

BMJ Best Practice

Encephalitis

Straight to the point of care



Last updated: Mar 04, 2025

Table of Contents

Overview	3
Summary	3
Definition	3
Theory	4
Epidemiology	4
Etiology	4
Pathophysiology	6
Case history	7
Diagnosis	8
Approach	8
History and exam	12
Risk factors	14
Tests	17
Differentials	45
Criteria	49
Management	51
Approach	51
Treatment algorithm overview	54
Treatment algorithm	57
Emerging	74
Primary prevention	74
Secondary prevention	75
Patient discussions	75
Follow up	76
Monitoring	76
Complications	77
Prognosis	79
Guidelines	80
Diagnostic guidelines	80
Treatment guidelines	81
Online resources	82
References	83
Images	99
Disclaimer	133

Summary

Encephalitis is a pathologic state of brain parenchymal inflammation leading to an altered state of consciousness or focal neurologic signs.

It is a serious, complex, and potentially fatal disorder with both infectious and noninfectious causes.

Patients present with acute to subacute onset of altered mental status; typical features include fever, headache, seizures, and focal neurologic signs.

Initial investigations should always include blood cultures, neuroimaging (preferably magnetic resonance imaging), and cerebrospinal fluid analysis (unless contraindicated).

Intravenous acyclovir should be administered as soon as possible in all cases of suspected viral encephalitis.

Complications include seizures, hydrocephalus, and both short- and long-term neurologic sequelae (e.g., behavioral disturbances, motor problems).

Definition

Encephalitis is defined as inflammation of the brain parenchyma associated with neurologic dysfunction, such as altered state of consciousness, seizures, personality changes, cranial nerve palsies, speech problems, and motor and sensory deficits.^[1] It is the result of direct inflammation of the brain tissue, as opposed to the inflammation of the meninges (meningitis), and can be the result of infectious or noninfectious causes. An etiologic agent is only identified in around 50% of cases.^{[2] [3]}

Epidemiology

Globally, the incidence of encephalitis is around 1.5 to 14 per 100,000 population per year.[4] [5]

Approximately 20,000 cases occur each year in the US.[6] True incidence is difficult to determine (due to the wide spectrum of clinical presentation, under-diagnosis, and under-reporting), and may be higher than hospital discharge data suggest in England, France, Italy, Canada, and Australia.[7] [8] [9] [10] [11] [12]

Infectious causes are most frequently identified causes of encephalitis. For infectious etiologies, there is no specific predominance in either sex, but frequently a bimodal age distribution is seen with peaks in the young and the elderly.[13]

Seasonal and geographic variations occur in some cases of viral encephalitis in the US and other parts of the world. There is increased incidence in summer and early fall (peaking July to October) for enteroviruses and most arboviruses, reflecting seasonal variations in pathogen and/or vector activity. Certain arboviruses show marked geographic variation. In Europe, tick-borne encephalitis (TBE) is increasing due to broadening of endemic areas and prolongation of the tick activity season.[14] TBE virus is endemic in rural and forested areas of central, eastern, and northern Europe.[15] In 2021, there were 3027 cases of TBE across 25 EU/EEA countries. The highest number of confirmed cases were seen in Czechia, Sweden, and Germany.[16]

Incidence of encephalitis associated with HIV infections has decreased and stabilized since the late 1990s with the advent of antiretroviral therapies.[6] In contrast, encephalitis associated with immunocompromised states induced in the setting of transplant or immune-mediated diseases has steadily increased.

Unlike infectious etiologies, there tends to be a female predominance in autoimmune encephalitis, with anti-N-methyl-D-aspartate receptor (anti-NMDAR) encephalitis being the most commonly reported type of autoimmune encephalitis. Acute disseminated encephalomyelitis (ADEM) is a rare illness with an incidence of 0.2 to 0.4 per 100,000 children annually.[17] [18] [19] The most common age of presentation is between 3 and 7 years.[18] [20]

Etiology

An etiologic agent is only identified in around 50% of cases.[6] [7] [21] [22] [23] [24] [25]

Viruses are the main identified cause of encephalitis, with herpes simplex virus (HSV) being the most commonly identified globally.[26] Japanese encephalitis (JE) is an important viral cause in Asia, particularly in rural and suburban areas where pigs are thought to act as amplifier hosts.[27] The global incidence of JE is unknown.[28] In the US, West Nile virus is a consideration for patients with encephalitis; it is a leading cause of domestically acquired arboviral disease with over 60% of West Nile virus cases in the US reported as encephalitis in 2021.[29] Other arboviruses (ARthropod-BORne viruses) with ticks and mosquitoes as vectors are a main contributor to encephalitic etiologies worldwide. [CDC: Division of vector-borne diseases (DVBD)] (<http://www.cdc.gov/nceid/dvbd/about.html>)

The incidence of encephalitis in patients with HIV has improved since the advent of highly active antiretroviral therapy, mainly manifested by a decrease in incidence of toxoplasma encephalitis. *Neisseria meningitidis* is the main bacterial cause of meningoencephalitis and disproportionately affects the young (<1 year old) and old (>65 years old).[7]

Immune-mediated or autoimmune encephalitis remains relatively rare, despite accounting for approximately one third of cases with identified etiology. Incidence is increasing, likely due to the widening availability of diagnostic testing, growing number of identified antibodies and more awareness among clinical

practitioners.[6] [30] It can be associated with a preceding infection or a presence of an underlying malignancy. In adults, anti-NMDAR antibodies are the most common cause of autoimmune encephalitis, and typically associated with the presence of ovarian teratoma.[31] Acute disseminated encephalomyelitis (ADEM) is thought to be a post-infectious response, and is a common cause of autoimmune encephalitis in children.

The following is a list of the main etiologic agents in encephalitis.

Viral infections:

- Herpes viruses: herpes simplex virus (HSV)-1, HSV-2, varicella zoster virus (VZV), cytomegalovirus (CMV), Epstein-Barr virus (EBV), human herpesvirus-6, herpes B virus
- Picornaviridae/enteroviruses: enterovirus-71, coxsackievirus, poliovirus
- Parechovirus
- Flaviviruses: West Nile virus, Japanese encephalitis virus, tick-borne encephalitis virus, Murray Valley encephalitis virus, Saint Louis encephalitis virus, Powassan virus, dengue virus
- Bunyavirus: La Crosse virus, Jamestown Canyon virus, Toscana virus
- Togavirus: chikungunya virus, Venezuelan equine encephalitis virus, Western equine encephalitis virus, Eastern equine encephalitis virus
- Paramyxovirus: Nipah virus, Hendra virus
- Others: coronaviruses, snowshoe hare virus, lymphocytic choriomeningitis virus, mumps virus, HIV, rabies virus, measles virus, adenovirus, influenza virus, parainfluenza virus, hepatitis C virus, rotavirus, parvovirus B19, BK virus, JC virus, cycloviruses, and Zika.

Bacterial infections:

- *Neisseria meningitidis*
- Tuberculosis
- *Treponema pallidum* (syphilis)
- *Listeria*
- *Bartonella* (cat-scratch disease)
- *Borrelia burgdorferi* (Lyme disease)
- Rickettsia and ehrlichiosis (Rocky Mountain spotted fever, Ehrlichia, *Coxiella burnetii*)
- Mycoplasma
- Typhoid fever
- Brucellosis
- Leptospirosis
- *Tropheryma whipplei* (Whipple disease)
- *Actinomyces*
- *Streptococcus agalactiae*
- *Klebsiella*
- *Streptococcus pneumoniae*
- *Staphylococcus aureus*
- *Streptococcus viridans*
- Group C beta-hemolytic streptococci
- *Nocardia* .

Fungal infections:

- *Cryptococcus*
- *Coccidioides*

- *Histoplasma*
- *Blastomycosis*
- *Candida*.

Parasitic infections:

- *Toxoplasma gondii*
- Cysticercosis
- *Naegleria fowleri*
- *Entamoeba histolytica*
- *Plasmodium falciparum*
- *Balamuthia mandrillaris*
- *Baylisascaris procyonis*
- *Echinococcus granulosus*
- Human African trypanosomiasis
- Schistosomiasis
- *Angiostrongylus cantonensis* .

Parainfectious:

- ADEM
- Acute hemorrhagic leukoencephalitis
- Bickerstaff encephalitis
- Rasmussen encephalitis.

Prion diseases:

- Creutzfeldt-Jakob disease.

Paraneoplastic syndromes:

- "Classical" antibodies against intracellular onconeural antigens (e.g., anti-Hu, anti-Yo)
- Surface antibodies targeting neuronal surface or synaptic antigens (e.g., N-methyl-D-aspartate receptor-antibody and leucine-rich glioma inactivated-antibody).

Pathophysiology

Encephalitis is an inflammatory process in the brain parenchyma. It is associated with clinical evidence of brain dysfunction due to infectious (usually viral) or noninfectious (usually autoimmune) processes. The pattern of brain involvement depends on the specific pathogen, the immunologic state of the host, and a range of environmental factors. In viral encephalitis, the virus initially gains entry and replicates in local or regional tissue, such as the gastrointestinal tract, skin, urogenital system, or respiratory system. Subsequent dissemination to the central nervous system occurs by hematogenous routes (including enterovirus, arboviruses, herpes simplex virus, HIV, mumps) or via retrograde axonal transport, as with the herpes virus, the rabies virus, or variant scrapie-isoform prion proteins.

Depending on the interactions between the neurotropic properties of the virus and the host immune response (mediated by humoral antibodies, cytotoxic T cells, cytokines, innate immunity of each neuronal subtype), infection and inflammation of brain parenchyma occur.^[32] In these cases, neuronal involvement occurs along with evidence of a productive viral infection. In contrast, autoimmune etiologies are thought to result from antibodies or T-cells directed against normal brain antigens, which play a role in anti-N-methyl-D-aspartate (NMDA) receptor encephalitis and other paraneoplastic syndromes. Given the immune-mediated

pathophysiology of autoimmune encephalitis, these conditions are typically amenable to immunosuppressive therapy.

Case history

Case history #1

A 56-year-old man presents to the emergency department with headache, fever, blurred vision, and somnolence followed shortly by unresponsiveness to verbal commands. For the last 2 weeks he had been feeling ill, and had decreased appetite and myalgias. Three days prior to presentation he experienced intermittent confusion, severe headache, and fever. Examination was limited by a generalized tonic-clonic seizure, for which he received lorazepam.

Case history #2

A 19-year-old man presents to the emergency department with a witnessed generalized tonic-clonic seizure episode. One month previously he had an upper respiratory tract infection. Over the last 2 weeks he developed headaches, blurred vision, generalized weakness, and progressive difficulty walking. Examination revealed pain on eye movement as well as limb and gait ataxia.

Approach

Encephalitis is a medical emergency.[33] An acute or subacute onset of a febrile illness, altered mental status, focal neurologic abnormalities, and seizures raises suspicion for this condition.[13] [47] The main differential to distinguish is encephalopathy secondary to metabolic or toxic disturbances, which is more associated with systemic, generalized symptoms (such as myoclonus or asterixis) and typically lacks focal findings seen with encephalitis. Once a primary central nervous system disease is suspected, the diagnostic approach is geared toward determining the etiology and appropriate therapy (i.e., finding the appropriate antiviral or antibacterial agents vs. immunotherapy).

Clinical evaluation

History may provide differentiation factors. Age (extremes of age), chronicity of disease, and immune status (HIV, organ transplantation, immunosuppressive medication) are important aspects to review. The time of year (summer), geographic location, travel history, and other exposure history (including occupational, vector, animal, ill contacts, water, sexual) are additional considerations.[26] Other factors to consider are a recent viral illness or vaccination, or a history of autoimmune disorders or malignancies.

General examination features such as skin rashes and/or bites, parotitis, or upper respiratory tract involvement may suggest a specific etiologic agent. Altered mental state, ranging from subtle alterations in level of arousal and behavioral abnormalities to coma, is typical. Lethargy, drowsiness, confusion, disorientation may be seen.[13] Focal neurologic findings are common and include hemiparesis, ataxia, pyramidal signs (brisk tendon reflexes, extensor plantar responses), cranial nerve deficits, involuntary movements (myoclonus and tremors) may occur.

Cognitive behavioral issues frequently occur, and these include: altered personality, withdrawal, akinetic mutism, bizarre behavior, memory problems, and an amnesic state. Seizures of all varieties occur; complex partial seizures are most commonly seen. Signs of meningoencephalitis (e.g., headache, photophobia, neck stiffness) are present in patients with meningeal inflammation. Symptoms and signs of a systemic illness, such as fever or upper respiratory or gastrointestinal symptoms, may precede or occur concurrently with the other presenting features. Other less common signs and symptoms include autonomic and hypothalamic disturbances, pericarditis/myocarditis, arthritis, retinitis, and acute flaccid paralysis, depending on the causative pathogen.[13]

Autoimmune encephalitis associated with surface antibodies targeting neuronal surface or synaptic antigens presents with a broad range of features, but well-recognized clinical syndromes do occur. Limbic encephalitis associated with leucine-rich glioma-inactivated 1 (LGI1) antibodies usually affects older patients, and is associated with faciobrachial dystonic seizures (e.g., rapid jerks of the face and/or ipsilateral arm and shoulder) before the development of frank seizures, behavioral changes, and cognitive impairment.[48] [49] Limbic encephalitis associated with contactin-associated protein-like 2 (CASPR2) antibodies is associated with peripheral nervous system involvement, including neuromyotonia and neuropathic pain syndromes. Anti-N-methyl-D-aspartate receptor (Anti-NMDA-R) encephalitis is marked by rapid onset (less than three months) and primarily affects young patients, with a female predominance.[31] Its features include early abnormal behavior and cognition, memory deficit, speech disorder, seizures, abnormal movements (e.g., orofacial, limb, or trunk dyskinesias), reduced consciousness level, and autonomic dysfunction or central hypoventilation.[50] Psychiatric symptoms including agitation, hallucinations, delusions, and catatonia may lead to hospital admission for psychosis are common presenting symptoms.[51]

Investigations required for all patients

A lumbar puncture is recommended for patients with suspected encephalitis, as long as there is no contraindication.[13] Contraindications to lumbar puncture include mass effect causing potential herniation, coagulopathy, concern for lumbar spine abscess, or open skin lesion at the site of entry. Usually three or four tubes of cerebrospinal fluid (CSF) are collected by lumbar puncture for diagnostic studies. The first tube has the highest potential for contamination with skin flora and should not be sent to the microbiology laboratory for direct smears, culture, or molecular studies.[26] A minimum of 0.5 to 1.0 mL of CSF should be sent immediately after collection to the microbiology laboratory in a sterile container for bacterial testing.[26] Larger volumes (5-10 mL) increase the sensitivity of culture and are required for optimal identification of mycobacteria, fungi, or malignancy.[26] CSF should not be refrigerated.[26]

Routine investigations in all patients should include:[26] [33]

- Cerebrospinal fluid (CSF):
 - Opening pressure
 - Cell count
 - Protein
 - Glucose
 - Gram stain
 - Bacterial culture
 - Herpes simplex virus-1/2 polymerase chain reaction (PCR)
 - Enterovirus PCR
 - Measles, mumps (if unvaccinated)
 - Erythrovirus B19
 - Influenza (depending on the season)
 - Hold residual sample for further testing.
- Serum:
 - CBC
 - Serum electrolytes/liver function test
 - Blood cultures (two sets)
 - Hold for further testing
- Imaging:
 - Chest x-ray
 - Neuroimaging (MRI with contrast is the study of choice; however, CT may be more readily available and produce better quality imaging in an uncooperative patient)
- Electroencephalogram may be indicated to investigate seizures, status epilepticus, and altered behavior or consciousness.[13] [47]

Further investigations required for specific groups

Adults

- CSF
 - Varicella zoster virus (VZV) PCR, VZV IgG/IgM
 - Cryptococcal antigen and/or India ink staining

- Oligoclonal bands and IgG Index
- Venereal Disease Research Laboratory (VDRL), fluorescent treponemal antibody absorption (FTA-ABS) test
- West Nile virus testing (West Nile IgM)
- Serum
 - HIV serology (consider RNA)
 - Nontreponemal testing (VDRL, rapid plasma reagin, ICE Syphilis recombinant antigen test), with treponemal testing for positive/equivocal results (FTA-ABS, enzyme immunoassay, or microhemagglutination assay)

Throat

- Antigen detection tests and PCR are performed on throat swabs to detect enterovirus, poliovirus, cytomegalovirus, adenovirus, mumps, measles, influenza, and parainfluenza[13]

Children

- CSF
 - Rotavirus (if unvaccinated)

Serum

- Epstein-Barr virus (EBV) serology (viral-capsid antigen IgG and IgM and EBV nuclear antigen IgG)
- *Mycoplasma pneumoniae* IgM and IgG
- Nasopharyngeal/respiratory tract aspirate
 - Influenza/adenovirus PCR

Immunosuppressed patients

- CSF
 - Cytomegalovirus PCR
 - Epstein-Barr virus PCR
 - Human herpesvirus-6/7 PCR
 - HIV PCR
 - JC virus PCR
- *Toxoplasma gondii* serology and/or PCR
- *Mycobacterium tuberculosis* testing (TB PCR and AFB culture)
- Fungal testing
-

Other tests to consider

- CSF viral-specific IgG/IgM antibodies and serum PCR (if a viral etiology is suspected).[26]
- Serum 16S ribosomal RNA gene (rRNA) sequencing for bacteria, acid-fast bacilli, fungus.
- Serum for LGI1 or CASPR2 antibodies and NMDA receptor antibodies. Voltage-gated potassium channel positivity, in the absence of LGI1 or CASPR2 antibodies, may not be a true marker of disease.[1] [52]
- CSF and serum paraneoplastic antibody testing if there is a clinical suspicion.[53] Up to 14% of patients with anti-NMDA-R encephalitis have antibodies in the CSF, but not serum. The clinical course seems to correlate better with CSF antibodies than serum antibodies.[54]

- CSF analysis for NMDA receptor antibodies may be useful in patients with relapsing symptoms after herpes simplex encephalitis (HSE), if clinical suspicion for autoimmune encephalitis supports this. In 20% of patients with HSE, antibodies may be triggered against the NMDA receptor.[55] [56] [57] These patients may respond to immunotherapy.[58]
- Stool culture (obtained more frequently in children when gastrointestinal symptoms precede encephalitis, or when enterovirus is suspected).
- Sputum culture (for *Mycoplasma*, tuberculosis [acid-fast stain], and fungal infections).
- Sputum PCR (in children, for *Mycoplasma pneumoniae* and enterovirus).
- Arbovirus testing: if an arbovirus infection is suspected, specific guidance on testing, such as from the Centers for Disease Control and Prevention, should be sought. [CDC: Division of vector-borne diseases (DVB)] (<http://www.cdc.gov/nceid/dvbd/about.html>)
- CSF real-time quaking-induced conversion assay (RT-QuIC) if prion disease is suspected. See Prion disease .
- Brain biopsy: although it is the most specific diagnostic test, brain biopsy is not performed routinely due to its invasive nature, lack of widespread availability, and because DNA amplification techniques are now widely available to identify virologic causes. Where diagnosis is uncertain and prognosis remains poor, brain biopsy may be essential. Important for diagnosis and treatment, the brain biopsy may also provide an etiologic clue.[59] UK guidelines recommend to consider stereotactic biopsy in patients with suspected encephalitis in whom no diagnosis has been made after the first week, especially if there are focal abnormalities on imaging and no clinical improvement.[13]
- Whole-body CT and whole-body PET scans (performed if an underlying cancer is suspected).
- Abdominal/pelvic ultrasound may be useful if anti-NMDA-R encephalitis is suspected; up to 58% of affected young female patients have an ovarian teratoma.[51]
- If malignancy screening is negative, repeating the assessment 3 to 6 months later should be considered in cases where the autoantibody found is strongly associated with malignancy.[1] [51]

Additional tests (typically restricted to academic centers)

Magnetic resonance spectroscopy

- Advanced imaging techniques provide metabolic data that can be used to clarify abnormal brain areas and identify the etiology. They are obtained in patients with a clinical diagnosis of encephalitis but in whom etiology is unknown, or if diagnosis of encephalitis is suspected but cannot be differentiated from brain tumors (e.g., by first-line tests).

Next-generation sequencing of CSF

- As opposed to directed PCR amplification of a selected number of targets, technology is now available to detect organisms in an unbiased manner. Genetic material is isolated from organisms, and select DNA and RNA sequences can be amplified with universal primers. The sequence is then compared with publicly available sequences to identify the organism. Furthermore, unbiased next-generation sequencing will provide a powerful tool to potentially identify new and/or potentially treatable infectious agents.

History and exam

Key diagnostic factors

fever (common)

- Frequently seen in infectious causes of encephalitis.[13] Important exceptions are immunocompromised patients (who may not be able to mount a fever response) as well as individuals with measles causing subacute sclerosing panencephalitis, varicella zoster virus infection, and hepatitis C.

rash (common)

- Vesicular eruption - enterovirus, herpes simplex virus (HSV), varicella zoster virus.
- Maculopapular eruption - Epstein-Barr virus (after treatment with ampicillin), measles, human herpesvirus-6, Colorado tick fever, West Nile virus.
- Malar rash - systemic lupus erythematosus.
- Petechial rash - rickettsial fever.
- Erythema migrans - Lyme disease.
- Erythema nodosum - tuberculosis and histoplasmosis, sarcoidosis.
- Erythema multiforme - HSV, *Mycoplasma*.
- Mucous membrane lesions - herpes virus, Behcet.
- Pharyngitis - enterovirus, adenovirus.
- Conjunctivitis - St. Louis encephalitis virus, adenovirus, leptospirosis (conjunctival suffusion).
- Gumma - syphilis.
- Kaposi sarcoma - HIV/AIDS.
- Nonhealing skin lesions - *Balamuthia mandrillaris*, *Acanthamoeba*.
- Genital lesions - HSV-2, Behcet.
- Lesions on the hands, feet and mouth - enteroviral infections (e.g., enterovirus 71).

altered mental state (common)

- A frequent component.[13] Alterations in higher mental function include lethargy, drowsiness, confusion, disorientation.[13]
- Cognitive dysfunction with acute memory disturbances and psychiatric and behavioral manifestations (e.g., withdrawal, apathy, abulia, akinetic mutism, personality changes, psychotic behavior, disorientation, and hallucinations) can be seen.

focal neurologic deficit (common)

- Include aphasia, hemianopia, hemiparesis, ataxia, brisk tendon reflexes, Babinski sign, cranial nerve deficits (seen in human herpesvirus-6, tuberculosis, syphilis, brucellosis, acute disseminated encephalomyelitis, West Nile virus, St. Louis encephalitis virus, varicella zoster virus, herpes B virus, rabies); tremors (arboviruses); myoclonus (subacute sclerosing panencephalitis); paresthesias (Colorado tick fever, rabies); generalized weakness (West Nile virus, rabies).

meningismus (common)

- Some patients have evidence of meningeal inflammation with headache, photophobia, and neck stiffness.

parotitis (uncommon)

- Seen in mumps.

lymphadenopathy (uncommon)

- Seen in *Bartonella*.

optic neuritis (uncommon)

- Seen in acute disseminated encephalomyelitis.

acute flaccid paralysis (uncommon)

- West Nile virus and other arboviruses, rabies.[13]

movement disorder (uncommon)

- Creutzfeldt-Jakob disease (myoclonus), anti-N-methyl-D-aspartate receptor encephalitis (orofacial dyskinesias/myorhythmia), rabies, Whipple disease (oculomasticatory myorhythmia).

Other diagnostic factors**cough (common)**

- Upper and lower respiratory tract symptoms and signs (e.g., cough) can occur in herpes simplex virus-1, influenza, parainfluenza, *Mycoplasma pneumoniae*, Q fever, *Coccidioides*, *Histoplasma*, blastomycosis, or rabies.

gastrointestinal infection (common)

- Enteroviruses, rotavirus, Whipple disease.

seizures (common)

- Generalized tonic-clonic seizures and focal seizures (with or without secondary generalization) are very frequently seen at some point in the clinical course. Most frequently seen in patients with measles causing subacute sclerosing panencephalitis, human herpesvirus-6 infection, and herpes simplex virus-1 infection. Status epilepticus that is particularly resistant to treatment is sometimes seen.[47]
Faciobrachial dystonic seizures (e.g., rapid jerks of the face and/or ipsilateral arm and shoulder) are seen in limbic encephalitis associated with leucine-rich glioma-inactivated 1 antibodies.[48]

biphasic illness (uncommon)

- Enterovirus, Colorado tick fever.

autonomic and hypothalamic disturbances (uncommon)

- Loss of temperature and vasomotor control (dysautonomia), diabetes insipidus, and syndrome of inappropriate secretion of antidiuretic hormone are sometimes part of the clinical picture in encephalitis and can contribute to morbidity and mortality.
- Seen in anti-N-methyl-D-aspartate receptor encephalitis and anti-voltage gated potassium channel encephalitis.

myocarditis/pericarditis (uncommon)

- Enterovirus, mumps, Chagas disease.

jaundice (uncommon)

- May be seen in leptospirosis.

arthritis (uncommon)

- Seen in Lyme disease, systemic lupus erythematosus.

retinitis (uncommon)

- Cytomegalovirus, toxoplasmosis, West Nile virus, paraneoplastic syndrome.

parkinsonism (uncommon)

- Arbovirus, toxoplasmosis.

Risk factors

Strong**age <1 or >65 years**

- Increased risk of developing more extensive and prominent symptoms and signs of infective (viral) encephalitis.
- Neonates are especially susceptible to infectious encephalitis.
- Older individuals are at higher risk due to both weaker immune system as well as higher likelihood of malignancy

immunodeficiency

- Etiologic agent and clinical severity varies with host immune status.
- Immunocompromised patients (e.g., patients with HIV infection and those receiving chemotherapy or immunosuppressive medications) tend to have more extensive and florid manifestations. They are susceptible to pathogens that usually do not cause encephalitis in immunocompetent hosts (e.g., cytomegalovirus, Epstein-Barr virus, human herpesvirus-6, toxoplasmosis, JC virus, *Candida*, and *Nocardia*). Agammaglobulinemic patients are particularly susceptible to enteroviral meningoencephalitis.[6]

vector exposure and/or animal bites

- Mosquitoes can transmit West Nile virus, St. Louis encephalitis virus, Eastern equine, Western equine, Venezuelan equine, Japanese B, Murray Valley, Ilheus, and Rocio viruses.
- Tick bites are associated with tick-borne encephalitis, Colorado tick fever, Powassan virus, Far Eastern, Central European, Kyasanur Forest disease virus, Louping Ill, Negishi, Russian spring-summer, Lyme disease, Rocky Mountain spotted fever, and *Ehrlichia*.
- Animal bite/exposure is associated with rabies (bats), brucellosis, *Bartonella* (cats), *Toxoplasma*, Q fever, and herpes B (primates). It is important to note that lack of a known bite or other exposure history does not exclude the diagnosis of rabies.

location

- Etiologic agents are endemic to certain locales.[33] Consider immigration and recent travel history.
- Africa: malaria, trypanosomiasis, dengue, Ebola virus.
- Asia: Japanese encephalitis virus, dengue, malaria, Nipah virus.

- Australia: Murray Valley encephalitis, Kunjin virus, Australian bat lyssavirus.[34]
- Europe: tick-borne encephalitis virus, West Nile virus, Toscana virus.
- Central and South America: dengue, malaria, West Nile virus, Venezuelan equine encephalitis.
- North America: West Nile virus and St. Louis encephalitis virus are common throughout the US. *Coccidioides* and blastomycosis are common in the southwestern and midwestern US, respectively. Lyme disease in northcentral and northeastern US.

postinfection

- Bickerstaff encephalitis, Rasmussen encephalitis, anti-N-methyl-D-aspartate receptor encephalitis, and acute disseminated encephalomyelitis can be seen after the resolution of a viral illness (e.g., varicella, herpes virus, nonspecific upper respiratory viral infections, mumps, rubella, enterovirus, Epstein-Barr virus, influenza viruses, adenovirus) and may be due to an autoimmune process.

blood/body fluid exposure

- HIV and West Nile virus can be transmitted by contaminated blood products, needle sticks, and body fluid exposure.

organ transplantation

- Rabies, West Nile virus, and cytomegalovirus infections have occurred in transplant patients who received organs from infected donors.[38]

season

- Spring: Powassan virus, Colorado tick fever.
- Summer: enterovirus, arboviruses, Colorado tick fever, Lyme disease (but may occur year-round).
- Fall: enterovirus, arboviruses, lymphocytic choriomeningitis virus (LCMV).
- Winter: LCMV, influenza.
- July-November: West Nile virus.
- Rainy season: Venezuelan equine (May through December).

swimming or diving in warm freshwater or nasal/sinus irrigation

- Associated with *Naegleria*.

Weak

vaccination

- Although most studies find no relation between vaccination and acute disseminated encephalomyelitis (ADEM), certain vaccines, including older vaccines containing neural tissues and those against COVID-19, may be associated with a rare risk of developing ADEM.[18] [35] [36]
- Children not vaccinated against mumps and measles are at risk of developing measles or mumps encephalitis.
- Rarely, unvaccinated children suffering with measles infection can develop subacute sclerosing panencephalitis, a progressive neurologic deterioration typically leading to death within 4 years.[37]

occupation

- Forestry worker: Lyme disease, Kyasanur Forest disease virus, rabies.
- Farm workers: Nipah, avian influenza, brucellosis.
- Abattoir workers: Q fever.
- Laboratory workers: Ebola, Marburg, herpes B.

- Healthcare workers and prison staff: Tuberculosis.

hunting/trekking in woods

- Associated with Lyme disease (tick exposure) and rabies (through exposure to a rabid animal).

spelunking (cave-exploring)

- Associated with rabies (through exposure to bats).

death in animals

- Epidemic outbreaks of certain viral encephalitides in humans are frequently preceded by large-scale illnesses and death in animals (horses for equine encephalitides) and birds (West Nile virus).

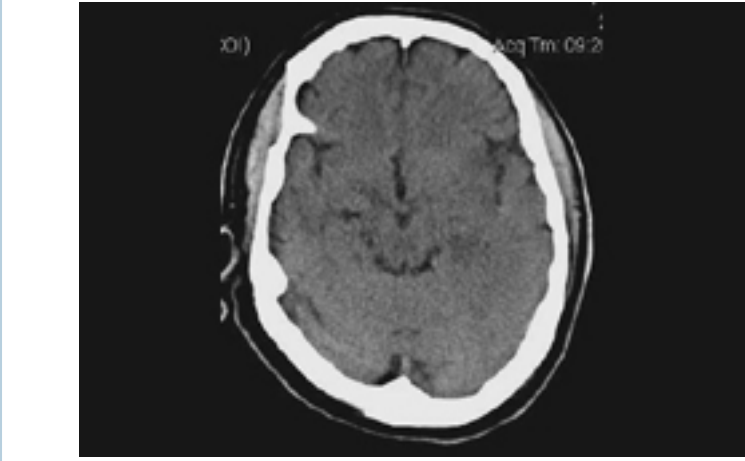
cancer

- Paraneoplastic encephalitis may be related to classical antibodies against intracellular onconeural antigens (e.g., anti-Hu, anti-Yo), or antibodies targeting neuronal surface or synaptic antigens (e.g., N-methyl-D-aspartate receptor-antibody and leucine-rich glioma inactivated-antibody).^[39] Typically associated with cancer in the lung, breast, or reproductive organ.

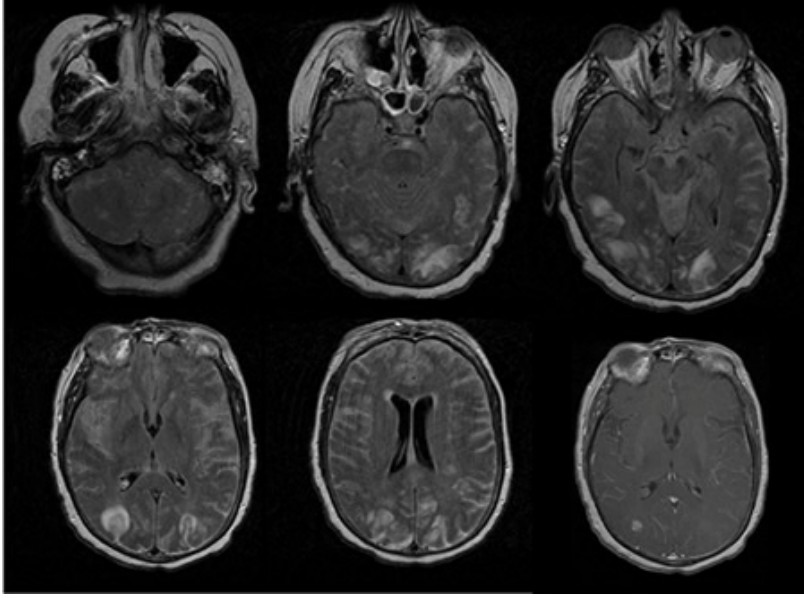
Tests

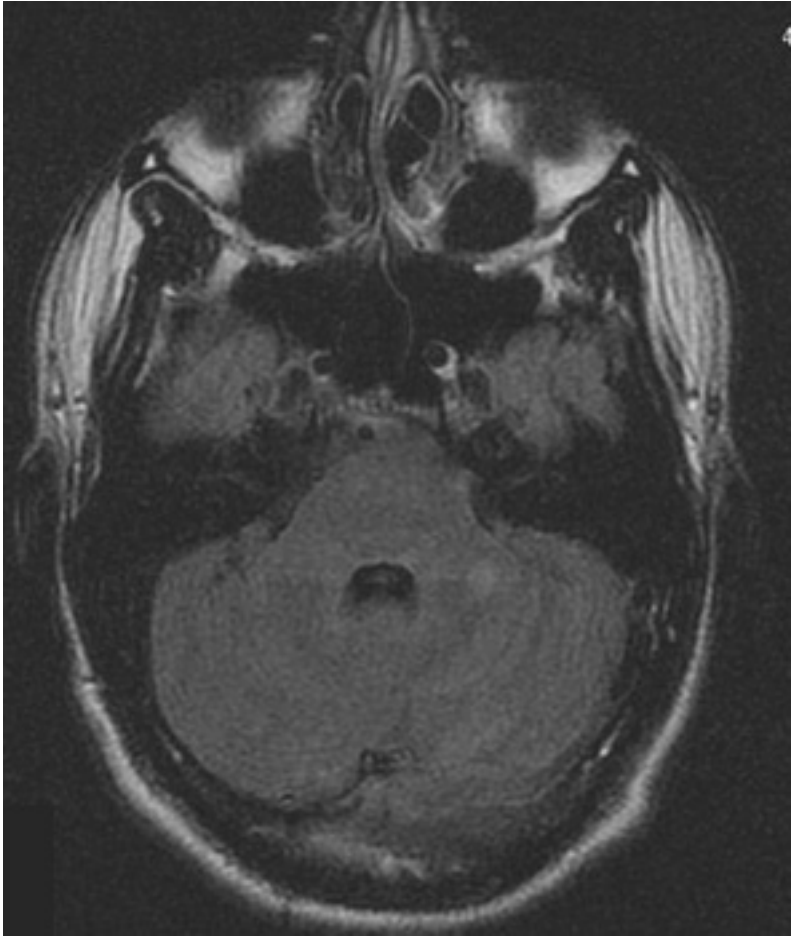
1st test to order

Test	Result
CBC <ul style="list-style-type: none"> A routine test. An elevated WBC count occurs in most infectious causes of encephalitis. Depressed WBC counts and pancytopenia can be seen in HIV and immunomodulating/immunosuppressive drug use. A relative lymphocytosis may occur in viral encephalitis. Rickettsial and viral fevers are associated with leukopenia and thrombocytopenia. Eosinophilia is seen in certain parasitic infections (<i>Baylisascaris procyonis</i>). 	often elevated WBC
peripheral blood smear <ul style="list-style-type: none"> It is preferable to collect blood for the smear at the time of a fever spike in cases of suspected malarial illness, to increase the likelihood of finding the trophozoites. This is essential in malarial-endemic areas. Cytoplasmic inclusions in monocytes are seen in ehrlichiosis. 	detection of <i>Plasmodium falciparum</i> and <i>Ehrlichia</i>
serum electrolytes <ul style="list-style-type: none"> A routine test. Hyponatremia is seen in rickettsial infections and syndrome of inappropriate secretion of antidiuretic hormone (particularly in TB), and anti-voltage-gated potassium channel-associated encephalitis (anti-leucine-rich glioma-inactivated 1/contactin-associated protein-like 2 encephalitis). 	hyponatremia
liver function tests <ul style="list-style-type: none"> <i>Coxiella burnetii</i> , <i>Rickettsia</i> , tick-borne disease, cytomegalovirus, Epstein-Barr virus. 	elevated
blood cultures <ul style="list-style-type: none"> Two sets of blood cultures should be obtained as part of the routine workup of a febrile illness. Arboviral cultures are rarely performed and are available only through specialized reference laboratories. 	detection and confirmation of systemic bacterial and fungal infections
throat swab <ul style="list-style-type: none"> Antigen detection tests and PCR are performed on throat swabs to detect enterovirus, poliovirus, cytomegalovirus, adenovirus, mumps, measles, influenza, and parainfluenza. 	detection of viruses
nasopharyngeal aspirate <ul style="list-style-type: none"> Obtained in children (less commonly used in adults) with respiratory symptoms. 	detection of respiratory viruses; polymerase chain reaction confirmation for adenovirus or influenza virus
chest radiography <ul style="list-style-type: none"> Routinely performed as part of a febrile workup. May detect <i>Mycoplasma</i> , <i>Legionella</i> , influenza, parainfluenza, tuberculosis, <i>Coccidioides</i> , <i>Histoplasma</i> , blastomycosis, <i>Coxiella burnetii</i> , or sarcoidosis. 	may detect a noninfectious or infectious cause (e.g., tuberculosis, sarcoidosis, malignancy)

Test	Result
<p>CT brain</p> <ul style="list-style-type: none"> • Used more as a screening tool due to its widespread availability and ease of acquisition in an uncooperative patient. CT brain is indicated in patients with GCS<12, focal neurologic deficits, continuous or uncontrolled seizures, and papilledema.[60] • Post-contrast CT scans (if obtained) can demonstrate diffuse meningeal enhancement, which is a frequent co-occurrence in encephalitis. Vessel imaging up to the vertex must be obtained in cases with systemic infection in order to assess for mycotic aneurysms. • Herpes simplex virus encephalitis: an initial CT scan soon after admission will show a suggestive abnormality in about 25% to 80% of patients with HSV encephalitis, though it is not, on its own, diagnostic.[61] Hypodense lesions and mild mass effect in temporal lobes, insula, hemorrhage, and enhancement may be seen. • HIV-1: normal/mild atrophy with hypodense white matter lesions. Opportunistic infections and complications of HIV infection have their own characteristic findings. • Acute disseminated encephalomyelitis (ADEM): normal in 40%; low-density, flocculent, asymmetric multifocal punctuate or ring-enhancing lesions can be seen. • West Nile virus: hyperintensities in the deep brain structures, including basal ganglia and thalamus. • Amoebae: diffuse edema.  <p><i>Noncontrast head CT of a patient with HSV encephalitis: shows subtle hypodensities involving the left insular region. Some blurring of gray-white margins and sulcal effacement over the left temporal region is discernible</i> <i>From the personal collection of Catalina C. Ionita, MD; used with permission</i></p>	<p>frequently normal early in the clinical course of encephalitis, but may see more prominent changes</p>
<p>MRI brain</p> <ul style="list-style-type: none"> • Highly recommended (preferably initially) in suspected encephalitis and is invaluable in diagnosis.[47] [62] [63] However, MRI is less widely available compared with CT, and may require sedation for 	<p>depends on etiology; often hyperintense lesions (T2 and fluid-attenuated inversion recovery [FLAIR] sequences), increased</p>

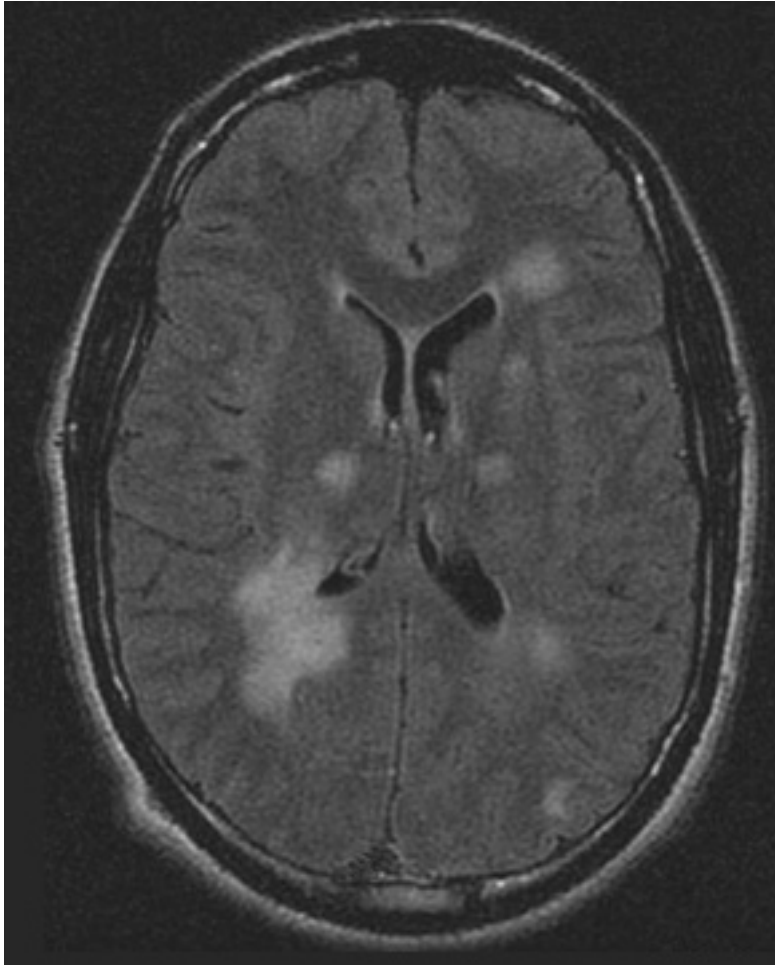
Test	Result
<p>optimal image quality. MRI should include FLAIR, diffusion, T2*, and T1 sequences with and without gadolinium if possible.[47]</p> <ul style="list-style-type: none"> • Early lesions in the form of signal abnormalities are seen in most cases. • Herpes simplex virus encephalitis: gyral edema on T1, high signal on T2, FLAIR, and DWI (with increased diffusion on Apparent Diffusion Coefficient [ADC] maps) in temporal lobe and cingulate gyrus. • HIV: atrophy and nonspecific white matter high signal on T2 and FLAIR. Opportunistic infections and complications of HIV infection have their own characteristic findings. • Polio and Coxsackie: T2 hyperintensities in the midbrain and anterior horn of the spinal cord. • Epstein-Barr virus: T2 hyperintensities in the basal ganglia, thalami, and cerebellum. • Varicella zoster virus: white and gray matter hyperintensities. • West Nile virus: Leptomeningeal periventricular enhancement. • Japanese encephalitis: T2 hyperintensities in bilateral thalami, brainstem, and cerebellum. • Acute disseminated encephalomyelitis (ADEM): multifocal, bilateral, asymmetric, hyperintense (ranging in size from <1 cm to multiple-centimeter confluent white matter abnormalities) lesions of the white and gray matter on T2 and FLAIR.[18] Typically, lesions occur in the deep and subcortical white matter while sparing periventricular white matter, unlike multiple sclerosis.[18] Gray matter lesions can occur in ADEM, particularly in the thalami and basal ganglia.[18] Ring-enhancing lesions may be seen on post-contrast T1 images. • Rasmussen encephalitis: T2 hyperintensities in cortex and white matter, cortical atrophy of the fronto-insular region, enlargement of lateral ventricle, and moderate atrophy of the caudate nucleus, all limited to one cerebral hemisphere. • Creutzfeldt-Jakob disease: T2/FLAIR hyperintensities and/or DWI changes in the globus pallidus, thalamus, and cortex (cortical ribboning). • Paraneoplastic limbic encephalitis: bilateral involvement of the medial temporal lobes and multifocal lesions on FLAIR and DWI. 	<p>diffusion on diffusion-weighted imaging (DWI) indicating edema, contrast enhancement on T1 post-contrast sequences indicating blood-brain barrier breakdown; MRI is normal in up to a third of patients with autoimmune encephalitis</p>

Test	Result
 <p><i>The first 5 images are FLAIR images of patient with varicella zoster virus meningoencephalitis showing white and gray matter hyperintensities. The last image is T1 image with contrast showing parenchymal and diffuse leptomeningeal enhancement</i> <i>From the personal collection of Eric E. Kraus; used with permission</i></p>	

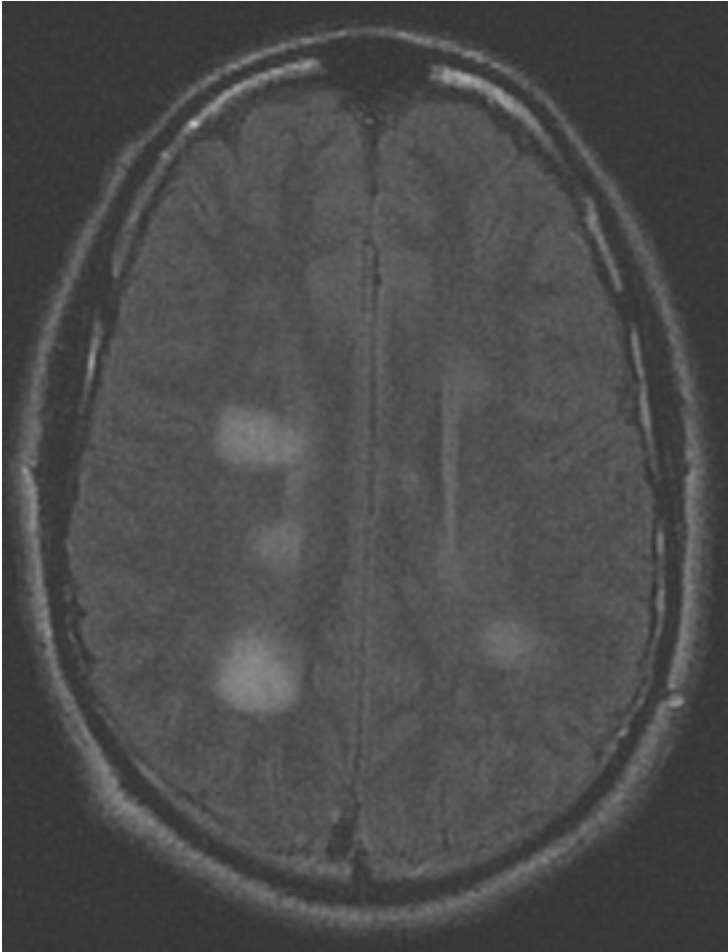
Test	Result
<div data-bbox="244 188 1038 1122"></div> <p data-bbox="300 1149 986 1292"><i>Series of MRI images of brain of patient with acute disseminated encephalomyelitis: hyperintense lesions of fluid attenuated inversion recovery (FLAIR) involving the left cerebellar peduncle</i> From the personal collection of Catalina C. Ionita, MD; used with permission</p>	

Test

Result

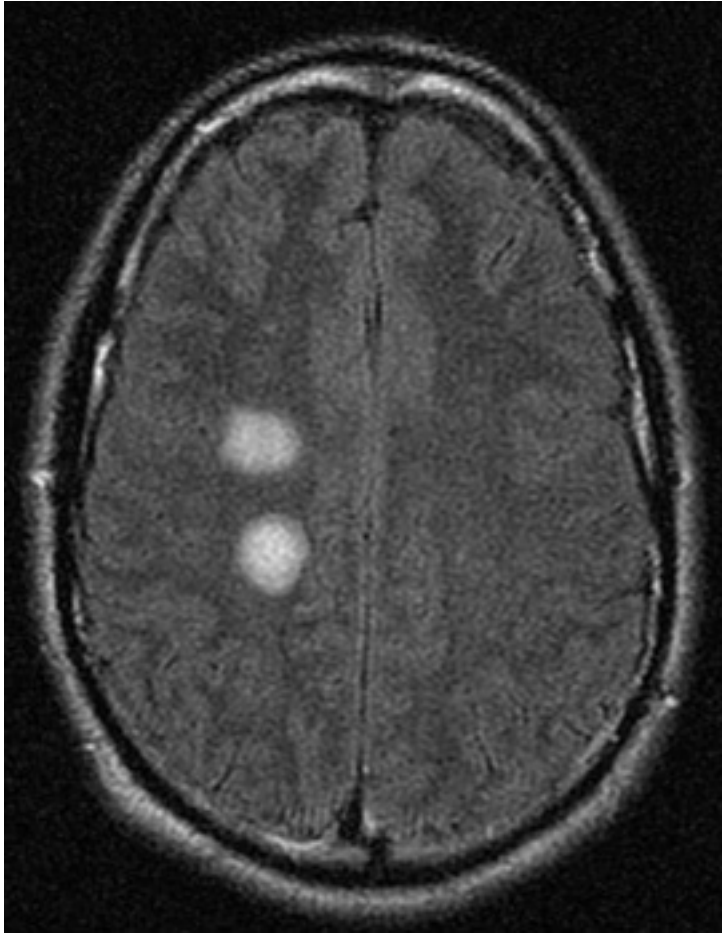


Series of MRI images of brain of patient with acute disseminated encephalomyelitis: asymmetric "fluffy" lesions over the bilateral ventricular horns and thalami
From the personal collection of Catalina C. Ionita, MD; used with permission

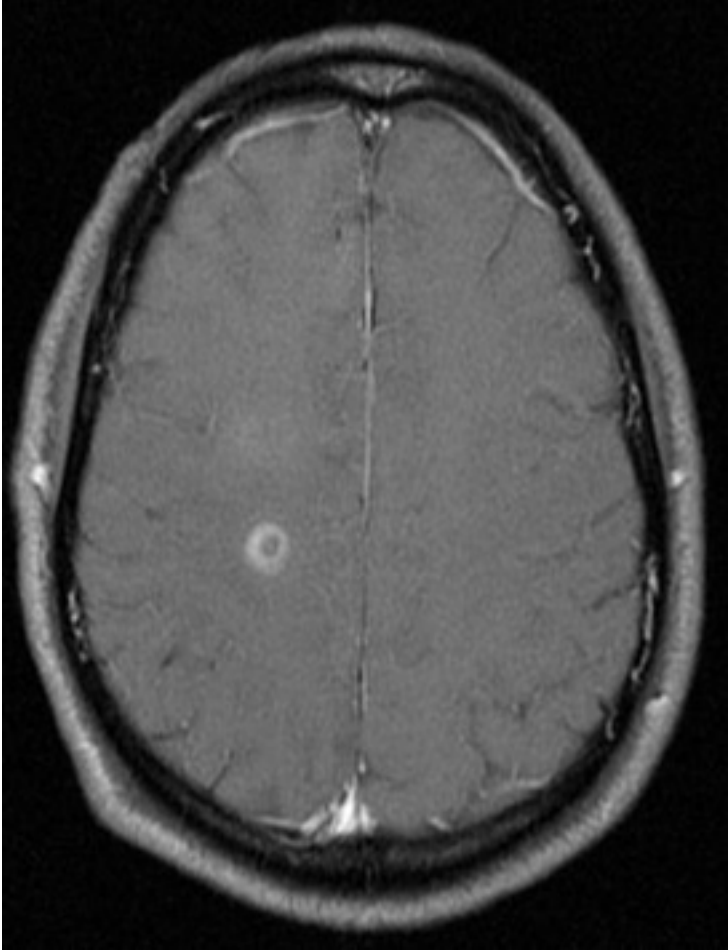
Test	Result
<div></div> <p><i>Series of MRI images of brain of patient with acute disseminated encephalomyelitis: periventricular regions</i> <i>From the personal collection of Catalina C. Ionita, MD; used with permission</i></p>	

Test

Result

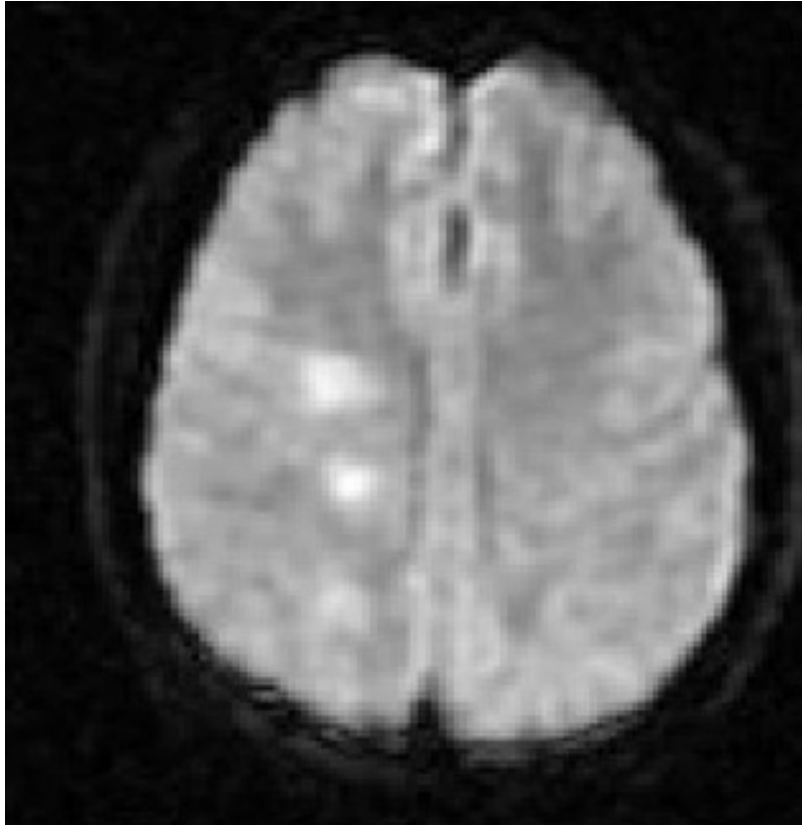


Series of MRI images of brain of patient with acute disseminated encephalomyelitis: centrum semiovale
From the personal collection of Catalina C. Ionita, MD; used with permission

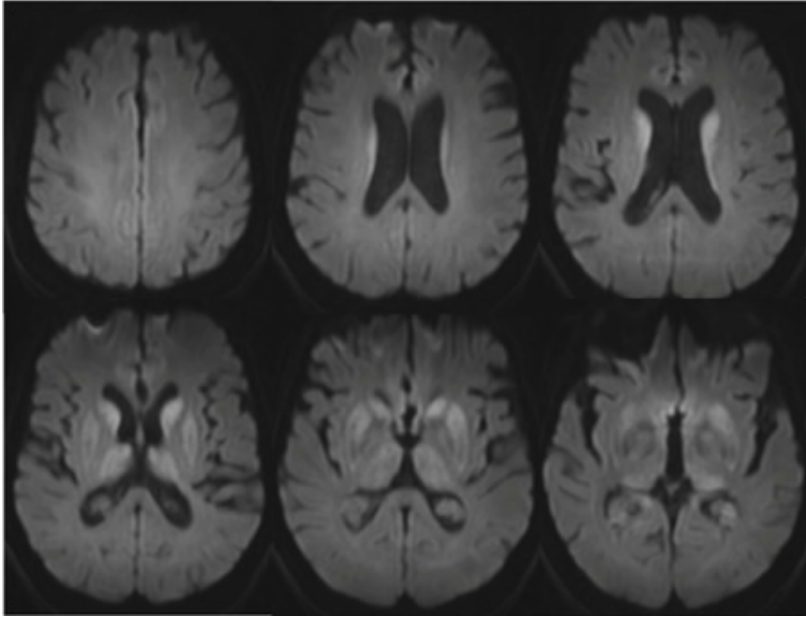
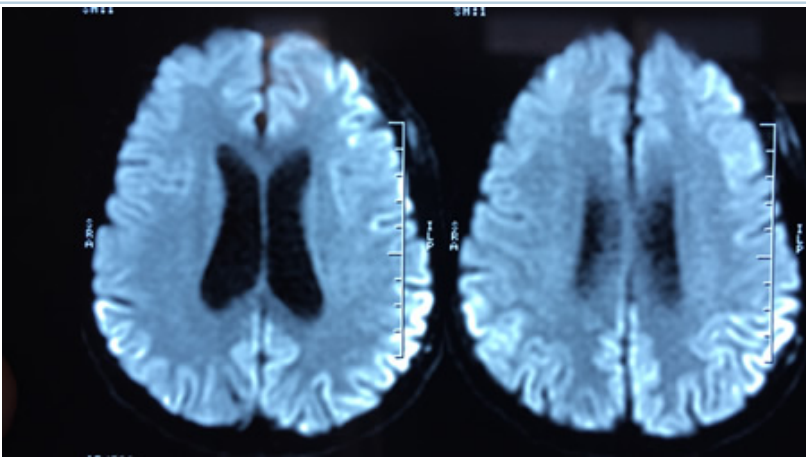
Test	Result
<div data-bbox="276 190 1007 1137"></div> <p data-bbox="295 1167 989 1339"><i>Series of MRI images of brain of patient with acute disseminated encephalomyelitis: T1 post-gadolinium enhanced image shows ring enhancement around a lesion in the right centrum semiovale region and faint diffuse enhancement just above this area</i> <i>From the personal collection of Catalina C. Ionita, MD; used with permission</i></p>	

Test

Result



Series of MRI images of brain of patient with acute disseminated encephalomyelitis: diffusion-weighted image from the same patient shows high signal intensity in the same area, and this correlates with increased (bright on ADC maps) diffusion
From the personal collection of Catalina C. Ionita, MD; used with permission

Test	Result
 <p><i>MRI brain: the pulvinar sign (a term referencing bilateral pulvinar hyperintensity) in a patient with Creutzfeldt-Jakob disease on diffusion-weighted images</i> <i>From the personal collection of Leo H. Wang; used with permission</i></p>  <p><i>MRI brain: cortical ribboning in a patient with Creutzfeldt-Jakob disease on diffusion-weighted images</i> <i>From the personal collection of Leo H. Wang; used with permission</i></p>	
<p>electroencephalogram (EEG)</p> <ul style="list-style-type: none"> • EEG may be indicated to investigate seizures, status epilepticus, and altered consciousness.[13] [47] Background slowing is an early 	<p>often shows background slowing</p>

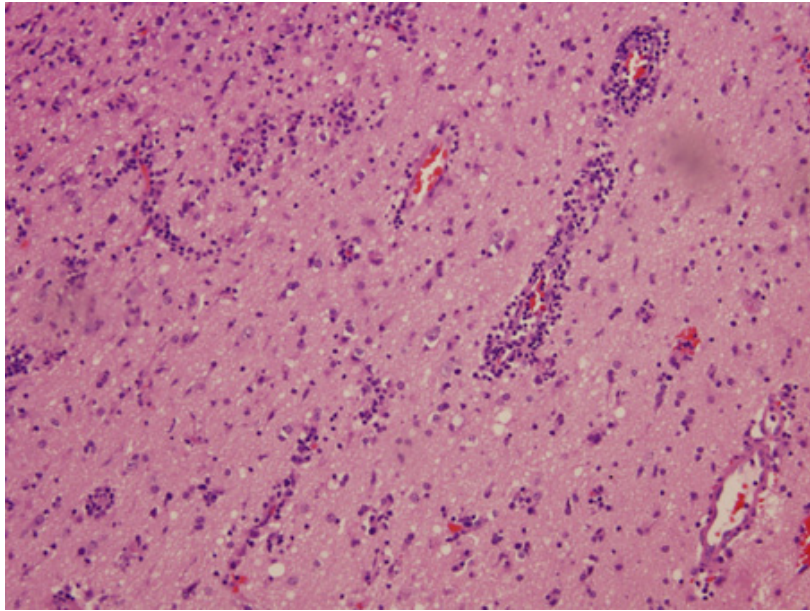
Test	Result
<p>and sensitive indicator of cerebral involvement but very nonspecific, especially if the patient has required sedation.</p> <ul style="list-style-type: none"> • Temporal lobe abnormalities are frequently seen in certain viral encephalitides, including HSV and VZV. • Repetitive sharp wave complexes over the temporal lobes or periodic lateralizing epileptiform discharges can be seen in herpes simplex virus encephalitis.[64] [65] • In subacute sclerosing panencephalitis, a typical generalized periodic EEG pattern repeating with intervals between 4 and 15 seconds, synchronous with the myoclonus of the patient, may be seen.[65] [66] • In autoimmune encephalitis, EEG can provide evidence of focality when MRI is normal.[67] Common findings include slowing and epileptiform changes, but these are not specific.[67] • Creutzfeldt-Jakob disease findings: high-amplitude periodic (1 Hz) complexes. Extreme delta brush may be seen in anti-N-methyl-D-aspartate receptor encephalitis. This is characterized by rhythmic delta activity at 1 Hz to 3 Hz, with superimposed bursts of rhythmic 20 Hz to 30 Hz beta frequency activity “riding” on each delta wave.[68] 	
<p>cerebrospinal fluid (CSF) analysis</p> <ul style="list-style-type: none"> • A lumbar puncture (LP) is recommended for patients with suspected encephalitis as long as there is no contraindication.[13] Contraindications to LP include mass effect causing potential herniation, coagulopathy, concern for lumbar spine abscess, or open skin lesion at the site of entry. Usually three or four tubes of cerebrospinal fluid (CSF) are collected by lumbar puncture for diagnostic studies. The first tube has the highest potential for contamination with skin flora and should not be sent to the microbiology laboratory for direct smears, culture, or molecular studies.[26] A minimum of 0.5 to 1.0 mL of CSF should be sent immediately after collection to the microbiology laboratory in a sterile container for bacterial testing.[26] Larger volumes (5-10 mL) increase the sensitivity of culture and are required for optimal identification of mycobacteria, fungi, or malignancy.[26] CSF should not be refrigerated.[26] • Opening pressure: usually elevated in bacterial, fungal, and TB meningoencephalitis, can be variable for other etiologies. • Color and clarity: variable, usually clear, can be mildly xanthochromic or blood-tinged in certain necrotizing and hemorrhagic encephalitides (herpes simplex virus [HSV], acute hemorrhagic leukoencephalitis, listerial and primary amebic meningoencephalitis). • Protein: normal or mildly elevated in most cases of viral encephalitis. Moderately elevated in bacterial infections, autoimmune diseases, limbic encephalitis, and acute disseminated encephalomyelitis. Markedly elevated in tuberculosis (TB) and sarcoidosis. • Glucose: normal to low normal in viral encephalitis except mumps, lymphocytic choriomeningitis virus, late stages of HSV-1. Low glucose levels are also seen in bacterial, fungal, parasitic, and neoplastic etiologies. • Cell counts: in the absence of a traumatic tap, RBC count is usually normal. In cases of HSV (40%), acute hemorrhagic leukoencephalitis, listerial and primary amebic meningoencephalitis, RBC >500/mm³ can be seen. WBC usually elevated in most cases and suggestive of an inflammatory process of the brain parenchyma, meninges, or both (meningoencephalitis). May be normal early in disease course and in immunocompromised patients who cannot mount an 	<p>findings depend on etiology; may have elevated WBC, normal/ elevated protein, normal/ low glucose, normal/ elevated red blood cell (RBC); up to a third of patients with autoimmune encephalitis have normal CSF</p>

Test	Result
<p>inflammatory response.[69] [70] [71] [72] [73] In viral encephalitis an initial polymorphonuclear (PMN) predominance followed by a mononuclear shift in 24 to 48 hours (except in West Nile virus) is seen. Lymphocytosis (viruses, TB); atypical lymphocytes (Epstein-Barr virus, cytomegalovirus, rarely in HSV); PMN leukocytosis (bacterial infections, acute disseminated encephalomyelitis, acute hemorrhagic leukoencephalitis, amebic infections, occasionally in some viruses such as West Nile virus). Eosinophilia (TB, fungal infection, <i>Baylisascaris procyonis</i>, <i>Angiostrongylus cantonensis</i>, <i>Gnathostoma</i> species).</p> <ul style="list-style-type: none"> • CSF protein >100 mg/dL, or CSF glucose <2/3 peripheral glucose, or lymphocytic pleocytosis with subacute symptom onset suggests TB or fungal infection. • CSF protein >100 mg/dL or CSF glucose <2/3 peripheral glucose and neutrophilic predominance with acute symptom onset and recent antibiotic use suggests <i>Streptococcus pneumoniae</i> or <i>Neisseria meningitidis</i>. 	
<p>CSF culture</p> <ul style="list-style-type: none"> • Culture: very useful in identifying etiologies, particularly bacterial. Only useful for a few viruses (mumps, enterovirus, lymphocytic choriomeningitis virus). Viral cultures are rarely positive, and if negative do not exclude infection.[26] • Antigen testing: useful in rapidly identifying bacterial and fungal etiologies of encephalitis. • Gram stain: detection of organisms in bacterial causes. • Acid-fast stain: tuberculosis. • India ink: <i>Cryptococcus</i>. 	<p>findings depend on etiology</p>
<p>CSF serology</p> <ul style="list-style-type: none"> • Serologic indexing is required for definitive diagnosis and compares CSF to serum-specific antibody levels in reference to total CSF, serum albumin, or total immunoglobulin. For viruses, a 4-fold rise in IgG from acute to convalescent specimens, or a single positive IgM, is also considered diagnostic.[74] [75] 	<p>findings depend on etiology; more sensitive for detection of arboviruses, including West Nile virus</p>
<p>CSF polymerase chain reaction (PCR)</p> <ul style="list-style-type: none"> • CSF analysis should include PCR for common viral causes of encephalitis as a first-line screen and subsequent targeted PCRs for additional viruses based on the risk factors, exposure, and clinical picture. 	<p>findings depend on etiology; viruses (enterovirus, poliovirus, arboviruses, herpes simplex virus (HSV)-1, HSV-2, varicella zoster virus, cytomegalovirus, Epstein-Barr virus, lymphocytic choriomeningitis virus, adenovirus, measles, HIV, rabies); bacteria (<i>Mycoplasma pneumoniae</i>, tuberculosis); fungus (cryptococcus, aspergillosis)</p>

Other tests to consider

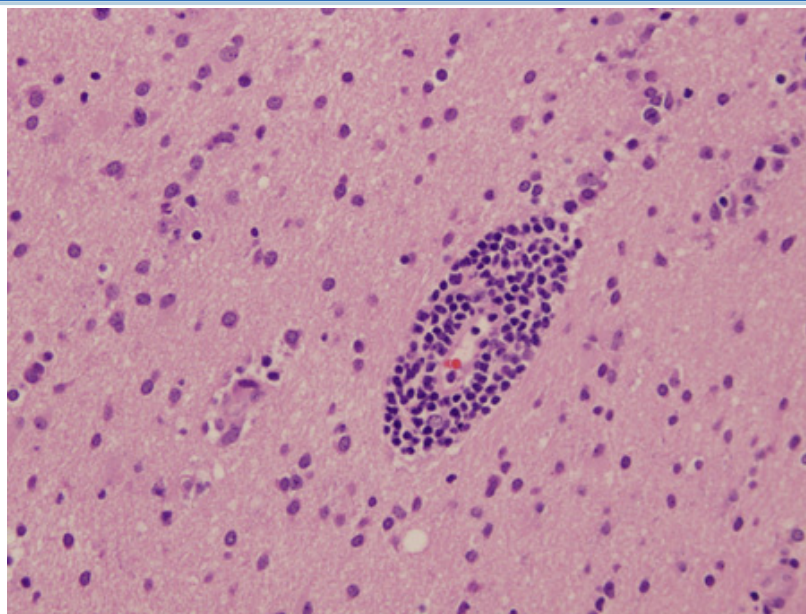
Test	Result
stool enteroviral culture <ul style="list-style-type: none"> Obtained more frequently in children when gastrointestinal symptoms precede the development of encephalitis. Stool culture may also be used to detect poliovirus. 	detection of enterovirus
sputum culture <ul style="list-style-type: none"> Obtained in patients with a febrile illness and pulmonary symptoms or signs. 	detection of <i>Mycoplasma</i>, tuberculosis (acid-fast stain), and fungal infections
IgG and IgM antibodies (blood or CSF) <ul style="list-style-type: none"> Obtained when a viral cause for encephalitis is suspected. IgG and IgM antibodies directed against specific viral pathogens may be detected by serum or CSF studies. 	detection of IgG/IgM antibodies to enterovirus, poliovirus, arboviruses, varicella zoster virus, cytomegalovirus, Epstein-Barr virus, lymphocytic choriomeningitis virus, mumps, measles, HIV, rabies, and West Nile virus
PCR (blood) <ul style="list-style-type: none"> Obtained when a viral cause for encephalitis is suspected 	detection of enterovirus, poliovirus, arboviruses, varicella zoster virus, cytomegalovirus, Epstein-Barr virus, and HIV
HIV serology/RNA test <ul style="list-style-type: none"> Reasonable to screen in all admitted patients, but should definitely be tested in people with risk factors for HIV infection. HIV may result in an acute encephalopathy with seroconversion. Quantitative viral RNA in plasma is used to confirm acute retroviral syndrome (i.e., symptomatic patients before the HIV antibody test is positive). HIV-associated encephalitis may also be due to an opportunistic infection. 	positive in cases of HIV infection
CSF biomarkers/prion protein assay <ul style="list-style-type: none"> Patients with suspected prion disease should have CSF testing. Real-time quaking-induced conversion assay (RT-QuIC) uses amplification technology to detect prion protein (PrP^{Sc}) and has higher detection sensitivity than biomarkers.^[76] 	elevated 14-3-3 protein, elevated tau protein; detection of prion protein
paraneoplastic antibodies (blood and CSF) <ul style="list-style-type: none"> Obtained when an underlying cancer is found and/or suspected. 	paraneoplastic antibodies such as anti-N-methyl-D-aspartate receptor, anti-LGI1, anti-CASPR2, anti-Hu, anti-Yo, anti-Ri, anti-Tr, anti-CV2, anti-Ma, anti-amphiphysin may be found
abdominal/pelvic ultrasound <ul style="list-style-type: none"> Obtained when anti-N-methyl-D-aspartate receptor encephalitis is suspected. If malignancy screening is negative, repeating the assessment 3 to 6 months later should be considered in cases where the autoantibody found is strongly associated with malignancy.^{[1] [51]} 	detection of underlying ovarian teratoma

Test	Result
whole-body CT <ul style="list-style-type: none"> Performed later in the clinical course as part of the clinical workup for suspected underlying cancers (e.g., lung, breast, or ovarian) that are associated with limbic or brainstem encephalitis. If malignancy screening is negative, repeating the assessment 3 to 6 months later should be considered in cases where the autoantibody found is strongly associated with malignancy.[1] [51] 	detection of underlying cancers
whole-body PET scans <ul style="list-style-type: none"> Performed later in the clinical course as part of the clinical workup for suspected underlying cancers (e.g., lung, breast, or ovarian) that are associated with limbic or brainstem encephalitis. If malignancy screening is negative, repeating the assessment 3 to 6 months later should be considered in cases where the autoantibody found is strongly associated with malignancy.[1] [51] 	detection of underlying cancers
magnetic resonance spectroscopy <ul style="list-style-type: none"> Specialist centers only. Obtained in patients with a clinical diagnosis of encephalitis but in whom the etiology is unknown, or if the diagnosis of encephalitis is suspected but cannot be differentiated from brain tumors. 	metabolic data aiding identification of etiology
next-generation sequencing of CSF <ul style="list-style-type: none"> Specialist centers only. The use of personalized genomics to diagnose etiologic infectious agents.[77] As opposed to directed PCR amplification of a selected number of targets, technology is now available to detect organisms in an unbiased manner. Genetic material is isolated from organisms, and select DNA and RNA sequences can be amplified with universal primers. The sequence is then compared with publicly available sequences to identify the organism. 	detection and identification of organism
brain biopsy <ul style="list-style-type: none"> Currently the criterion standard for diagnosis. Not routinely performed as it is invasive, requires general anesthesia, and is associated with some morbidity. With the increasing availability of MRI and PCR-based diagnostic methods, the need for brain biopsy is decreasing. It is still very useful in diagnostically challenging cases; stereotactic biopsy should be considered in patients with suspected encephalitis in whom no diagnosis has been made after the first week, especially if there are focal abnormalities on imaging and no clinical improvement.[13] If imaging shows nothing focal, an open biopsy, usually from the nondominant frontal lobe, may be preferable.[13] Immunocytochemistry, in situ hybridization, and PCR can be performed on biopsy/autopsy specimens, and have had a profound impact on the ability to diagnose the various etiologies of encephalitis. Classic encephalitic nodules are composed of a mixture of microglia, astrocytes, and lymphocytes around affected neurons, cytologic features such as inclusion bodies (intranuclear in herpes simplex virus, varicella zoster virus, subacute sclerosing panencephalitis, and cytoplasmic Negri bodies in rabies), and cytomegalic cell changes (cytomegalovirus). In acute disseminated encephalomyelitis, multiple small demyelinated foci are arranged around small veins of the white matter, with infiltration by lymphocytes, macrophages, and microglia. In cryptococcal meningoencephalitis, the <i>Cryptococcus</i> 	damage to the brain parenchyma (usually nerve cell damage or loss, eventually demyelination), reactive gliosis, and inflammatory cellular infiltration

Test	Result
<p>can be seen. In HIV encephalitis, distinctive multinucleated giant cells can be seen; however, in CD8 encephalitis, intraparenchymal and perivascular CD8+ T-cells infiltrations are seen (while multinucleated giant cells are absent). In toxoplasmosis, the organism can be identified. Creutzfeldt-Jakob disease presents with spongiform changes.</p>  <p><i>Biopsy of brain from right temporal lobe: the classic H&E stain shows evidence of patchy but extensive inflammatory infiltrate of small mononuclear cells (lymphocytes) in the brain parenchyma, predominantly around the blood vessel walls. PCR studies of the biopsy sample were positive for EBV infection</i> <i>From the personal collection of Catalina C. Ionita, MD; used with permission</i></p>	

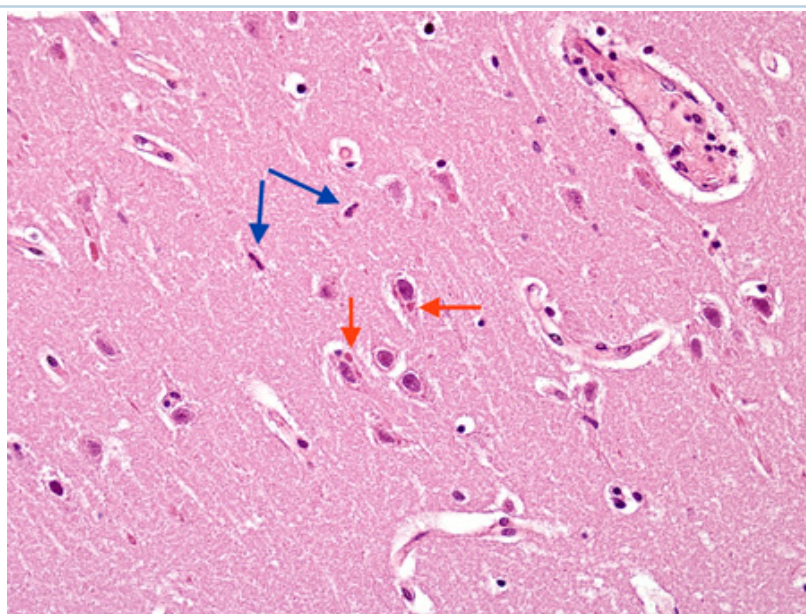
Test

Result



Biopsy of brain from right temporal lobe: a close-up view of a blood vessel with its surrounding marked inflammatory infiltrate is also seen. PCR studies of the biopsy sample were positive for EBV infection.

From the personal collection of Catalina C. Ionita, MD; used with permission



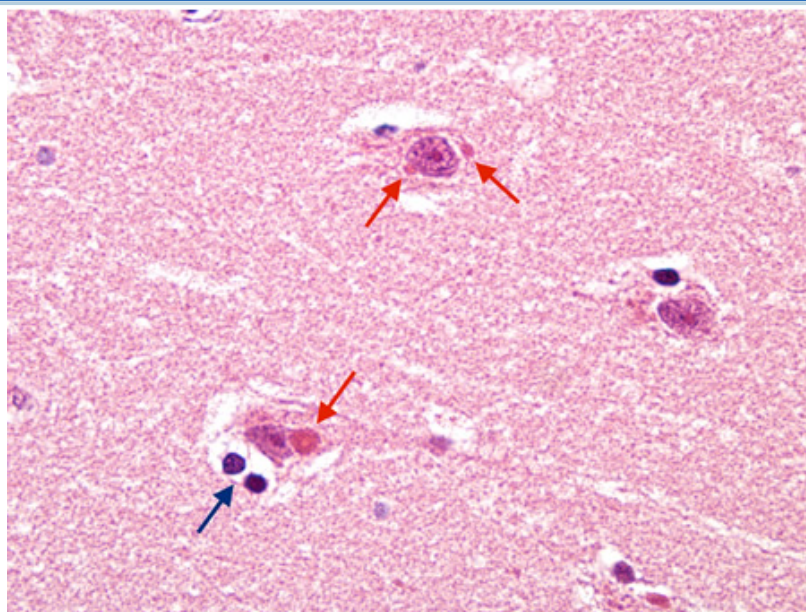
Biopsy from hippocampus of patient with rabies showing 2 neurons with eosinophilic Negri bodies (red arrows).

These are found in areas, often with little inflammatory reaction. The blue arrows highlight microglial cells

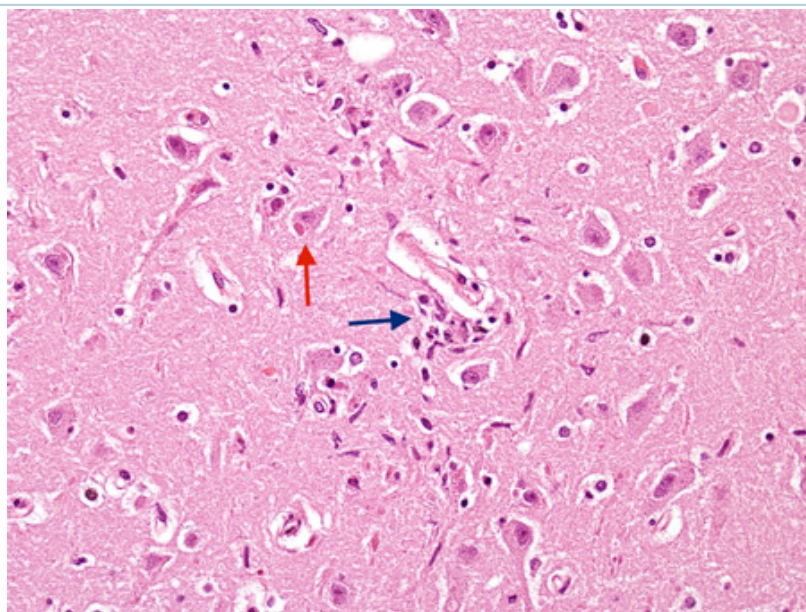
From the personal collection of Robert E. Schmidt; used with permission

Test

Result



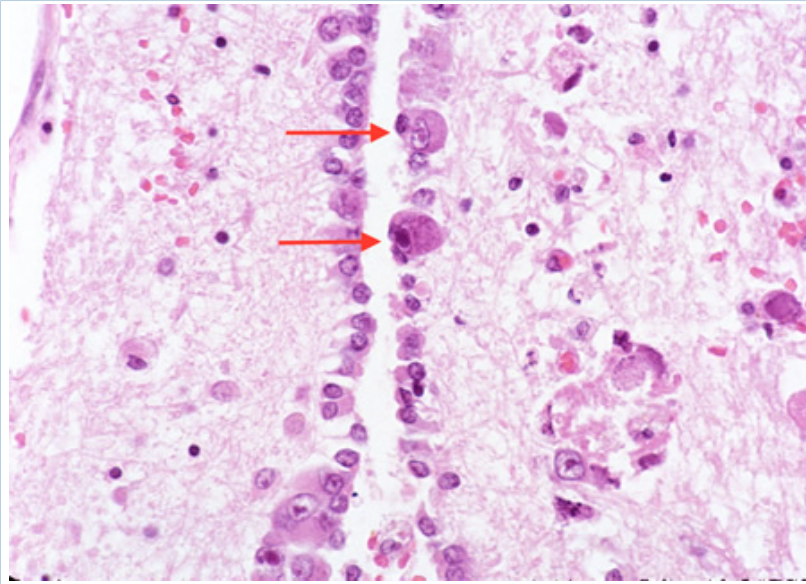
Biopsy from hippocampus of patient with rabies showing neurons with eosinophilic Negri bodies (red arrow). The blue arrow highlights a collection of satelliting oligodendrocytes
From the personal collection of Robert E. Schmidt; used with permission



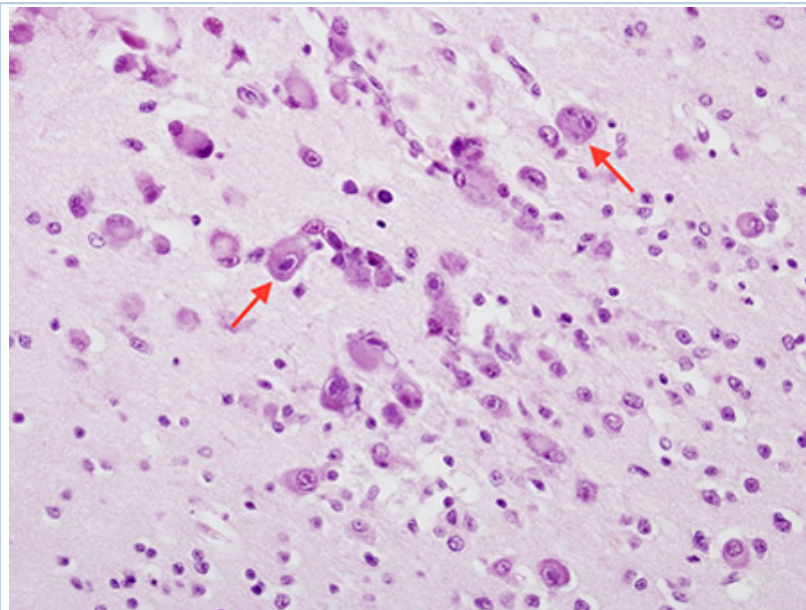
Biopsy from hippocampus of patient with rabies showing a neuron with an eosinophilic cytoplasmic Negri body (red arrow). The blue arrow highlights a collection of microglial cells next to a blood vessel
From the personal collection of Robert E. Schmidt; used with permission

Test

Result



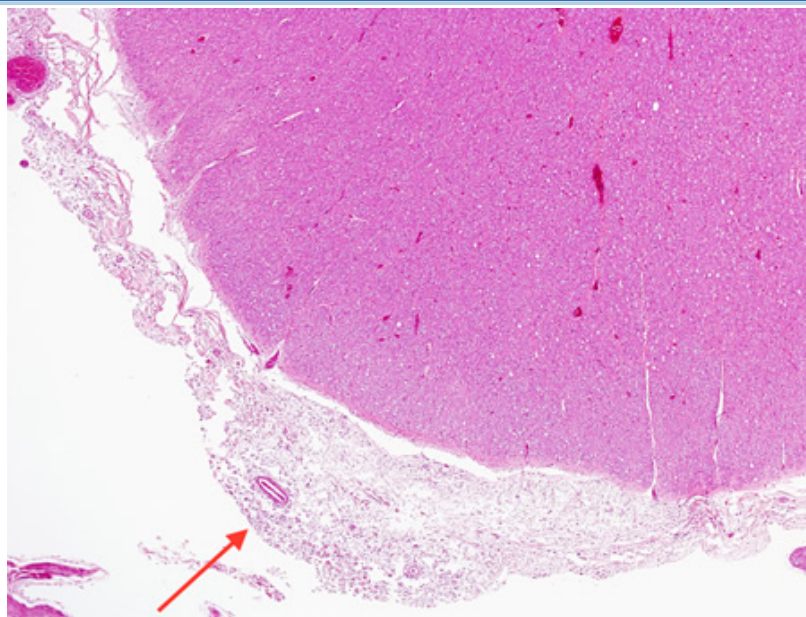
*Biopsy from the brainstem of HIV patient with CMV encephalitis. The ependymal lining shows enlarged cells (arrows) with intranuclear inclusions
From the personal collection of Robert E. Schmidt; used with permission*



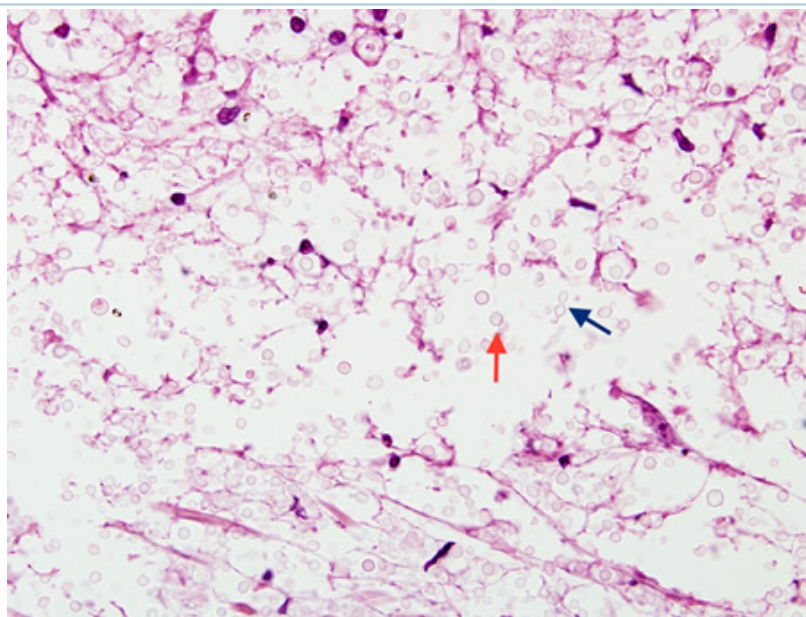
*Biopsy from cortex of neonate with CMV encephalitis showing enlarged cells (arrows) with intranuclear inclusions. The top arrow points to a neuron with two nuclei each with a nuclear inclusion
From the personal collection of Robert E. Schmidt; used with permission*

Test

Result



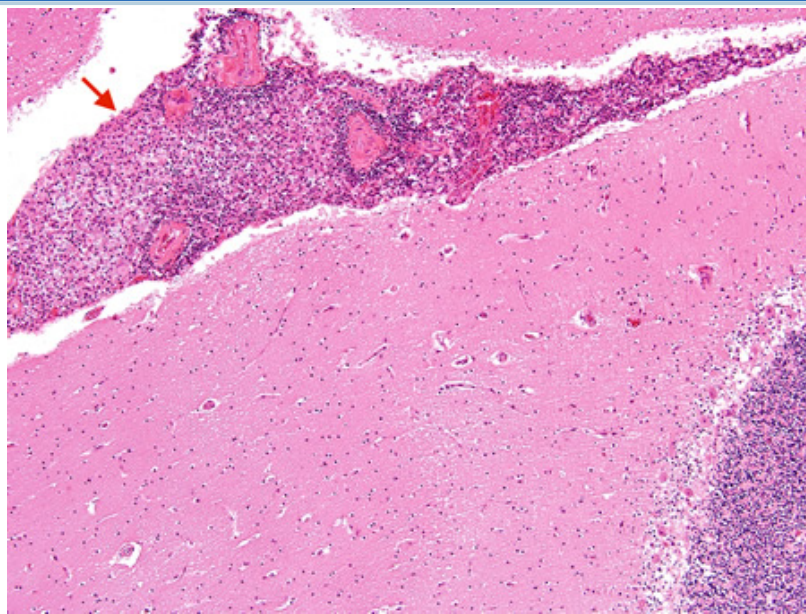
Biopsy from brain of immunocompromised patient with cryptococcal meningitis at low magnification. The meninges are expanded (arrow), but the cortex is histologically relatively uninvolved
 From the personal collection of Robert E. Schmidt; used with permission



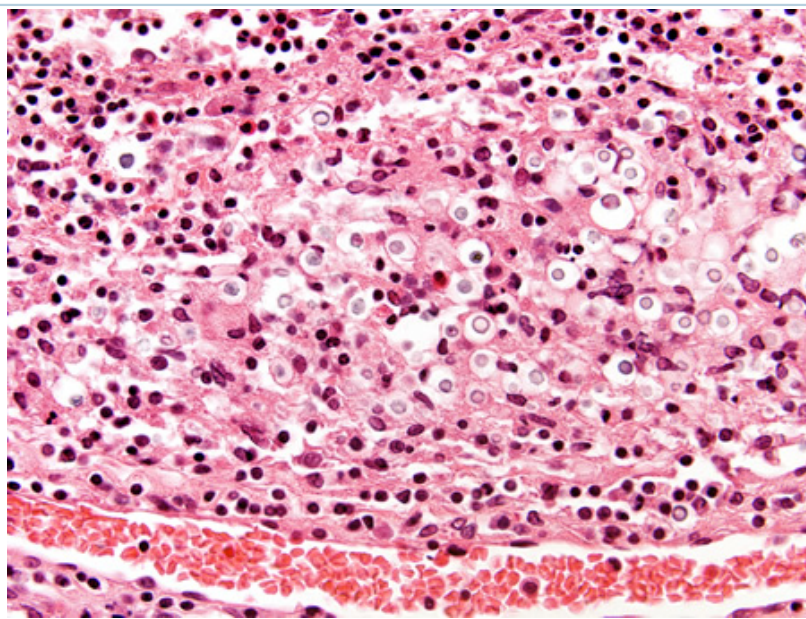
Biopsy from brain of immunocompromised patient with cryptococcal meningitis showing the meninges with round translucent cryptococcal organism (red arrow) as well as a budding yeast (blue arrow)
 From the personal collection of Robert E. Schmidt; used with permission

Test

Result



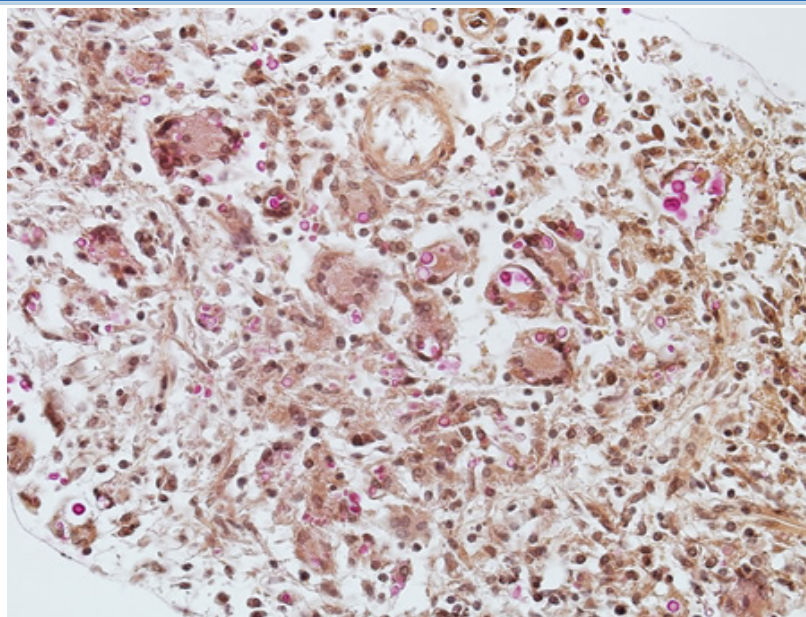
Biopsy from brain of an immunocompetent patient with cryptococcal meningitis at low magnification showing the meninges with inflammation (red arrow)
From the personal collection of Robert E. Schmidt; used with permission



Biopsy from brain of immunocompetent patient with cryptococcal meningitis showing the meninges with inflammatory cells and Cryptococcus
From the personal collection of Robert E. Schmidt; used with permission

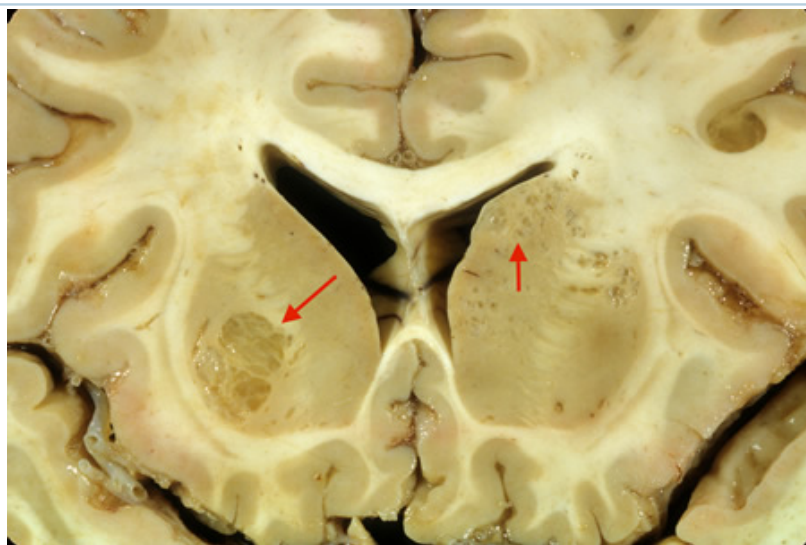
Test

Result



Biopsy from meninges of patient with cryptococcal meningitis stained with mucicarmine, demonstrating fungal organisms, particularly in giant cells

From the personal collection of Robert E. Schmidt; used with permission

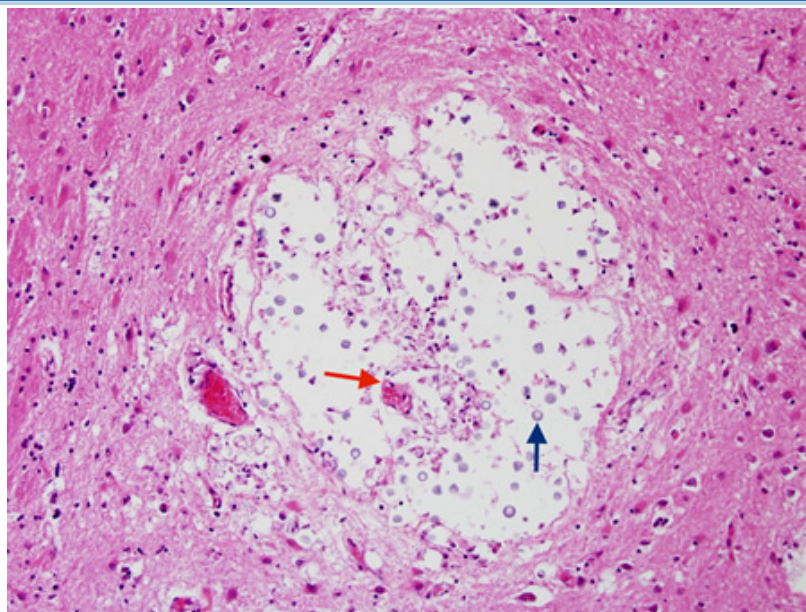


Coronal slice of the brain of patient with cryptococcal meningoencephalitis showing classical appearance of "soap bubble" structures in the basal ganglia (arrows) resulting from the cryptococcal expansion of Virchow-Robin spaces around the lenticulostriate vessels

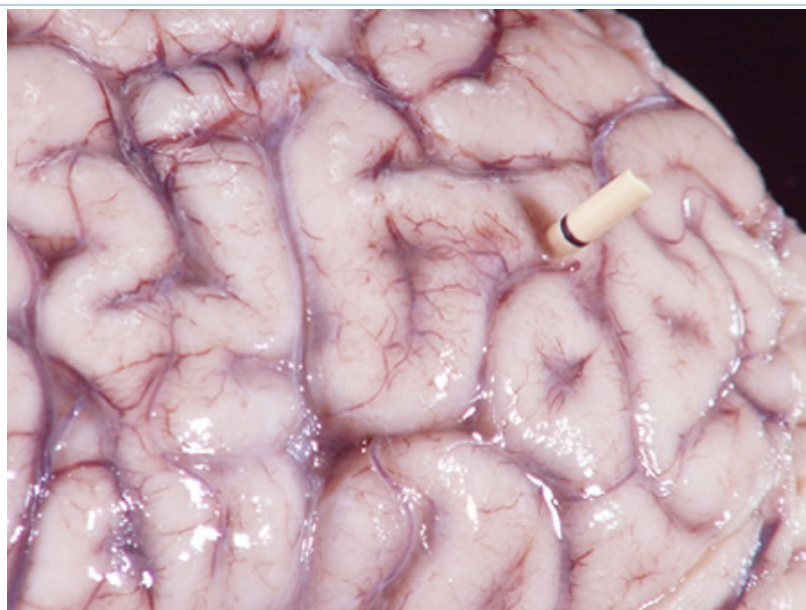From the personal collection of Robert E. Schmidt; used with permission

Test

Result



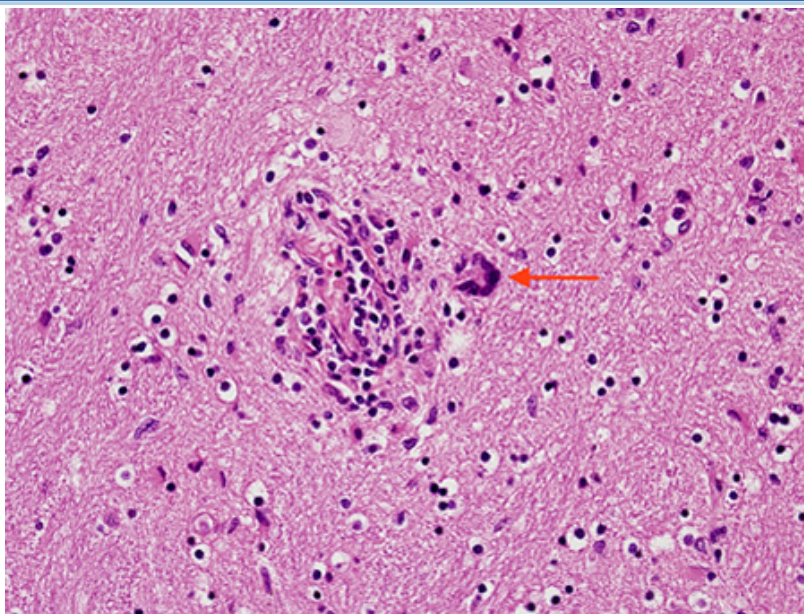
*Biopsy from basal ganglia of patient with cryptococcal meningoencephalitis showing cryptococcal (blue arrow) expansion of Virchow-Robbin spaces around a lenticulostriate vessel (red arrow)
From the personal collection of Robert E. Schmidt; used with permission*



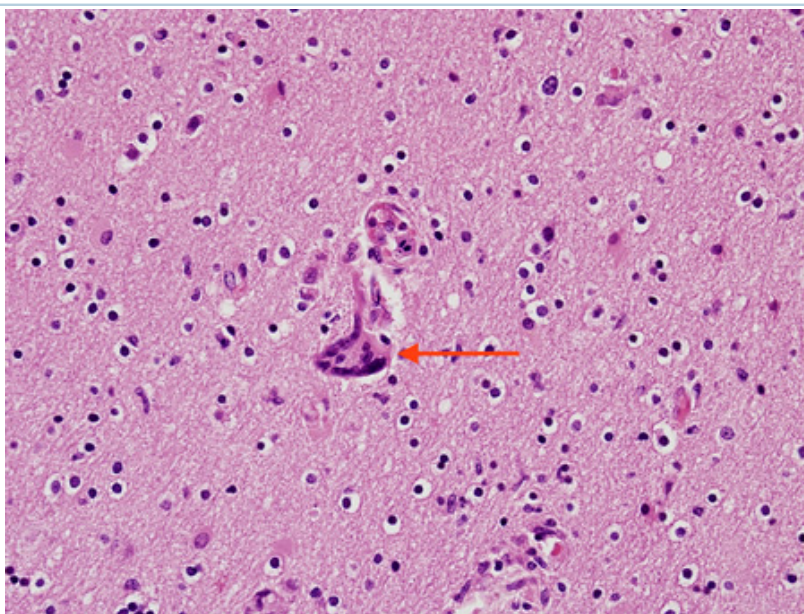
*Gross autopsy of brain of patient with cryptococcal meningitis showing the surface with a "glazed" look. There is also a shunt present
From the personal collection of Robert E. Schmidt; used with permission*

Test

Result



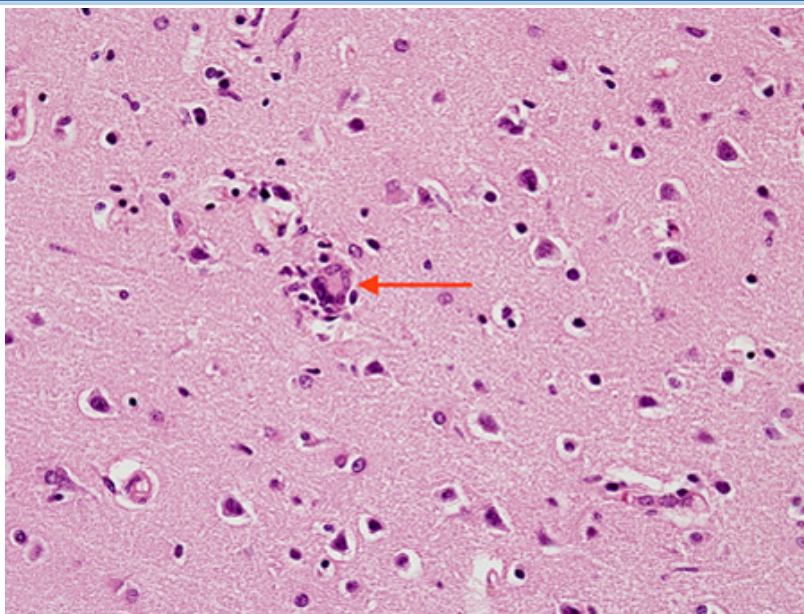
Biopsy from brain of patient with subacute HIV leukoencephalitis showing the distinctive multinucleated cell (red arrow) in the white matter next to inflammatory cells in the Virchow-Robin space
 From the personal collection of Robert E. Schmidt; used with permission



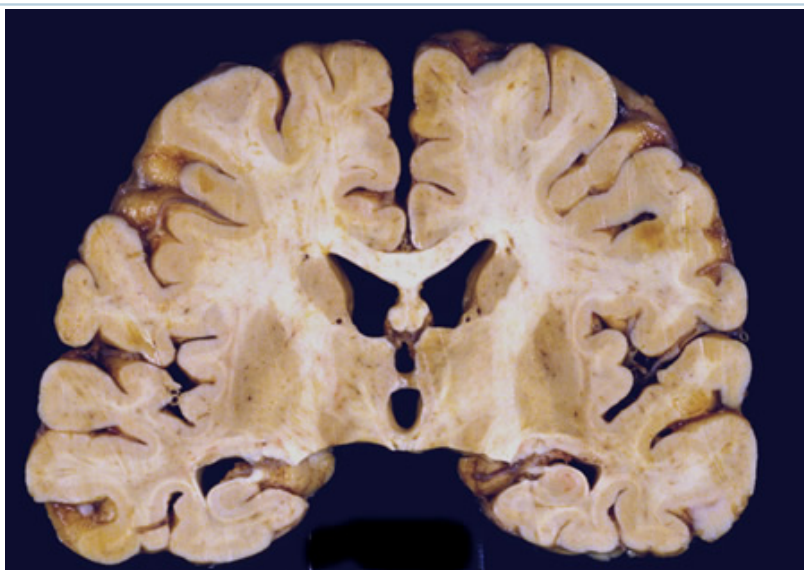
Biopsy from brain of patient with subacute HIV leukoencephalitis showing the distinctive multinucleated cell (red arrow) in the white matter
 From the personal collection of Robert E. Schmidt; used with permission

Test

Result



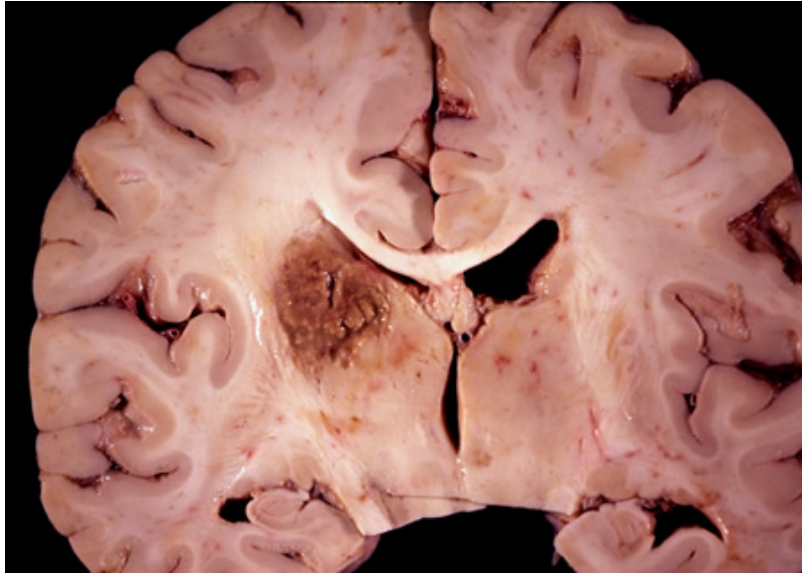
Biopsy from brain of patient with subacute HIV encephalitis showing the distinctive multinucleated giant cell (red arrow), which contains the HIV virus. The multinucleated giant cells are from histiocyte/macrophage lineage. There is also associated astrocytosis. From the personal collection of Robert E. Schmidt; used with permission



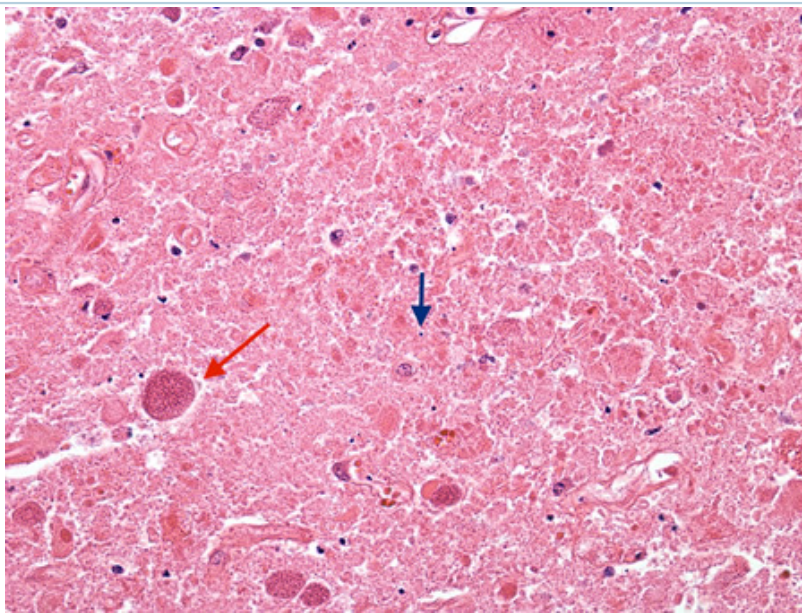
Coronal slice of the brain of HIV patient in his 30s. He had subacute HIV encephalitis involving both the white matter and gray matter diffusely. The ventricles were enlarged reflecting white matter and cortical loss. From the personal collection of Robert E. Schmidt; used with permission

Test

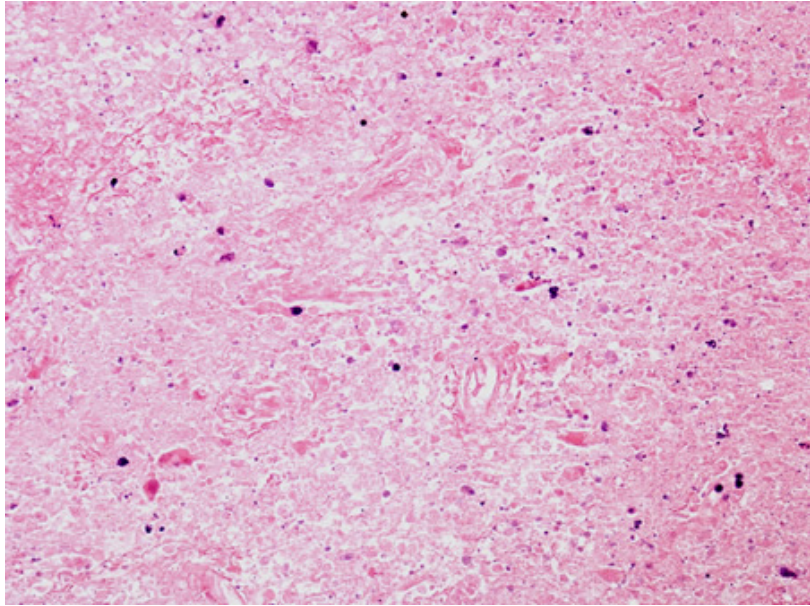
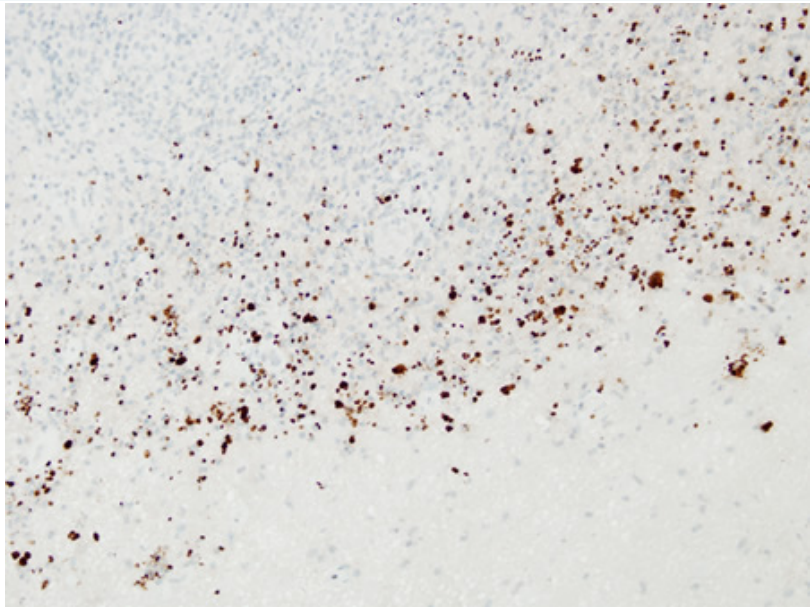
Result

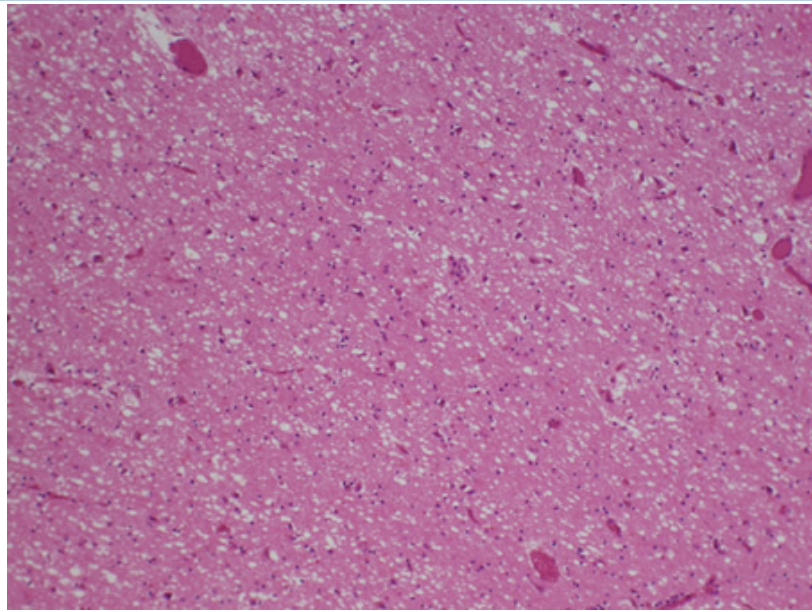


Coronal slice of the brain of HIV patient with toxoplasmosis, showing infection of the periventricular superior part of the left thalamus
From the personal collection of Robert E. Schmidt; used with permission



Biopsy of the brain of an HIV patient with toxoplasmosis, showing encysted bradyzoites (red arrow) and tachyzoites (blue arrow)
From the personal collection of Robert E. Schmidt; used with permission

Test	Result
	<p><i>Biopsy of HIV patient with toxoplasmosis, showing both pieces of cellular debris and tachyzoites. The tachyzoites are round, smooth, and hard to identify without antibody staining (see next image)</i></p> <p><i>From the personal collection of Robert E. Schmidt; used with permission</i></p>
	<p><i>Biopsy of HIV patient with toxoplasmosis, with the tachyzoites identified using immunohistochemistry</i></p> <p><i>From the personal collection of Robert E. Schmidt; used with permission</i></p>

Test	Result
<div></div> <div><p><i>Biopsy of the posterior thalamus of patient with Creutzfeldt-Jakob disease showing the spongiform changes</i></p><p><i>From the personal collection of Robert E. Schmidt; used with permission</i></p></div>	

Differentials

Condition	Differentiating signs / symptoms	Differentiating tests
Viral meningitis	<ul style="list-style-type: none"> Headache, neck stiffness, and fever with no altered mental status (maybe mild somnolence) or focal neurologic signs. Frequently meningitis and encephalitis coexist (meningoencephalitis). 	<ul style="list-style-type: none"> MRI evidence of meningeal enhancement, with no evidence of brain parenchymal involvement.
Encephalopathy (toxic/metabolic)	<ul style="list-style-type: none"> A multitude of metabolic factors and remote infections can cause brain parenchymal dysfunction without structural damage to the brain. Frequently encountered in hospital/nursing home settings. Altered mental status and even focal neurologic signs (hypoglycemia) can be seen with both conditions, and there are no specific clinical differentiating features. 	<ul style="list-style-type: none"> Normal cerebrospinal fluid analysis, normal MRI, electroencephalogram - diffuse slowing, triphasic waves.
Status epilepticus	<ul style="list-style-type: none"> There are no specific clinical differentiating features, and status epilepticus is not uncommonly seen in patients with encephalitis so can be considered a clinical feature of this disease. In cases that are clearly not due to encephalitis (MRI, cerebrospinal fluid negative), the patient frequently has a known seizure disorder with subtherapeutic levels of medications. 	<ul style="list-style-type: none"> Electroencephalogram - evidence of ongoing seizure activity.
Central nervous system vasculitis	<ul style="list-style-type: none"> There are no specific clinical differentiating features. Headaches and focal neurologic signs can be seen. 	<ul style="list-style-type: none"> Differentiated by MRI, angiography, and biopsy. MRI - evidence of multiple small strokes, usually cortical. Angiography - can be normal but frequently a typical angiographic appearance of multisegment narrowing/beading of the vessels is noted.

Condition	Differentiating signs / symptoms	Differentiating tests
		<ul style="list-style-type: none"> Definitive diagnosis sometimes requires brain and meningeal biopsy, which will show evidence of inflammation (i.e., presence of inflammatory cells such as lymphocytes in the vessel wall and surrounding the blood vessel, along with structural alterations of the involved vessels).
Headache with neurologic deficits and CSF lymphocytosis (confusional migraine with pleocytosis)	<ul style="list-style-type: none"> Acute confusion, psychosis, and focal neurologic deficits in association with migraine headache is seen in some migraine patients.[78] and in familial hemiplegic migraine.[79] These are suggestive of but not specific to migraine. 	<ul style="list-style-type: none"> Cerebrospinal fluid - elevated WBC count with no evidence of infection.
Malignant hypertension	<ul style="list-style-type: none"> High blood pressure, headaches, altered mental status, and visual symptoms can be seen. 	<ul style="list-style-type: none"> Elevated BP (usually >220/110 mmHg). But may be sudden acute elevations even at lower blood pressure. Differentiated by fundoscopy, CT, and MRI. Fundus examination - papilledema and hemorrhage. CT usually normal, but occasionally hypodense lesions seen over occipital lobes. MRI: T2 and fluid attenuated inversion recovery (FLAIR) hyperintense lesions over the occipital lobes (usually asymmetric). Increased diffusion on diffusion-weighted imaging (with apparent diffusion coefficient maps showing increased diffusion) is also seen. The term "posterior reversible leukoencephalopathy syndrome (PRES)" is also used to describe the MRI changes.
Posterior reversible leukoencephalopathy syndrome (PRES)	<ul style="list-style-type: none"> Headache, confusion, seizures, visual loss, focal deficits; pathogenesis includes immunosuppressive 	<ul style="list-style-type: none"> MRI: T2/fluid attenuated inversion recovery (FLAIR) lesions throughout the brain.

Condition	Differentiating signs / symptoms	Differentiating tests
	therapy, renal failure, eclampsia, hypertension, lupus.	
Intracranial tumors and cysts	<ul style="list-style-type: none"> • There are no specific clinical differentiating features. • A variety of clinical presentations, such as headache worse on awakening, altered mental status, seizures, and focal neurologic deficits are seen with intracranial neoplasms. 	<ul style="list-style-type: none"> • CT and MRI imaging of the brain (preferably MRI) can help diagnose these conditions. Biopsy - required in some cases to make a definitive diagnosis.
Neurosarcoidosis	<ul style="list-style-type: none"> • There are no specific clinical differentiating features. Cranial neuropathies (especially CN II and VII), spinal cord involvement, disruption of the hypothalamic/pituitary axis, and peripheral neuropathy may be accompanying features. Additional systemic features include lung disease, erythema nodosum, lymphadenopathy, arthralgias, and uveitis. 	<ul style="list-style-type: none"> • Brain MRI with contrast may demonstrate meningeal enhancement. LP may show pleocytosis (lymphocytic predominant) and elevated total protein; glucose levels are sometimes low. Serum and cerebrospinal fluid ACE levels can be assessed, but may yield both false negative and false positive results. Chest radiography, whole-body (18F)-fluoro-2-deoxy-D-glucose positron emission tomography (FDG-PET), and gallium scanning can be considered in individuals without a known diagnosis of sarcoidosis. Biopsy should be considered for pathologic diagnosis of noncaseating granulomas, especially if a non-CNS lesion is identified.
Systemic lupus erythematosus (SLE)	<ul style="list-style-type: none"> • There are no specific clinical differentiating features. Headache, neuropsychiatric issues, and seizures can be seen. • Systemic features include skin changes (e.g., butterfly rash, discoid rash), arthritis, serositis, hematologic abnormalities, renal disorder, and immunologic abnormalities. 	<ul style="list-style-type: none"> • Serum immunology tests for antinuclear antibody, anti-double stranded DNA antibody, anti-Smith antibody, and antiphospholipid antibody are positive in most patients with SLE.
Intracranial bleed	<ul style="list-style-type: none"> • There are no specific clinical differentiating features. Headache, altered mental status, seizures, and focal 	<ul style="list-style-type: none"> • CT and MRI can clearly demonstrate acute intracranial bleeds. In subarachnoid hemorrhage, a lumbar puncture may

Condition	Differentiating signs / symptoms	Differentiating tests
	neurologic deficits can be seen.	show xanthochromia and no change in the number of red blood cells from tube 1 to tube 4.
Traumatic brain injury	<ul style="list-style-type: none"> • A history of head injury is frequently obtained, but can be unavailable in someone who is found unresponsive. • Headache, varying degrees of altered mental status, and focal neurologic findings can be seen. • There are no specific clinical differentiating features. 	<ul style="list-style-type: none"> • CT and MRI will reveal various intracranial bleeds that are associated with head injury; concussions have normal imaging findings; diffuse axonal damage can be seen as signal abnormality in MRI images.
Ischemic stroke	<ul style="list-style-type: none"> • There are no specific clinical differentiating features. • Sudden onset of focal neurologic deficits, altered mental status, seizures, and headaches. • Certain strokes, such as those involving the posterior cerebral artery, basilar artery, and anterior cerebral artery, can present with an encephalopathic clinical picture. • It is important to note that ischemic stroke can also occur as a complication of some cases of encephalitis. 	<ul style="list-style-type: none"> • CT scan - low attenuation in the involved areas. • MRI - diffusion-weighted imaging evidence of decreased diffusion is characteristic of acute ischemic stroke. Fluid attenuated inversion recovery (FLAIR) and T2 hyperintense lesions are seen in subacute cases.
Mitochondrial encephalopathy lactic acidosis and stroke-like episodes (MELAS)	<ul style="list-style-type: none"> • There are no specific clinical differentiating features. Hearing loss, encephalopathy, seizures, stroke-like episodes, and presence of lactic acidosis are characteristic clinical features. 	<ul style="list-style-type: none"> • Cerebrospinal fluid lactate - elevated • MRI - T2 hyperintense signal in territory not conforming to major vascular regions. Diffusion-weighted imaging evidence of increased diffusion. • Genetic test - mitochondrial DNA point mutations (A3243G mutation in 80% of cases). • Muscle biopsy - ragged red fibers on modified Gomori trichrome stain.
Inborn errors of metabolism	<ul style="list-style-type: none"> • History of parental consanguinity, early neonatal death, maternal acute fatty liver of pregnancy and HELLP syndrome (elevated liver enzymes 	<ul style="list-style-type: none"> • Serum ammonia may be elevated (urea cycle defect, organic acidemias). Arterial blood gas can show a metabolic acidosis with elevated anion gap. Urine

Condition	Differentiating signs / symptoms	Differentiating tests
	and low platelets) in pregnancy. May be lethargic and irritable with poor feeding. Physical exam may reveal jaundice, cataracts, hepatosplenomegaly, abnormal muscle tone, dysmorphism (e.g., coarse facial features), and abnormal body odor. May present with life-threatening encephalopathy.[80] [81]	orotic acid is low in carbamyl phosphate synthetase deficiency and elevated in ornithine transcarbamylase deficiency.[81]
Bacterial meningitis	<ul style="list-style-type: none"> History of headache, neck stiffness, photophobia, and fever. Physical exam may reveal fever, neck stiffness, and focal neurologic abnormalities. 	<ul style="list-style-type: none"> Cerebrospinal fluid shows elevated WBC often with neutrophil predominance, elevated protein, and low glucose. Gram stain and polymerase chain reaction may reveal the causative organism.[82]
Fungal meningitis	<ul style="list-style-type: none"> History of headache, neck stiffness, photophobia, and fever. History of immunosuppression may be present. Physical exam may reveal fever, neck stiffness, and focal neurologic abnormalities. 	<ul style="list-style-type: none"> Cerebrospinal fluid culture may demonstrate fungal growth.

Criteria

Diagnostic definition[2]

Diagnostic criteria for encephalitis and encephalopathy of presumed infectious or autoimmune etiology

- Major criterion (required):
 - Patients presenting to medical attention with altered mental status (defined as decreased or altered level of consciousness, lethargy, or personality change) lasting ≥ 24 hours with no alternative cause identified.
- Minor criteria (2 required for possible encephalitis; ≥ 3 required for probable or confirmed encephalitis):
 - Documented fever $\geq 100.4^{\circ}\text{F}$ (38°C) within the 72 hours before or after presentation
 - Generalized or partial seizures not fully attributable to a preexisting seizure disorder
 - New onset of focal neurologic findings
 - Cerebrospinal fluid WBC count $\geq 5/\text{mm}^3$
 - Abnormality of brain parenchyma on neuroimaging suggestive of encephalitis that is either new from prior studies or appears acute in onset

- Abnormality on electroencephalography that is consistent with encephalitis and not attributable to another cause.

Confirmed encephalitis requires one of the following:

- Pathologic confirmation of brain inflammation consistent with encephalitis
- Defined pathologic, microbiologic, or serologic evidence of acute infection with a microorganism strongly associated with encephalitis from an appropriate clinical specimen
- Laboratory evidence of an autoimmune condition strongly associated with encephalitis.

Approach

Encephalitis is a medical emergency; hence, management consists of basic resuscitation measures ensuring adequacy of the airway, breathing, and circulation, and empiric antiviral therapy in cases of suspected viral encephalitis concurrently with diagnostic steps.[47]

All suspected cases of encephalitis should be admitted and fully evaluated. Some patients with milder symptoms and signs can be managed in a regular nursing unit, with access to an intensive care unit (ICU) bed if needed. All other patients, and in particular those with complications (e.g., significant electrolyte abnormalities, strokes, elevated intracranial pressure [ICP], cerebral edema, coma, seizures activity, or status epilepticus) should be managed in an ICU, preferably a neurointensive care unit.[33] [83]

Prompt isolation is required for all forms of encephalitis until the etiology is determined; encephalitides with airborne or contact transmission to immunocompetent hosts (herpes simplex virus [HSV], varicella, mumps, rubella, enteroviruses, upper respiratory viral infections) require isolation according to local regulations. The microbiology laboratory should be alerted if unusual organisms are suspected (e.g., *Treponema pallidum*, *Listeria* species, *Mycoplasma* species, *Rickettsia rickettsii*), for which special microbiologic procedures are necessary.[26] Most cases of infectious encephalitis involve close collaboration between the treating clinicians and infectious disease team.

Etiology is often unknown, and therefore no specific treatment options exist for the majority of cases. However, for cases where a diagnosis is reasonably certain, treatment is directed toward the underlying offending agent if available (e.g., antivirals for viral encephalitis; appropriate anti-infective measures in bacterial, fungal, or parasitic infections).

Supportive measures

Supportive care is the cornerstone of treatment in most cases. This may include endotracheal intubation and mechanical ventilation, circulatory and electrolyte support, prevention and management of secondary bacterial infections, deep venous thrombosis prophylaxis, and gastrointestinal (ulcer) prophylaxis. Antiretroviral therapy is an important treatment in all cases of HIV-associated encephalitis (whether due to HIV itself or to an opportunistic infection); in CD8 encephalitis, patients respond well to corticosteroids.[84] [85] For certain opportunistic infections, such as cryptococcus, antiretroviral therapy should be delayed based on World Health Organization guidelines.[86] [87][88]

In patients with elevated ICP, initial measures are elevation of head of bed to 30° to 45°, avoiding compression of the jugular veins, and brief episodes of hyperventilation.[89] Subsequently, hyperosmolar therapy with mannitol boluses or hypertonic saline can be used to decrease ICP.[90] In children with elevated ICP, maintaining cerebral perfusion pressure ≥ 60 mm Hg, using normal saline bolus and vasoactive therapy-dopamine, may be superior to maintaining intracranial pressure < 20 mm Hg, using osmotherapy while ensuring normal blood pressure, in reducing mortality and morbidity.[91]

Antiviral therapies

All cases of suspected community-acquired viral encephalitis are started empirically on acyclovir until the cause is determined.[13] As most cases of sporadic viral encephalitis are secondary to HSV, this is good clinical practice supported by biopsy-proven randomized controlled trials, and it reduces mortality.[47] [92] Delays in treatment initiation beyond 48 hours after hospital admission are associated with a worse outcome in both children and adults.[13] [93] In an immunocompromised patient, cytomegalovirus (CMV) encephalitis is a consideration. If suspected, ganciclovir and foscarnet are given with acyclovir

until HSV polymerase chain reaction is available. If HSV encephalitis is excluded, then acyclovir can be discontinued. In some cases, magnetic resonance imaging findings and clinical features strongly suggest a diagnosis of CMV encephalitis, so acyclovir may not be necessary.

Specific viruses and the drugs used against them are:[94]

- HSV-1 and HSV-2: acyclovir.
- Varicella-zoster virus (VZV): acyclovir.
- CMV: ganciclovir plus foscarnet.
- Epstein-Barr virus (EBV): acyclovir is first line in suspected viral encephalitis, but once the diagnosis of EBV is confirmed, ganciclovir or cidofovir is a possible alternative.
- Herpes B virus: ganciclovir or acyclovir (intravenous therapy may be preferable over oral therapy). For post-exposure prophylaxis, valacyclovir is the preferred agent.
- Human herpes 6: ganciclovir or foscarnet should be used in immunocompromised patients. However, use of these agents in immunocompetent patients can also be considered, but there are no good data on their effectiveness.

Corticosteroids

The role of corticosteroids in viral encephalitis to reduce the inflammation associated with infection is an ongoing area of study.[95] To date, there is limited data regarding the benefit of adjuvant corticosteroids for the treatment of viral encephalitis and guidelines do not support their routine use.[13][47] [96] One meta-analysis (n=281 patients with viral encephalitis; 120 received corticosteroids) did not find benefit of corticosteroid treatment on survival.[97] Results from a multicenter randomized controlled trial in HSV encephalitis are currently awaited.[98]

High-dose intravenous corticosteroids are considered as first-line therapy for acute disseminated encephalomyelitis (ADEM).[18] High-dose corticosteroids are also recommended for autoimmune encephalitis once infection is ruled out based on basic CSF results (e.g., number of cells) and if biopsy for primary CNS lymphoma or neurosarcoidosis is not a consideration. In these patients, immunotherapy with high dose corticosteroids is recommended.[39] The duration of corticosteroid therapy should be short (3-7 days) to minimize adverse effects (e.g., gastrointestinal bleeds, predisposition to secondary bacterial infections, neuropsychiatric disturbance).[39] Corticosteroids should not be prescribed before consultation with specialists.

Surgical intervention

Monitoring devices such as catheters or bolts may be placed to measure ICP. Shunting or surgical decompression (by craniectomy) is indicated in some cases where medical management (corticosteroids, mannitol) has failed to control elevated ICP, and for impending uncal herniation.[99] This can be considered no matter the etiology of encephalitis; however, most outcome data have been published for viral encephalitis. In some cases of HSV encephalitis, surgical decompression has been shown to improve outcome.[100]

Therapy for nonviral etiologies

If the clinical picture and initial tests suggest a nonviral infective encephalitis (bacterial, fungal, parasitic) appropriate antimicrobial therapy is started.

When the initial evaluation does not support an infectious cause and an autoimmune cause is suspected, aggressive immunotherapy with intravenous corticosteroids, immune globulin, or plasma exchange

should be considered.[1] [101] The decision to fight infection or suppress the immune system needs to be balanced in each case.

Blood-borne infections can rarely be transmitted by immune globulin. Immunoglobulin (Ig)A-deficient patients are at risk of allergic reactions (this is less of a problem, as technology used to prepare immune globulin ensures removal of most IgA). Plasma exchange is performed by placing a double-lumen catheter in a central vein, and mechanically filtering and replacing the patient's plasma with pooled donor plasma. This is done in consultation with a hematologist.

Cases with persistent altered mental status not responsive to first-line therapy should be treated with rituximab and/or cyclophosphamide.[31][50] [51] [102] [103] In most newly diagnosed cases, it is difficult to determine clinically whether autoimmune encephalitis is antibody or cell-mediated before the antibody results are available.[104] Some clinical clues may help the clinician come to a preliminary hypothesis regarding etiology (e.g., leucine-rich glioma-inactivated 1 antibodies are associated with faciobrachial dystonic seizures, such as rapid jerks of the face and/or ipsilateral arm and shoulder, while patients with known or increased cancer risk are more likely to have cell-mediated autoimmune encephalitis).[39] Based on these clues, clinicians may decide to use rituximab or cyclophosphamide as a second-line agent if antibody results are delayed, or if there is no access to antibody testing.[39] Rituximab is now generally preferred over cyclophosphamide if monotherapy is used in highly suspected antibody-mediated autoimmunity (e.g., N-methyl-D-aspartate receptor-antibody encephalitis).[105] Rituximab is less toxic than cyclophosphamide.[39] [106] Cyclophosphamide may be considered if rituximab is contraindicated or not available in these cases.[105] Some patients may be treated with a combination of rituximab and cyclophosphamide.[104] Cyclophosphamide can be considered in known or highly suspected cell-mediated autoimmunity (e.g., classical paraneoplastic syndrome) since rituximab may not be as effective for cell-mediated inflammation.[39] Some patients may be treated with a combination of cyclophosphamide and rituximab.[104]

Management of autoimmune encephalitis associated with malignancy (i.e., paraneoplastic encephalitis) involves diagnostic testing and treatment of the underlying tumor. However, in order to avoid the risk of permanent sequelae, treatment directed toward the paraneoplastic syndrome should not be delayed by a failure to identify the underlying tumor. Oophorectomy is indicated as an acute treatment if ovarian teratomas are present. Tumor resection is associated with faster rate of recovery and reduced relapse rate.[31] [107]

High-dose corticosteroids are advocated by experts for patients with acute disseminated encephalomyelitis.[108] [109] In cases where corticosteroids fail to show benefit, plasma exchange or immune globulin can be considered.[108]

Rehabilitation

The results of one systematic review suggested that rehabilitative interventions, including cognitive therapy, behavioral therapy, and physical therapy, may help to improve functionality in children and adults after infectious encephalitis. However, most of the included studies were observational in nature.[110]

One retrospective study based on 8 patients noted that, although patients with encephalitis can make some functional gains with acute rehabilitation therapy, the rate of recovery varies and is generally less than that of stroke and traumatic brain injury.[111] The most frequently used nonpharmacological treatments to treat dementia and apathy following encephalitis are music therapy and cognitive rehabilitation.[112]

Treatment algorithm overview

Please note that formulations/routes and doses may differ between drug names and brands, drug formularies, or locations. Treatment recommendations are specific to patient groups: [see disclaimer](#)

Initial (summary)		
immunocompetent host: suspected viral etiology		
	1st	acyclovir
	plus	supportive care
immunocompromised host: suspected viral etiology		
	1st	combination antiviral therapy
	plus	supportive care

Acute (summary)		
confirmed herpes simplex virus (HSV) encephalitis		
	1st	acyclovir
	plus	supportive care
confirmed varicella zoster virus (VZV) encephalitis		
	1st	acyclovir
	plus	supportive care
confirmed cytomegalovirus (CMV) encephalitis		
	1st	ganciclovir plus foscarnet
	plus	supportive care
confirmed Epstein-Barr virus (EBV) encephalitis		
	1st	acyclovir, ganciclovir, or cidofovir
	plus	supportive care
confirmed herpes B encephalitis		
	1st	ganciclovir, acyclovir, or valacyclovir
	plus	supportive care
confirmed human herpes 6 encephalitis		
	1st	ganciclovir or foscarnet
	plus	supportive care
confirmed nonherpes virus etiology		
	1st	supportive care ± antiviral therapy
nonviral etiology		
	1st	supportive care + treatment of underlying etiology
■ autoimmune/paraneoplastic encephalitis	plus	immune-modulating therapy
	adjunct	treatment of underlying malignancy
■ acute disseminated encephalomyelitis	plus	immune-modulating therapy
■ confirmed syphilis encephalitis	plus	targeted antimicrobial treatment

Acute (summary)			
	■ confirmed listeria encephalitis	plus	targeted antimicrobial treatment
	■ confirmed Mycoplasma pneumoniae encephalitis	plus	targeted antimicrobial treatment
		adjunct	immune-modulating therapy
	■ confirmed Rocky Mountain spotted fever encephalitis	plus	targeted antimicrobial treatment

Ongoing (summary)		
convalescent phase: all etiologies		
	1st	rehabilitation

Treatment algorithm

Please note that formulations/routes and doses may differ between drug names and brands, drug formularies, or locations. Treatment recommendations are specific to patient groups: [see disclaimer](#)

Initial

immunocompetent host: suspected viral etiology

1st acyclovir

Primary options

» **acyclovir**: 10 mg/kg intravenously every 8 hours for 10-21 days

» All cases of suspected community-acquired viral encephalitis are started empirically on acyclovir until the cause is determined.^[13] As most cases of sporadic viral encephalitis are secondary to herpes simplex virus, this is good clinical practice supported by biopsy-proven randomized controlled trials, and it reduces mortality.^{[47] [92]}

plus supportive care

Treatment recommended for ALL patients in selected patient group

» All suspected cases of encephalitis should be admitted and fully evaluated. Some patients with milder symptoms and signs can be managed in a regular nursing unit, with access to an intensive care unit (ICU) bed if needed. All other patients, and in particular those with complications (e.g., significant electrolyte abnormalities, strokes, elevated intracranial pressure [ICP], cerebral edema, coma, seizures activity, or status epilepticus) should be managed in an ICU, preferably a neurointensive care unit.^{[33] [83]}

» Supportive care may include endotracheal intubation and mechanical ventilation, circulatory and electrolyte support, prevention and management of secondary bacterial infections, deep venous thrombosis prophylaxis, and gastrointestinal (ulcer) prophylaxis. Antiretroviral therapy is an important treatment in all cases of HIV-associated encephalitis (whether due to HIV itself or to an opportunistic infection); in CD8 encephalitis, patients respond well to corticosteroids.^{[84] [85]} For certain opportunistic infections, such as cryptococcus, antiretroviral therapy should be delayed based on World Health Organization guidelines.^{[86] [87] [88]}

Initial

» In patients with elevated ICP, initial measures are elevation of head of bed to 30° to 45°, avoiding compression of the jugular veins, and brief episodes of hyperventilation.[89]

Subsequently, hyperosmolar therapy with mannitol boluses or hypertonic saline can be used to decrease ICP.[90]

» Shunting or surgical decompression (by craniectomy) is indicated in some cases where medical management has failed to control elevated ICP, and for impending uncal herniation.[99] This can be considered no matter the etiology of encephalitis; however, most outcome data have been published for viral encephalitis.

**immunocompromised host:
suspected viral etiology**
1st combination antiviral therapy
Primary options

» **ganciclovir**: 5 mg/kg intravenously every 12 hours for 14-21 days

-and-

» **foscarnet**: 60 mg/kg intravenously every 8 hours; or 90 mg/kg intravenously every 12 hours for 14-21 days

-and-

» **acyclovir**: 10 mg/kg intravenously every 8 hours for 21 days

» If cytomegalovirus (CMV) encephalitis is suspected in an immunocompromised patient, ganciclovir and foscarnet are given with acyclovir until herpes simplex virus (HSV) polymerase chain reaction (PCR) is available.

» Ganciclovir and foscarnet are given for 14 to 21 days unless nephrotoxicity or myelotoxicity occurs in which case one of the agents should be stopped.[113]

» Acyclovir is given until HSV infection can be excluded (HSV PCR). In some cases, magnetic resonance imaging findings and clinical features strongly suggest a diagnosis of CMV encephalitis, so acyclovir may not be necessary. If a diagnosis of CMV infection is established, then acyclovir should be discontinued as it is not effective against this virus.

plus supportive care

Treatment recommended for ALL patients in selected patient group

Initial

» All suspected cases of encephalitis should be admitted and fully evaluated. Some patients with milder symptoms and signs can be managed in a regular nursing unit, with access to an intensive care unit (ICU) bed if needed. All other patients, and in particular those with complications (e.g., significant electrolyte abnormalities, strokes, elevated intracranial pressure [ICP], cerebral edema, coma, seizures activity, or status epilepticus) should be managed in an ICU, preferably a neurointensive care unit.[33] [83]

» Supportive care may include endotracheal intubation and mechanical ventilation, circulatory and electrolyte support, prevention and management of secondary bacterial infections, deep venous thrombosis prophylaxis, and gastrointestinal (ulcer) prophylaxis. Antiretroviral therapy is an important treatment in all cases of HIV-associated encephalitis (whether due to HIV itself or to an opportunistic infection); in CD8 encephalitis, patients respond well to corticosteroids.[84] [85] For certain opportunistic infections, such as cryptococcus, antiretroviral therapy should be delayed based on World Health Organization guidelines.[86] [87] [88]

» In patients with elevated ICP, initial measures are elevation of head of bed to 30° to 45°, avoiding compression of the jugular veins, and brief episodes of hyperventilation.[89] Subsequently, hyperosmolar therapy with mannitol boluses or hypertonic saline can be used to decrease ICP.[90]

» Shunting or surgical decompression (by craniectomy) is indicated in some cases where medical management has failed to control elevated ICP, and for impending uncal herniation.[99] This can be considered no matter the etiology of encephalitis; however, most outcome data have been published for viral encephalitis.

Acute

confirmed herpes simplex virus (HSV) encephalitis

1st **acyclovir****Primary options**» **acyclovir**: 10 mg/kg intravenously every 8 hours for 14-21 days

» Confirmed HSV encephalitis should be treated with acyclovir.[13] This is supported by biopsy-proven randomized controlled trials, showing reduced mortality.[47] [92]

» Immunosuppressed patients should receive a full 21 days of treatment.

» The clinician should consider repeating the lumbar puncture at day 12 to 13 with repeat polymerase chain reaction to guide the decision of whether to stop the treatment or to continue up to 21 days.

plus **supportive care**

Treatment recommended for ALL patients in selected patient group

» All cases of encephalitis should be admitted and fully evaluated. Some patients with milder symptoms and signs can be managed in a regular nursing unit, with access to an intensive care unit (ICU) bed if needed. All other patients, and in particular those with complications (e.g., significant electrolyte abnormalities, strokes, elevated intracranial pressure [ICP], cerebral edema, coma, seizures activity, or status epilepticus) should be managed in an ICU, preferably a neurointensive care unit.[33] [83]

» Supportive care may include endotracheal intubation and mechanical ventilation, circulatory and electrolyte support, prevention and management of secondary bacterial infections, deep venous thrombosis prophylaxis, and gastrointestinal (ulcer) prophylaxis. Antiretroviral therapy is an important treatment in all cases of HIV-associated encephalitis (whether due to HIV itself or to an opportunistic infection); in CD8 encephalitis, patients respond well to corticosteroids.[84] [85] For certain opportunistic infections, such as cryptococcus, antiretroviral therapy should be delayed based on World Health Organization guidelines.[86] [87] [88]

» In patients with elevated ICP, initial measures are elevation of head of bed to 30° to 45°, avoiding compression of the jugular veins,

Acute

and brief episodes of hyperventilation.[89]
Subsequently, hyperosmolar therapy with mannitol boluses or hypertonic saline can be used to decrease ICP.[90]

» Shunting or surgical decompression (by craniectomy) is indicated in some cases where medical management (corticosteroids, mannitol) has failed to control elevated ICP, and for impending uncal herniation.[99] In some cases of HSV encephalitis, surgical decompression has been shown to improve outcome.[100]

» To date, there is limited data regarding the benefit of adjuvant corticosteroids for the treatment of viral encephalitis (in the absence of elevated ICP) and guidelines do not support their routine use.[13] [47] [96]

confirmed varicella zoster virus (VZV) encephalitis

1st acyclovir

Primary options

» acyclovir: 10 mg/kg intravenously every 8 hours for 14 days

» Confirmed VZV encephalitis should be treated with acyclovir.[114]

plus supportive care

Treatment recommended for ALL patients in selected patient group

» All cases of encephalitis should be admitted and fully evaluated. Some patients with milder symptoms and signs can be managed in a regular nursing unit, with access to an intensive care unit (ICU) bed if needed. All other patients, and in particular those with complications (e.g., significant electrolyte abnormalities, strokes, elevated intracranial pressure [ICP], cerebral edema, coma, seizures activity, or status epilepticus) should be managed in an ICU, preferably a neurointensive care unit.[33] [83]

» Supportive care may include endotracheal intubation and mechanical ventilation, circulatory and electrolyte support, prevention and management of secondary bacterial infections, deep venous thrombosis prophylaxis, and gastrointestinal (ulcer) prophylaxis. Antiretroviral therapy is an important treatment in all cases of HIV-associated encephalitis (whether due to HIV itself or to an opportunistic infection); in CD8 encephalitis, patients respond well to corticosteroids.[84] [85] For certain opportunistic

Acute

infections, such as cryptococcus, antiretroviral therapy should be delayed based on World Health Organization guidelines.[86] [87] [88]

» In patients with elevated ICP, initial measures are elevation of head of bed to 30° to 45°, avoiding compression of the jugular veins, and brief episodes of hyperventilation.[89]

Subsequently, hyperosmolar therapy with mannitol boluses or hypertonic saline can be used to decrease ICP.[90]

» Shunting or surgical decompression (by craniectomy) is indicated in some cases where medical management (corticosteroids, mannitol) has failed to control elevated ICP, and for impending uncal herniation.[99]

» To date, there is limited data regarding the benefit of adjuvant corticosteroids for the treatment of viral encephalitis (in the absence of elevated ICP) and guidelines do not support their routine use.[13] [47] [96]

confirmed cytomegalovirus (CMV) encephalitis

1st ganciclovir plus foscarnet

Primary options

» **ganciclovir**: 5 mg/kg intravenously every 12 hours for 14-21 days initially, followed by a maintenance dose of 5 mg/kg/day given once daily for 7 days/week or 6 mg/kg/day given once daily for 5 days/week

-and-

» **foscarnet**: 60 mg/kg intravenously every 8 hours; or 90 mg/kg intravenously every 12 hours for 14-21 days

» Confirmed CMV encephalitis should be treated with ganciclovir plus foscarnet.[114]

plus supportive care

Treatment recommended for ALL patients in selected patient group

» All cases of encephalitis should be admitted and fully evaluated. Some patients with milder symptoms and signs can be managed in a regular nursing unit, with access to an intensive care unit (ICU) bed if needed. All other patients, and in particular those with complications (e.g., significant electrolyte abnormalities, strokes, elevated intracranial pressure [ICP], cerebral edema, coma, seizures activity, or status epilepticus) should be managed in an ICU, preferably a neurointensive care unit.[33] [83]

Acute

» Supportive care may include endotracheal intubation and mechanical ventilation, circulatory and electrolyte support, prevention and management of secondary bacterial infections, deep venous thrombosis prophylaxis, and gastrointestinal (ulcer) prophylaxis. Antiretroviral therapy is an important treatment in all cases of HIV-associated encephalitis (whether due to HIV itself or to an opportunistic infection); in CD8 encephalitis, patients respond well to corticosteroids.[84] [89] For certain opportunistic infections, such as cryptococcus, antiretroviral therapy should be delayed based on World Health Organization guidelines.[86] [87] [88]

» In patients with elevated ICP, initial measures are elevation of head of bed to 30° to 45°, avoiding compression of the jugular veins, and brief episodes of hyperventilation.[89]

Subsequently, hyperosmolar therapy with mannitol boluses or hypertonic saline can be used to decrease ICP.[90]

» Shunting or surgical decompression (by craniectomy) is indicated in some cases where medical management (corticosteroids, mannitol) has failed to control elevated ICP, and for impending uncal herniation.[99]

confirmed Epstein-Barr virus (EBV) encephalitis

1st acyclovir, ganciclovir, or cidofovir

Primary options

» **acyclovir**: 10 mg/kg intravenously every 8 hours for 14 days

OR

» **ganciclovir**: consult specialist for guidance on dose

Secondary options

» **cidofovir**: consult specialist for guidance on dose

» Acyclovir is first line in suspected viral encephalitis, but once the diagnosis of EBV is confirmed, ganciclovir or cidofovir are possible alternatives.[94] There are limited data to guide therapy of EBV central nervous system infections. No controlled studies have been conducted. There are case reports that suggest ganciclovir improves outcomes.

plus supportive care

Acute

Treatment recommended for ALL patients in selected patient group

» All cases of encephalitis should be admitted and fully evaluated. Some patients with milder symptoms and signs can be managed in a regular nursing unit, with access to an intensive care unit (ICU) bed if needed. All other patients, and in particular those with complications (e.g., significant electrolyte abnormalities, strokes, elevated intracranial pressure [ICP], cerebral edema, coma, seizures activity, or status epilepticus) should be managed in an ICU, preferably a neurointensive care unit.[33] [83]

» Supportive care may include endotracheal intubation and mechanical ventilation, circulatory and electrolyte support, prevention and management of secondary bacterial infections, deep venous thrombosis prophylaxis, and gastrointestinal (ulcer) prophylaxis. Immune globulin can be used for agammaglobulinemic patients and neonates with sepsis syndrome.[74] Antiretroviral therapy is an important treatment in all cases of HIV-associated encephalitis (whether due to HIV itself or to an opportunistic infection); in CD8 encephalitis, patients respond well to corticosteroids.[84] [85] For certain opportunistic infections, such as cryptococcus, antiretroviral therapy should be delayed based on World Health Organization guidelines.[86] [87] [88]

» In patients with elevated ICP, initial measures are elevation of head of bed to 30° to 45°, avoiding compression of the jugular veins, and brief episodes of hyperventilation.[89] Subsequently, hyperosmolar therapy with mannitol boluses or hypertonic saline can be used to decrease ICP.[90]

» Shunting or surgical decompression (by craniectomy) is indicated in some cases where medical management (corticosteroids, mannitol) has failed to control elevated ICP, and for impending uncal herniation.[99] In some cases of herpes simplex virus encephalitis, surgical decompression has been shown to improve outcome.

» To date, there is limited data regarding the benefit of adjuvant corticosteroids for the treatment of viral encephalitis (in the absence of elevated ICP) and guidelines do not support their routine use.[13] [47] [96]

confirmed herpes B encephalitis

Acute

1st ganciclovir, acyclovir, or valacyclovir**Primary options**

» **ganciclovir**: 5 mg/kg intravenously every 12 hours for 14-21 days

Secondary options

» **acyclovir**: 10 mg/kg intravenously every 8 hours for 14-21 days

OR

» **valacyclovir**: 1 g orally every 8 hours for 14 days

» Intravenous therapy may be preferable in acute central nervous system (CNS) disease. However, the efficacy of the intravenous approach has not been studied. Ganciclovir may be preferable as a first option in CNS disease.[94] Duration of treatment should be decided in conjunction with an infectious disease specialist.

» There is also expert opinion that life-long suppression of latent infection with valacyclovir may be considered.[94]

plus supportive care

Treatment recommended for ALL patients in selected patient group

» All cases of encephalitis should be admitted and fully evaluated. Some patients with milder symptoms and signs can be managed in a regular nursing unit, with access to an intensive care unit (ICU) bed if needed. All other patients, and in particular those with complications (e.g., significant electrolyte abnormalities, strokes, elevated intracranial pressure [ICP], cerebral edema, coma, seizures activity, or status epilepticus) should be managed in an ICU, preferably a neurointensive care unit.[33] [83]

» Supportive care may include endotracheal intubation and mechanical ventilation, circulatory and electrolyte support, prevention and management of secondary bacterial infections, deep venous thrombosis prophylaxis, and gastrointestinal (ulcer) prophylaxis. Antiretroviral therapy is an important treatment in all cases of HIV-associated encephalitis (whether due to HIV itself or to an opportunistic infection); in CD8 encephalitis, patients respond well to corticosteroids.[84] [85] For certain opportunistic infections, such as cryptococcus, antiretroviral

Acute

therapy should be delayed based on World Health Organization guidelines.[\[86\]](#) [\[87\]](#) [\[88\]](#)

» In patients with elevated ICP, initial measures are elevation of head of bed to 30° to 45°, avoiding compression of the jugular veins, and brief episodes of hyperventilation.[\[89\]](#)

Subsequently, hyperosmolar therapy with mannitol boluses or hypertonic saline can be used to decrease ICP.[\[90\]](#)

» Shunting or surgical decompression (by craniectomy) is indicated in some cases where medical management (corticosteroids, mannitol) has failed to control elevated ICP, and for impending uncal herniation.[\[99\]](#)

confirmed human herpes 6 encephalitis

1st ganciclovir or foscarnet

Primary options

» [ganciclovir](#): 5 mg/kg intravenously every 12 hours for 14-21 days

OR

» [foscarnet](#): 60 mg/kg intravenously every 8 hours; or 90 mg/kg intravenously every 12 hours for 14-21 days

» Ganciclovir or foscarnet should be used in immunocompromised patients.[\[114\]](#)

» Use of these agents in immunocompetent patients can also be considered, but there are no good data on their effectiveness.[\[114\]](#)

plus supportive care

Treatment recommended for ALL patients in selected patient group

» All cases of encephalitis should be admitted and fully evaluated. Some patients with milder symptoms and signs can be managed in a regular nursing unit, with access to an intensive care unit (ICU) bed if needed. All other patients, and in particular those with complications (e.g., significant electrolyte abnormalities, strokes, elevated intracranial pressure [ICP], cerebral edema, coma, seizures activity, or status epilepticus) should be managed in an ICU, preferably a neurointensive care unit.[\[33\]](#) [\[83\]](#)

» Supportive care may include endotracheal intubation and mechanical ventilation, circulatory and electrolyte support, prevention and

Acute

management of secondary bacterial infections, deep venous thrombosis prophylaxis, and gastrointestinal (ulcer) prophylaxis. Antiretroviral therapy is an important treatment in all cases of HIV-associated encephalitis (whether due to HIV itself or to an opportunistic infection); in CD8 encephalitis, patients respond well to corticosteroids.[84] [85] For certain opportunistic infections, such as cryptococcus, antiretroviral therapy should be delayed based on WHO guidelines.[86] [87] [88]

» In patients with elevated ICP, initial measures are elevation of head of bed to 30° to 45°, avoiding compression of the jugular veins, and brief episodes of hyperventilation.[89] Subsequently, hyperosmolar therapy with mannitol boluses or hypertonic saline can be used to decrease ICP.[90]

» Shunting or surgical decompression (by craniectomy) is indicated in some cases where medical management (corticosteroids, mannitol) has failed to control elevated ICP, and for impending uncal herniation.[99]

confirmed nonherpes virus etiology

1st supportive care ± antiviral therapy

» For cases where a specific virus has been isolated and specific antiviral treatment is available, treatment is directed toward the underlying isolated virus.

» All cases of encephalitis should be admitted and fully evaluated. Some patients with milder symptoms and signs can be managed in a regular nursing unit, with access to an intensive care unit (ICU) bed if needed. All other patients, and in particular those with complications (e.g., significant electrolyte abnormalities, strokes, elevated intracranial pressure [ICP], cerebral edema, coma, seizures activity, or status epilepticus) should be managed in an ICU, preferably a neurointensive care unit.[33] [83]

» Supportive care may include endotracheal intubation and mechanical ventilation, circulatory and electrolyte support, prevention and management of secondary bacterial infections, deep venous thrombosis prophylaxis, and gastrointestinal (ulcer) prophylaxis. Antiretroviral therapy is an important treatment in all cases of HIV-associated encephalitis (whether due to HIV itself or to an opportunistic infection); in CD8 encephalitis, patients respond well to corticosteroids.[84] [85] For certain opportunistic

Acute

infections, such as cryptococcus, antiretroviral therapy should be delayed based on World Health Organization guidelines.[\[86\]](#) [\[87\]](#) [\[88\]](#)

» In patients with elevated ICP, initial measures are elevation of head of bed to 30° to 45°, avoiding compression of the jugular veins, and brief episodes of hyperventilation.[\[89\]](#)

Subsequently, hyperosmolar therapy with mannitol boluses or hypertonic saline can be used to decrease ICP.[\[90\]](#)

» Shunting or surgical decompression (by craniectomy) is indicated in some cases where medical management (corticosteroids, mannitol) has failed to control elevated ICP, and for impending uncal herniation.[\[99\]](#)

nonviral etiology

nonviral etiology

1st

supportive care + treatment of underlying etiology

» Etiology is often unknown, and therefore no specific treatment options exist for the majority of cases. However, for cases where a diagnosis is reasonably certain, treatment is directed toward the underlying offending agent, with appropriate anti-infective measures in bacterial, fungal, or parasitic infections. If cerebrospinal fluid studies do not show a clear infectious etiology, immunotherapy should be considered.[\[102\]](#) [\[103\]](#) The decision to fight infection or suppress the immune system needs to be balanced in each case.

» All cases of encephalitis should be admitted and fully evaluated. Some patients with milder symptoms and signs can be managed in a regular nursing unit, with access to an intensive care unit (ICU) bed if needed. All other patients, and in particular those with complications (e.g., significant electrolyte abnormalities, strokes, elevated intracranial pressure [ICP], cerebral edema, coma, seizures activity, or status epilepticus) should be managed in an ICU, preferably a neurointensive care unit.[\[33\]](#) [\[83\]](#)

» Supportive care is the cornerstone of treatment in most cases. This may include endotracheal intubation and mechanical ventilation, circulatory and electrolyte support, prevention and management of secondary bacterial infections, deep venous thrombosis prophylaxis, and gastrointestinal (ulcer) prophylaxis.

» In patients with elevated ICP, initial measures are elevation of head of bed to 30° to 45°,

Acute

■ autoimmune/
paraneoplastic
encephalitis

plus

avoiding compression of the jugular veins, and brief episodes of hyperventilation.[89]

Subsequently, hyperosmolar therapy with mannitol boluses or hypertonic saline can be used to decrease ICP.[90]

» Shunting or surgical decompression (by craniectomy) is indicated in some cases where medical management has failed to control elevated ICP, and for impending uncal herniation.[99] This can be considered no matter the etiology of encephalitis; however, most outcome data have been published for viral encephalitis.

immune-modulating therapy

Treatment recommended for ALL patients in selected patient group

Primary options

» **methylprednisolone sodium succinate**: 1000 mg intravenously once daily for 3-5 days

OR

» **immune globulin (human)**: 2 g/kg intravenously given in divided doses over 4-5 days

Secondary options

» **rituximab**: consult specialist for guidance on dose

-and/or-

» **cyclophosphamide**: consult specialist for guidance on dose

» When the initial evaluation does not support an infectious cause and an autoimmune cause is suspected, aggressive immunotherapy with intravenous corticosteroids, immune globulin, or plasma exchange should be considered.[1][101] Cases with persistent altered mental status not responsive to first-line therapy should be treated with rituximab and/or cyclophosphamide.[31][50][51][102][103]

» In most newly diagnosed cases, it is difficult to determine clinically whether autoimmune encephalitis is antibody or cell-mediated before the antibody results are available.[104] Some clinical clues may help the clinician come to a preliminary hypothesis regarding etiology (e.g., leucine-rich glioma-inactivated 1 antibodies are associated with faciobrachial dystonic seizures, such as rapid jerks of the face and/or ipsilateral arm and shoulder, while

Acute

patients with known or increased cancer risk are more likely to have cell-mediated autoimmune encephalitis).[39] Based on these clues, clinicians may decide to use rituximab or cyclophosphamide as a second-line agent if antibody results are delayed, or if there is no access to antibody testing.[39]

» Rituximab is now generally preferred over cyclophosphamide if monotherapy is used in highly suspected antibody-mediated autoimmunity (e.g., N-methyl-D-aspartate receptor-antibody encephalitis).[105] Rituximab is less toxic than cyclophosphamide.[39] [106] Cyclophosphamide may be considered if rituximab is contraindicated or not available in these cases.[105] Some patients may be treated with a combination of rituximab and cyclophosphamide.[104]

» Cyclophosphamide can be considered in known, or highly suspected, cell-mediated autoimmunity (e.g., classical paraneoplastic syndrome), since rituximab may not be as effective for cell-mediated inflammation.[39] Some patients may be treated with a combination of cyclophosphamide and rituximab.[104]

adjunct treatment of underlying malignancy

Treatment recommended for SOME patients in selected patient group

» Management of autoimmune encephalitis associated with malignancy (paraneoplastic encephalitis) involves diagnostic testing and treatment of the underlying tumor. However, treatment directed toward the paraneoplastic syndrome should not be delayed by failure to identify the underlying tumor, as there is a risk for development of permanent sequelae.

» Oophorectomy is indicated as an acute treatment if ovarian teratomas are present.[8] Tumor resection is associated with a faster rate of recovery and reduced relapse rate.[31] [107]

..... ■ **acute disseminated encephalomyelitis**

plus**immune-modulating therapy**

Treatment recommended for ALL patients in selected patient group

Primary options

» **methylprednisolone sodium succinate**: 1000 mg intravenously once daily for 3-5 days

Secondary options

Acute

			<p>» immune globulin (human): 2 g/kg intravenously given in divided doses over 4-5 days</p> <p>» High-dose corticosteroids are advocated by experts.[108] [109]</p> <p>» In cases where corticosteroids fail to show benefit, plasma exchange or immune globulin can be considered.[108] Plasma exchange is performed in consultation with a hematologist. Immune globulin has been shown to reduce duration of the illness.</p>
■ confirmed syphilis encephalitis	plus	targeted antimicrobial treatment	<p>Treatment recommended for ALL patients in selected patient group</p> <p>» The microbiology laboratory should be alerted if unusual organisms are suspected (e.g., <i>Treponema pallidum</i>), for which special microbiologic procedures are necessary. Neurosyphilis presenting with features of encephalitis is a rare form of central nervous system infection by <i>Treponema pallidum</i>. [115] [116] Targeted therapy is available if isolated. Consult a specialist for guidance on further management. See Syphilis infection .</p>
■ confirmed listeria encephalitis	plus	targeted antimicrobial treatment	<p>Treatment recommended for ALL patients in selected patient group</p> <p>» The microbiology laboratory should be alerted if unusual organisms are suspected (e.g., <i>Listeria</i>), for which special microbiological procedures are necessary. <i>Listeria</i> encephalitis is rare but carries a high mortality rate.[117]</p> <p>While <i>listeria</i> meningitis is more common, patients with high risk factors may also develop meningoencephalitis. Targeted therapy is available if isolated. Consult a specialist for guidance on further management. See Listeriosis .</p>
■ confirmed <i>Mycoplasma pneumoniae</i> encephalitis	plus	targeted antimicrobial treatment	<p>Treatment recommended for ALL patients in selected patient group</p> <p>» The microbiology laboratory should be alerted if unusual organisms are suspected (e.g., <i>Mycoplasma</i> species), for which special microbiologic procedures are necessary. <i>M pneumoniae</i> is commonly attributed to upper and lower respiratory tract infections in pediatric patients and central nervous system symptoms may reflect extrapulmonary infections or postinfectious encephalitis.[118] Targeted</p>

Acute

■ confirmed Rocky Mountain spotted fever encephalitis

adjunct

therapy is available if isolated. Consult a specialist for guidance on further management.

immune-modulating therapy

Treatment recommended for SOME patients in selected patient group

Primary options

» **methylprednisolone sodium succinate**: 1000 mg intravenously once daily for 3-5 days

OR

» **immune globulin (human)**: 2 g/kg intravenously given in divided doses over 4-5 days

» Immunomodulatory treatments have been hypothesized to benefit these patients based on the proposed antibody response to the pathogen. Immunotherapy with intravenous corticosteroids, immune globulin, or plasma exchange is typically considered as a first-line option.

» Case reports suggest possible benefit.

» Plasma exchange is performed in consultation with a hematologist.

plus

targeted antimicrobial treatment

Treatment recommended for ALL patients in selected patient group

» The microbiology laboratory should be alerted if unusual organisms are suspected (e.g., *Rickettsia rickettsii*), for which special microbiologic procedures are necessary. Neurologic involvement including encephalitis in patients with Rocky Mountain spotted fever is associated with higher mortality rates.^[119]

Targeted therapy is available if isolated. Consult a specialist for guidance on further management. See Rocky Mountain spotted fever .

Ongoing

convalescent phase: all etiologies

1st

rehabilitation

- » Starts once the acute, life-threatening phase has passed. It can begin with the initial evaluation during acute hospitalization by the rehabilitation medicine personnel and be continued in various in- or outpatient settings.
- » The need for rehabilitation is varied and depends on the functional deficits present in the individual patient. It can include cognitive/behavioral rehabilitation and motor/ambulatory rehabilitation.[\[110\]](#)
- » The most frequently used nonpharmacological treatments to treat dementia and apathy following encephalitis are music therapy and cognitive rehabilitation.[\[112\]](#)

Emerging

Intravenous immune globulin for viral encephalitis

One Cochrane review suggested a clinical benefit of adjunctive intravenous immune globulin treatment for children with viral encephalitis for some measures (i.e., mean length of hospital stay, time to stop spasms, time to regain consciousness, and time to resolution of neuropathic symptoms and fever). However, the quality of evidence in the included studies was very low.[120] Immune globulin with high titer to West Nile virus has been proposed as a potential treatment for severe West Nile virus infections but data have so far been inconclusive.[121] [122]

Neuraminidase inhibitors

Neuraminidase inhibitors may be considered if the influenza virus is the suspected etiologic agent. According to the Centers for Disease Control and Prevention and the American Academy of Pediatrics recommendations, oral oseltamivir, inhaled zanamivir, and intravenous peramivir should be used for the treatment of acute uncomplicated influenza within 2 days of illness onset; oral oseltamivir and inhaled zanamivir can also be used for chemoprophylaxis.[123] [CDC: Influenza (Flu)] (<https://www.cdc.gov/flu/professionals/index.htm>)

Primary prevention

Vaccines are available for mumps, measles, rubella, varicella zoster virus, and poliovirus (universal immunization); rabies; Japanese encephalitis (in the appropriate geographic and clinical setting); tuberculosis (Bacille Calmette-Guerin); and various bacteria (*Pneumococcus* and *Meningococcus*).

Tick-borne encephalitis

Four inactivated vaccines for tick-borne encephalitis (TBE) have been tested in clinical trials and shown to be safe and effective: FSME-Immun® (TicoVac®) and Encepur® are licensed in many European countries, and TBE-Moscow® and EnceVir® are licensed in Russia and some neighboring countries.[40] Where the disease is highly endemic, the World Health Organization recommends that vaccination be offered to all age groups, including children.[41]

The Food and Drug Administration approved TicoVac® in August 2021 to prevent TBE in people ages 1 year and older.[42] The Advisory Committee on Immunization Practices (ACIP) recommends TBE vaccination in people who are moving or traveling to an endemic area, and are likely have a high level of exposure to ticks. Vaccination may be considered when the risk of exposure is lower, based on individual factors including medical history and risk tolerance.[43]

Japanese encephalitis

Four types of vaccines for Japanese encephalitis (JE) exist. Most vaccines are cell-culture based. In the US only one vaccine is available, the Vero cell-derived, inactivated, and alum-adsorbed Japanese encephalitis vaccine based on SA-14-14-2 strain (JE-VC).[44] This is also available in Australia and various European countries. Two different Vero cell-derived inactivated vaccines are available in Japan. Both of these are based on the Beijing-1 strain. A live attenuated vaccine also based on the SA 14-14-2 strain is commonly used in China and other East Asian and Southeast Asian countries. Lastly, a live, attenuated, Japanese encephalitis-yellow fever chimeric vaccine is now available in Australia and Thailand. Different vaccines have different recommended schedules based on seroconversion rates and individual studies for specific vaccines. For some of the newer vaccines, booster schedules may not have been determined yet.

Most travelers to JE-endemic countries are at very low risk of the disease, but some will be at increased risk depending on factors such as longer periods of travel, transmission season, and spending time in rural areas.[44] Vaccination is recommended for travelers to JE-endemic countries who plan to spend one month or longer in an endemic area or are frequent travelers to the areas. Vaccination should also be considered for travelers to an endemic area during the transmission season with a shorter than one-month stay if they plan to visit nonurban areas and their activities may increase the risk of disease transmission (e.g., spending

substantial time outdoors, especially during the night, or staying in accommodation lacking screens, bed nets, or air-conditioning) or if they visit an area with an ongoing outbreak. Vaccination should also be considered for travelers to endemic areas who are uncertain of specific duration of travel, destinations, or activities.[44]

Vaccination of people living in endemic areas is also recommended.

Meningococcal vaccination

Many developed countries offer routine childhood vaccination for the prevention of meningococcal disease. For full details of US immunization schedules, including indications for booster doses, the ACIP guidelines should be consulted.

[CDC: immunization schedules] (<https://www.cdc.gov/vaccines/schedules>)

Pneumococcal vaccination

Rates of pneumococcal meningitis have decreased among children and adults since the pneumococcal conjugate vaccine (PCV7, subsequently PCV13) vaccine was introduced. Although the overall effect of the vaccine is substantial, increases in meningitis caused by nonvaccine serotypes, including strains nonsusceptible to antibiotics, remain a concern.[45] [46]

Influenza vaccination

Annual seasonal influenza vaccination can also be recommended to reduce potential extrapulmonary complications including encephalitis.

Secondary prevention

Certain measures are available for the prevention of a limited number of agents (viral and bacterial) that can cause encephalitis.

- Specific drugs: isoniazid for purified protein derivative positivity in tuberculosis and for post-exposure prophylaxis.
- Education and avoidance of risk-taking behavior (unprotected sexual acts): prevention of HIV, syphilis.
- Environmental control (sanitation, vector control and avoidance): Nipah and Hendra virus, all the arboviruses, enteroviruses, typhoid.
- Isolation should be considered for patients who are severely immunosuppressed and those with rabies encephalitis, exanthematous encephalitis, or contagious viral hemorrhagic fever.[99]
- As West Nile virus encephalitis has been reported to occur after blood transfusion and solid organ transplantation, sensitive screening laboratory tests are in development, which may guide future preventive measures.[154] [155]

Patient discussions

There is no general advice for patients, but in the event of certain infections, contact tracing and limiting contamination of the environment (by placing in isolation room, avoiding travel) may be advised. Participation in rehabilitation for those with cognitive and/or motor sequelae should be advised. Input from specialists in neuropsychology and neuropsychiatry as central components of the rehabilitation process, in addition to speech and language therapy, neuro-physiotherapy, and occupational therapy.[13] [151] Access to specialist brain injury rehabilitation services is key to recovery in many cases.[13] [152] Patients affected by encephalitis and those supporting them require information on the condition and its consequences, and directions on how to access this information.[13] [153]

Monitoring

Monitoring

Survivors must undergo intensive inpatient rehabilitation therapy after hospital discharge if their mental status and functional abilities allow. The extent of their functional recovery should be monitored and documented to make suitable arrangements for their further care and living situation. More specifically, these patients should be monitored for the development of a seizure disorder and treated with appropriate antiepileptic drugs. Some patients can develop hydrocephalus, and may benefit from a permanent cerebrospinal fluid drainage procedure such as placement of a ventriculoperitoneal shunt. Encephalitis may increase risk of ADHD and cognitive problems, especially in the pediatric population.^[140] Neuropsychological testing is recommended for survivors of childhood encephalitis.^[126]^[139]

Patients with acute disseminated encephalomyelitis (ADEM) should be followed with serial office visits (to document the appearance of new symptoms). Follow-up MRI brain at 3-6 months is recommended to assess the evolution of ADEM lesions and verify whether they regress in a pattern commonly seen with ADEM.^[18] This follow-up imaging can also serve as a baseline for comparison for possible future episodes of acute demyelination.^[18] The appearance of new symptoms or new MRI changes a few months after the clinical episode of ADEM raises the suspicion of a chronic demyelinating disease (multiple sclerosis).^[150]

Complications

Complications	Timeframe	Likelihood
death	short term	high
<p>Mortality rates vary according to the underlying etiologic agent. Untreated herpes simplex virus (HSV) encephalitis has a mortality rate of around 70%, with early treatment reducing this to approximately 10%.^{[7] [132]} Older age and depressed levels of consciousness (Glasgow Coma Scale <6) are poor prognostic indicators. Rabies and amebic encephalitis are almost universally fatal. High mortality rates are seen with Eastern equine encephalitis, Japanese encephalitis, Nipah virus, and viral hemorrhagic fevers. HIV infection forebodes higher mortality rates in encephalitis.^[7]</p> <p>Early treatment with acyclovir and adequate supportive critical care can decrease mortality associated with HSV encephalitis. For other cases, in addition to specific treatments if available, good supportive critical care medicine is advocated, and there is some indirect evidence that this is associated with decreased mortality rates.</p>		
hypothalamic and autonomic dysfunction	short term	medium
<p>Syndrome of inappropriate secretion of antidiuretic hormone (SIADH), diabetes insipidus (DI), loss of temperature control, and vasomotor instability can occur in patients with encephalitis.</p> <p>SIADH: avoidance of hypotonic fluids and fluid restriction (if possible).</p> <p>DI: maintenance of normovolemia and use of desmopressin.</p> <p>Hyperthermia: antipyretics or cooling devices are used to maintain normothermia, as hyperthermia is associated with worse functional outcomes.</p> <p>Vasomotor instability: monitored in an intensive care unit setting with adequate intravenous access and cardiac and blood pressure monitoring. Treatment is tailored to stabilize these parameters, with the institution of advanced cardiac life support protocols as required.</p>		
ischemic stroke	short term	low
<p>Depending on the extent and severity, worsens the outcome. Antiplatelet or anticoagulant agents can be considered.</p>		
autoimmune encephalitis	long term	medium
<p>Herpes simplex virus (HSV) encephalitis can trigger autoimmune encephalitis that leads to neurologic worsening.^[133] Prospective studies suggest 23% to 27% of patients with herpes simplex encephalitis develop autoimmune encephalitis.^{[133] [144]} Post-HSV-autoimmune encephalitis usually presents within 2 months of treatment of herpes simplex encephalitis; the symptoms are age-dependent, and the neurologic outcome is worse in young children.^{[133] [144]} These patients may respond to immunotherapy.^[58]</p>		
encephalitis lethargica (Von Economo disease)	long term	low
<p>Occurs after 6 months. An extrapyramidal syndrome characterized by somnolence, fatigue, and ophthalmoplegia was seen after the influenza epidemic of 1918. Occasional cases are now reported after sporadic viral encephalitis, especially Japanese encephalitis.^[145]</p>		

Complications	Timeframe	Likelihood
neurologic sequelae	variable	high
Neurologic sequelae occur within one month and include abulia, akinetic mutism, aphasia, amnesia, neuropsychiatric issues, and motor problems. ADHD and cognitive issues can be seen in children. ^[126] ^[139] ^[140] Acute rehabilitation services, speech language therapy, and neuropsychiatric services should be provided for these patients.		
seizures	variable	medium
<p>A frequent component of encephalitis and a consequence of the extensive inflammatory reaction that is integral to encephalitis. The formation of gliotic scars marks the healing phase and can lead to the formation of epileptogenic foci. A neurology consultation is highly recommended for all patients with ongoing seizures.</p> <p>Status epilepticus is defined as 5 or more minutes of either continuous seizure activity or repetitive seizures without regaining consciousness.^[141] ^[142] Treatment involves a stepwise medication approach aimed at aborting the clinical and electrographic seizures. It carries a high mortality rate and may cause serious complications if not promptly treated.</p> <p>Management is best done in consultation with a specialist in neurocritical care or neurology. Seizures can occur in the long term and need to be treated with standard antiepileptic drugs in consultation with a neurologist. See Status epilepticus .</p>		
hypersomnolence and sleep disorders	variable	medium
Sleep disorders in patients with autoimmune encephalitis include parasomnia, insomnia, hypersomnia, and sleep-disordered breathing. ^[146] ^[147] These can be acute and severe, and can often persist beyond the initial stage of the disease. ^[148] Untreated sleep disturbances may worsen autonomic instability, thereby challenging attempts to wean patients from mechanical ventilation. Over the long term, sleep disorders may compromise recovery and return to meaningful function. ^[149] Because sleep disorders are often overshadowed by other neurologic and psychiatric symptoms, patients and caregivers should be specifically questioned about new-onset sleep disruption or behaviors. ^[149]		
cerebral hemorrhage	variable	low
Depending on the extent and severity, worsens the outcome. Hemorrhages are usually medically managed with supportive care and monitoring of blood pressure. Larger bleeds may require surgical interventions.		
cerebral vein thrombosis	variable	low
Depending on the extent and severity, worsens the outcome. The treatment of cerebral vein thrombosis is difficult, as anticoagulant use can increase the risk of hemorrhage.		
cerebral vasculitis	variable	low
Varicella-zoster virus (VZV) encephalitis is frequently associated with a cerebral vasculitic picture. ^[47] Some experts recommend high-dose short-duration corticosteroid therapy ^[13]		

Complications	Timeframe	Likelihood
hydrocephalus	variable	low
Can develop as a late complication with bacterial, fungal, and parasitic encephalitis. This is due to the decreased efficiency of absorption of cerebrospinal fluid from arachnoid granulations. Placement of a draining ventricular catheter/ventriculoperitoneal shunt should be considered.		
postviral chronic fatigue syndrome	variable	low
The syndrome of prolonged and persistent fatigue, myalgia, difficulty concentrating, and postexertional malaise is sometimes seen after viral encephalitis.[143] No specific treatments exist for this condition, but a multidisciplinary approach is advocated.		

Prognosis

Due to the varied etiology, survivors of the critical phases of the illness are a heterogeneous group. Mortality and morbidity vary depending on the underlying etiology, the immune status of the host, the extent and location of anatomic lesions, the development of complications, and the time to initiate treatment. Mortality as an outcome occurs in 6% to 9% in the US, and in 12% in England in infectious encephalitis.[3] [6] [7] [124] Age >65 years old, immunocompromised (HIV or immunosuppressive medication-induced), mechanical ventilation, coma, acute thrombocytopenia, elevated cerebrospinal fluid polymorphonuclear count, cerebral edema, and status epilepticus are associated with poor outcomes.[124] [125]

The development of the late sequelae depends on age, etiology of the encephalitis, and severity of the clinical episode.[75] Severe disability occurs in more than half of survivors. In children, long-term morbidity occurs in up to two-thirds of patients. This includes fatigue, cognitive impairment, attention and deficit disorders, dysphasia, motor impairment, ataxia, epilepsy, and personality changes.[126] [127] [128] [129] Children with isolated cerebellar involvement or respiratory syncytial virus encephalitis tend to have a good prognosis.

Postencephalitic epilepsy occurs in 10% by 5 years and 20% by 20 years.[130] The presence of seizures during hospitalization and an abnormal brain magnetic resonance imaging are the strongest predictors of development of postencephalitic epilepsy. The etiology of encephalitis, presence of focal neurologic deficits, and interictal electroencephalographic abnormalities do not influence development of postencephalitic epilepsy.[131]

For herpes simplex virus encephalitis, older age, decreased level of consciousness, and delay or lack of treatment with acyclovir are associated with high mortality rates. Diffuse cerebral edema and intractable seizures are additional poor prognostic indicators. Survivors frequently have disabling neurologic sequelae such as (short-term) memory impairment, personality and behavioral changes, psychiatric issues, and anosmia.[132] Some have observed associations of anti-NMDAR encephalitis after HSV encephalitis.[133] Severe behavioral and personality changes including Kluver-Bucy syndrome, seen before acyclovir became widely available, are no longer common.

Mortality rates in autoimmune encephalitis are generally lower than in infectious cases; however, prolonged recovery and potential for relapse make longer-term management challenging.[1] Mortality rates for anti-N-methyl-D-aspartate (NMDA) receptor encephalitis are up to 6%, and relapse occurs in 12% to 25% of patients.[31] [134] [135] Earlier immune treatment has been associated with better outcomes but cognitive and behavioral changes may persist.[31] [135][136] Mortality rates may be lower for anti-leucine-rich glioma-inactivated 1 encephalitis than anti-NMDA encephalitis, but longer-term relapse rates might be higher.[1] [137] [138]

Diagnostic guidelines

International

Guide to utilization of the microbiology laboratory for diagnosis of infectious diseases (https://www.idsociety.org/practice-guideline/practice-guidelines/#/+0/date_na_dt/desc) [26]

Published by: Infectious Diseases Society of America (IDSA); American Society for Microbiology (ASM) **Last published:** 2024

Canadian consensus guidelines for the diagnosis and treatment of autoimmune encephalitis in adults (<https://www.cambridge.org/core/journals/canadian-journal-of-neurological-sciences/article/canadian-consensus-guidelines-for-the-diagnosis-and-treatment-of-autoimmune-encephalitis-in-adults/DC88204486B656B85324E93AF2CCCCFC7>) [67]

Published by: Canadian Neurological Sciences Federation **Last published:** 2024

Updated diagnostic criteria for paraneoplastic neurologic syndromes (PNS) (<https://www.ncbi.nlm.nih.gov/pmc/articles/PMC8237398>) [53]

Published by: PNS care panel **Last published:** 2021

Case definitions, diagnostic algorithms, and priorities in encephalitis: consensus statement of the International Encephalitis Consortium (<https://academic.oup.com/cid/article/57/8/1114/529190/Case-Definitions-Diagnostic-Algorithms-and>) [2]

Published by: International Encephalitis Consortium **Last published:** 2013

EAN consensus review on prevention, diagnosis and management of tick-borne encephalitis (<https://www.eanpages.org/2017/07/07/scientific-panel-on-infectious-diseases-ean-consensus-review-on-prevention-diagnosis-and-management-of-tick-borne-encephalitis>) [14]

Published by: European Academy of Neurology (European Federation of Neurological Societies) **Last published:** 2017

Guidelines on the management of infectious encephalitis in adults (<https://www.sciencedirect.com/science/article/pii/S0399077X17300240>) [47]

Published by: French Infectious Diseases Society **Last published:** 2017

Treatment guidelines

International

Canadian consensus guidelines for the diagnosis and treatment of autoimmune encephalitis in adults (<https://www.cambridge.org/core/journals/canadian-journal-of-neurological-sciences/article/canadian-consensus-guidelines-for-the-diagnosis-and-treatment-of-autoimmune-encephalitis-in-adults/DC88204486B656B85324E93AF2CCCCFC7>) [67]

Published by: Canadian Neurological Sciences Federation

Last published: 2024

EAN consensus review on prevention, diagnosis and management of tick-borne encephalitis (<https://www.eanpages.org/2017/07/07/scientific-panel-on-infectious-diseases-ean-consensus-review-on-prevention-diagnosis-and-management-of-tick-borne-encephalitis>) [14]

Published by: European Academy of Neurology (European Federation of Neurological Societies)

Last published: 2017

Guidelines on the management of infectious encephalitis in adults (<https://www.sciencedirect.com/science/article/pii/S0399077X17300240>) [47]

Published by: French Infectious Diseases Society

Last published: 2017

Online resources

1. [CDC: Division of vector-borne diseases \(DVBD\) \(http://www.cdc.gov/ncezid/dvbd/about.html\)](http://www.cdc.gov/ncezid/dvbd/about.html) (*external link*)
2. [CDC: immunization schedules \(https://www.cdc.gov/vaccines/schedules\)](https://www.cdc.gov/vaccines/schedules) (*external link*)
3. [CDC: Influenza \(Flu\) \(https://www.cdc.gov/flu/professionals/index.htm\)](https://www.cdc.gov/flu/professionals/index.htm) (*external link*)

Key articles

- Venkatesan A, Tunkel AR, Bloch KC, et al. Case definitions, diagnostic algorithms, and priorities in encephalitis: consensus statement of the International Encephalitis Consortium. Clin Infect Dis. 2013 Oct;57(8):1114-28. [Full text \(https://academic.oup.com/cid/article/57/8/1114/529190/Case-Definitions-Diagnostic-Algorithms-and\)](https://academic.oup.com/cid/article/57/8/1114/529190/Case-Definitions-Diagnostic-Algorithms-and) [Abstract \(http://www.ncbi.nlm.nih.gov/pubmed/23861361?tool=bestpractice.bmj.com\)](http://www.ncbi.nlm.nih.gov/pubmed/23861361?tool=bestpractice.bmj.com)
- Solomon T, Michael BD, Smith PE, et al. Management of suspected viral encephalitis in adults-- Association of British Neurologists and British Infection Association National Guidelines. J Infect. 2012 Apr;64(4):347-73. [Full text \(https://www.doi.org/10.1016/j.jinf.2011.11.014\)](https://www.doi.org/10.1016/j.jinf.2011.11.014) [Abstract \(http://www.ncbi.nlm.nih.gov/pubmed/22120595?tool=bestpractice.bmj.com\)](http://www.ncbi.nlm.nih.gov/pubmed/22120595?tool=bestpractice.bmj.com)
- Miller JM, Binnicker MJ, Campbell S, et al. Guide to utilization of the microbiology laboratory for diagnosis of infectious diseases: 2024 update by the Infectious Diseases Society of America (IDSA) and the American Society for Microbiology (ASM). Clin Infect Dis. 2024 Mar 5;ciae104. [Full text \(https://academic.oup.com/cid/advance-article/doi/10.1093/cid/ciae104/7619499?login=false\)](https://academic.oup.com/cid/advance-article/doi/10.1093/cid/ciae104/7619499?login=false) [Abstract \(http://www.ncbi.nlm.nih.gov/pubmed/38442248?tool=bestpractice.bmj.com\)](http://www.ncbi.nlm.nih.gov/pubmed/38442248?tool=bestpractice.bmj.com)
- Kneen R, Michael BD, Menson E, et al. Management of suspected viral encephalitis in children - Association of British Neurologists and British Paediatric Allergy, Immunology and Infection Group national guidelines. J Infect. 2012 May;64(5):449-77. [Full text \(https://www.doi.org/10.1016/j.jinf.2011.11.013\)](https://www.doi.org/10.1016/j.jinf.2011.11.013) [Abstract \(http://www.ncbi.nlm.nih.gov/pubmed/22120594?tool=bestpractice.bmj.com\)](http://www.ncbi.nlm.nih.gov/pubmed/22120594?tool=bestpractice.bmj.com)

References

1. Venkatesan A, Michael BD, Probasco JC, et al. Acute encephalitis in immunocompetent adults. Lancet. 2019 Feb 16;393(10172):702-16. [Abstract \(http://www.ncbi.nlm.nih.gov/pubmed/30782344?tool=bestpractice.bmj.com\)](http://www.ncbi.nlm.nih.gov/pubmed/30782344?tool=bestpractice.bmj.com)
2. Venkatesan A, Tunkel AR, Bloch KC, et al. Case definitions, diagnostic algorithms, and priorities in encephalitis: consensus statement of the International Encephalitis Consortium. Clin Infect Dis. 2013 Oct;57(8):1114-28. [Full text \(https://academic.oup.com/cid/article/57/8/1114/529190/Case-Definitions-Diagnostic-Algorithms-and\)](https://academic.oup.com/cid/article/57/8/1114/529190/Case-Definitions-Diagnostic-Algorithms-and) [Abstract \(http://www.ncbi.nlm.nih.gov/pubmed/23861361?tool=bestpractice.bmj.com\)](http://www.ncbi.nlm.nih.gov/pubmed/23861361?tool=bestpractice.bmj.com)
3. Granerod J, Tam CC, Crowcroft NS, et al. Challenge of the unknown: a systematic review of acute encephalitis in non-outbreak situations. Neurology. 2010 Sep 7;75(10):924-32. [Abstract \(http://www.ncbi.nlm.nih.gov/pubmed/20820004?tool=bestpractice.bmj.com\)](http://www.ncbi.nlm.nih.gov/pubmed/20820004?tool=bestpractice.bmj.com)
4. Boucher A, Herrmann JL, Morand P, et al. Epidemiology of infectious encephalitis causes in 2016. Med Mal Infect. 2017 May;47(3):221-35. [Abstract \(http://www.ncbi.nlm.nih.gov/pubmed/28341533?tool=bestpractice.bmj.com\)](http://www.ncbi.nlm.nih.gov/pubmed/28341533?tool=bestpractice.bmj.com)

5. Wang H, Zhao S, Wang S, et al. Global magnitude of encephalitis burden and its evolving pattern over the past 30 years. *J Infect.* 2022 Jun;84(6):777-87. [Full text \(https://www.journalofinfection.com/article/S0163-4453\(22\)00211-0/fulltext\)](https://www.journalofinfection.com/article/S0163-4453(22)00211-0/fulltext) [Abstract \(http://www.ncbi.nlm.nih.gov/pubmed/35452715?tool=bestpractice.bmj.com\)](http://www.ncbi.nlm.nih.gov/pubmed/35452715?tool=bestpractice.bmj.com)
6. Vora NM, Holman RC, Mehal JM, et al. Burden of encephalitis-associated hospitalizations in the United States, 1998-2010. *Neurology.* 2014 Feb 4;82(5):443-51. [Abstract \(http://www.ncbi.nlm.nih.gov/pubmed/24384647?tool=bestpractice.bmj.com\)](http://www.ncbi.nlm.nih.gov/pubmed/24384647?tool=bestpractice.bmj.com)
7. George BP, Schneider EB, Venkatesan A. Encephalitis hospitalization rates and inpatient mortality in the United States, 2000-2010. *PloS One.* 2014 Sep 5;9(9):e104169. [Full text \(http://journals.plos.org/plosone/article?id=10.1371/journal.pone.0104169\)](http://journals.plos.org/plosone/article?id=10.1371/journal.pone.0104169) [Abstract \(http://www.ncbi.nlm.nih.gov/pubmed/25192177?tool=bestpractice.bmj.com\)](http://www.ncbi.nlm.nih.gov/pubmed/25192177?tool=bestpractice.bmj.com)
8. Barbadoro P, Marigliano A, Ricciardi A, et al. Trend of hospital utilization for encephalitis. *Epidemiol Infect.* 2012 Apr;140(4):753-64. [Abstract \(http://www.ncbi.nlm.nih.gov/pubmed/21733247?tool=bestpractice.bmj.com\)](http://www.ncbi.nlm.nih.gov/pubmed/21733247?tool=bestpractice.bmj.com)
9. Bernard S, Mailles A, Stahl JP, et al. Epidemiology of infectious encephalitis, differences between a prospective study and hospital discharge data. *Epidemiol Infect.* 2013 Nov;141(11):2256-68. [Abstract \(http://www.ncbi.nlm.nih.gov/pubmed/23168268?tool=bestpractice.bmj.com\)](http://www.ncbi.nlm.nih.gov/pubmed/23168268?tool=bestpractice.bmj.com)
10. Huppatz C, Durrheim DN, Levi C, et al. Etiology of encephalitis in Australia, 1990-2007. *Emerg Infect Dis.* 2009 Sep;15(9):1359-65. [Full text \(https://wwwnc.cdc.gov/eid/article/15/9/08-1540_article\)](https://wwwnc.cdc.gov/eid/article/15/9/08-1540_article) [Abstract \(http://www.ncbi.nlm.nih.gov/pubmed/19788802?tool=bestpractice.bmj.com\)](http://www.ncbi.nlm.nih.gov/pubmed/19788802?tool=bestpractice.bmj.com)
11. Kulkarni MA, Lecocq AC, Artsob H, et al. Epidemiology and aetiology of encephalitis in Canada, 1994-2008: a case for undiagnosed arboviral agents? *Epidemiol Infect.* 2013 Nov;141(11):2243-55. [Abstract \(http://www.ncbi.nlm.nih.gov/pubmed/23148910?tool=bestpractice.bmj.com\)](http://www.ncbi.nlm.nih.gov/pubmed/23148910?tool=bestpractice.bmj.com)
12. Granerod J, Cousens S, Davies NW, et al. New estimates of incidence of encephalitis in England. *Emerg Infect Dis.* 2013;19(9). [Full text \(https://wwwnc.cdc.gov/eid/article/19/9/13-0064_article\)](https://wwwnc.cdc.gov/eid/article/19/9/13-0064_article) [Abstract \(http://www.ncbi.nlm.nih.gov/pubmed/23969035?tool=bestpractice.bmj.com\)](http://www.ncbi.nlm.nih.gov/pubmed/23969035?tool=bestpractice.bmj.com)
13. Solomon T, Michael BD, Smith PE, et al. Management of suspected viral encephalitis in adults--Association of British Neurologists and British Infection Association National Guidelines. *J Infect.* 2012 Apr;64(4):347-73. [Full text \(https://www.doi.org/10.1016/j.jinf.2011.11.014\)](https://www.doi.org/10.1016/j.jinf.2011.11.014) [Abstract \(http://www.ncbi.nlm.nih.gov/pubmed/22120595?tool=bestpractice.bmj.com\)](http://www.ncbi.nlm.nih.gov/pubmed/22120595?tool=bestpractice.bmj.com)
14. Taba P, Schmutzhard E, Forsberg P, et al. EAN consensus review on prevention, diagnosis and management of tick-borne encephalitis. *Eur J Neurol.* 2017 Oct;24(10):1214-e61. [Abstract \(http://www.ncbi.nlm.nih.gov/pubmed/28762591?tool=bestpractice.bmj.com\)](http://www.ncbi.nlm.nih.gov/pubmed/28762591?tool=bestpractice.bmj.com)
15. UK Government guidance. Tick-borne encephalitis: epidemiology, diagnosis and prevention: Advice for health professionals on tick-borne encephalitis (TBE) including symptoms, diagnosis and epidemiology. [Full text \(https://www.gov.uk/guidance/tick-borne-encephalitis-epidemiology-diagnosis-and-prevention#epidemiology\)](https://www.gov.uk/guidance/tick-borne-encephalitis-epidemiology-diagnosis-and-prevention#epidemiology)

16. European Centre for Disease Prevention and Control. Tick-borne encephalitis - annual epidemiological report for 2019. Apr 2024 [internet publication]. [Full text \(https://www.ecdc.europa.eu/en/publications-data/tick-borne-encephalitis-annual-epidemiological-report-2021\)](https://www.ecdc.europa.eu/en/publications-data/tick-borne-encephalitis-annual-epidemiological-report-2021)
17. Banwell B, Kennedy J, Sadovnick D, et al. Incidence of acquired demyelination of the CNS in Canadian children. *Neurology*. 2009 Jan 20;72(3):232-9. [Abstract \(http://www.ncbi.nlm.nih.gov/pubmed/19153370?tool=bestpractice.bmj.com\)](http://www.ncbi.nlm.nih.gov/pubmed/19153370?tool=bestpractice.bmj.com)
18. Wang CX. Assessment and management of acute disseminated encephalomyelitis (ADEM) in the pediatric patient. *Paediatr Drugs*. 2021 May;23(3):213-21. [Full text \(https://www.ncbi.nlm.nih.gov/pmc/articles/PMC8026386\)](https://www.ncbi.nlm.nih.gov/pmc/articles/PMC8026386) [Abstract \(http://www.ncbi.nlm.nih.gov/pubmed/33830467?tool=bestpractice.bmj.com\)](http://www.ncbi.nlm.nih.gov/pubmed/33830467?tool=bestpractice.bmj.com)
19. Fontenot G, Johnston K, Cohen JC, et al. PCR amplification of HIV-1 proteinase sequences directly from lab isolates allows determination of five conserved domains. *Virology*. 1992 Sep;190(1):1-10. [Abstract \(http://www.ncbi.nlm.nih.gov/pubmed/1529522?tool=bestpractice.bmj.com\)](http://www.ncbi.nlm.nih.gov/pubmed/1529522?tool=bestpractice.bmj.com)
20. Cole J, Evans E, Mwangi M, et al. Acute disseminated encephalomyelitis in children: an updated review based on current diagnostic criteria. *Pediatr Neurol*. 2019 Nov;100:26-34. [Abstract \(http://www.ncbi.nlm.nih.gov/pubmed/31371120?tool=bestpractice.bmj.com\)](http://www.ncbi.nlm.nih.gov/pubmed/31371120?tool=bestpractice.bmj.com)
21. Galanakis E, Tzoufi M, Katragkou A, et al. A prospective multicenter study of childhood encephalitis in Greece. *Pediatr Infect Dis J*. 2009 Aug;28(8):740-2. [Abstract \(http://www.ncbi.nlm.nih.gov/pubmed/19633519?tool=bestpractice.bmj.com\)](http://www.ncbi.nlm.nih.gov/pubmed/19633519?tool=bestpractice.bmj.com)
22. Kolski H, Ford-Jones EL, Richardson S, et al. Etiology of acute childhood encephalitis at The Hospital for Sick Children, Toronto, 1994-1995. *Clin Infect Dis*. 1998 Feb;26(2):398-409. [Abstract \(http://www.ncbi.nlm.nih.gov/pubmed/9502462?tool=bestpractice.bmj.com\)](http://www.ncbi.nlm.nih.gov/pubmed/9502462?tool=bestpractice.bmj.com)
23. Lee TC, Guo HR, Su HJ, et al. Diseases caused by enterovirus 71 infection. *Pediatr Infect Dis J*. 2009 Oct;28(10):904-10. [Abstract \(http://www.ncbi.nlm.nih.gov/pubmed/20118685?tool=bestpractice.bmj.com\)](http://www.ncbi.nlm.nih.gov/pubmed/20118685?tool=bestpractice.bmj.com)
24. Mailles A, Stahl JP; Steering Committee and Investigators Group. Infectious encephalitis in France in 2007: a national prospective study. *Clin Infect Dis*. 2009 Dec 15;49(12):1838-47. [Full text \(https://academic.oup.com/cid/article/49/12/1838/436552/Infectious-Encephalitis-in-France-in-2007-A\)](https://academic.oup.com/cid/article/49/12/1838/436552/Infectious-Encephalitis-in-France-in-2007-A) [Abstract \(http://www.ncbi.nlm.nih.gov/pubmed/19929384?tool=bestpractice.bmj.com\)](http://www.ncbi.nlm.nih.gov/pubmed/19929384?tool=bestpractice.bmj.com)
25. Srey VH, Sadones H, Ong S, et al. Etiology of encephalitis syndrome among hospitalized children and adults in Takeo, Cambodia, 1999-2000. *Am J Trop Med Hyg*. 2002 Feb;66(2):200-7. [Abstract \(http://www.ncbi.nlm.nih.gov/pubmed/12135294?tool=bestpractice.bmj.com\)](http://www.ncbi.nlm.nih.gov/pubmed/12135294?tool=bestpractice.bmj.com)
26. Miller JM, Binnicker MJ, Campbell S, et al. Guide to utilization of the microbiology laboratory for diagnosis of infectious diseases: 2024 update by the Infectious Diseases Society of America (IDSA) and the American Society for Microbiology (ASM). *Clin Infect Dis*. 2024 Mar 5;ciae104. [Full text \(https://academic.oup.com/cid/advance-article/doi/10.1093/cid/ciae104/7619499?login=false\)](https://academic.oup.com/cid/advance-article/doi/10.1093/cid/ciae104/7619499?login=false) [Abstract \(http://www.ncbi.nlm.nih.gov/pubmed/38442248?tool=bestpractice.bmj.com\)](http://www.ncbi.nlm.nih.gov/pubmed/38442248?tool=bestpractice.bmj.com)

27. Suresh KP, Nayak A, Dhanze H, et al. Prevalence of Japanese encephalitis (JE) virus in mosquitoes and animals of the Asian continent: a systematic review and meta-analysis. *J Infect Public Health*. 2022 Sep;15(9):942-9. [Full text \(https://www.sciencedirect.com/science/article/pii/S1876034122001885?via%3Dihub\)](https://www.sciencedirect.com/science/article/pii/S1876034122001885?via%3Dihub) [Abstract \(http://www.ncbi.nlm.nih.gov/pubmed/35914358?tool=bestpractice.bmj.com\)](http://www.ncbi.nlm.nih.gov/pubmed/35914358?tool=bestpractice.bmj.com)
28. Campbell GL, Hills SL, Fischer M, et al. Estimated global incidence of Japanese encephalitis: a systematic review. *Bull World Health Organ*. 2011 Oct 1;89(10):766-74, 774A-774E. [Full text \(https://www.ncbi.nlm.nih.gov/pmc/articles/PMC3209971\)](https://www.ncbi.nlm.nih.gov/pmc/articles/PMC3209971) [Abstract \(http://www.ncbi.nlm.nih.gov/pubmed/22084515?tool=bestpractice.bmj.com\)](http://www.ncbi.nlm.nih.gov/pubmed/22084515?tool=bestpractice.bmj.com)
29. Fagre AC, Lyons S, Staples JE, et al. West Nile virus and other nationally notifiable arboviral diseases - United States, 2021. *MMWR Morb Mortal Wkly Rep*. 2023 Aug 25;72(34):901-6. [Full text \(https://www.ncbi.nlm.nih.gov/pmc/articles/PMC10468221\)](https://www.ncbi.nlm.nih.gov/pmc/articles/PMC10468221) [Abstract \(http://www.ncbi.nlm.nih.gov/pubmed/37616182?tool=bestpractice.bmj.com\)](http://www.ncbi.nlm.nih.gov/pubmed/37616182?tool=bestpractice.bmj.com)
30. Gable MS, Sheriff H, Dalmau J, et al. The frequency of autoimmune N-methyl-D-aspartate receptor encephalitis surpasses that of individual viral etiologies in young individuals enrolled in the California Encephalitis Project. *Clin Infect Dis*. 2012 Apr;54(7):899-904. [Full text \(https://academic.oup.com/cid/article/54/7/899/297744/The-Frequency-of-Autoimmune-N-Methyl-D-Aspartate\)](https://academic.oup.com/cid/article/54/7/899/297744/The-Frequency-of-Autoimmune-N-Methyl-D-Aspartate) [Abstract \(http://www.ncbi.nlm.nih.gov/pubmed/22281844?tool=bestpractice.bmj.com\)](http://www.ncbi.nlm.nih.gov/pubmed/22281844?tool=bestpractice.bmj.com)
31. Titulaer MJ, McCracken L, Gabilondo I, et al. Treatment and prognostic factors for long-term outcome in patients with anti-NMDA receptor encephalitis: an observational cohort study. *Lancet Neurol*. 2013 Feb;12(2):157-65. [Full text \(http://www.ncbi.nlm.nih.gov/pmc/articles/PMC3563251\)](http://www.ncbi.nlm.nih.gov/pmc/articles/PMC3563251) [Abstract \(http://www.ncbi.nlm.nih.gov/pubmed/23290630?tool=bestpractice.bmj.com\)](http://www.ncbi.nlm.nih.gov/pubmed/23290630?tool=bestpractice.bmj.com)
32. Cho H, Proll SC, Szretter KJ, et al. Differential innate immune response programs in neuronal subtypes determine susceptibility to infection in the brain by positive-stranded RNA viruses. *Nat Med*. 2013 Apr;19(4):458-64. [Full text \(http://www.ncbi.nlm.nih.gov/pmc/articles/PMC3618596\)](http://www.ncbi.nlm.nih.gov/pmc/articles/PMC3618596) [Abstract \(http://www.ncbi.nlm.nih.gov/pubmed/23455712?tool=bestpractice.bmj.com\)](http://www.ncbi.nlm.nih.gov/pubmed/23455712?tool=bestpractice.bmj.com)
33. Venkatesan A, Geocadin RG. Diagnosis and management of acute encephalitis: a practical approach. *Neurol Clin Pract*. 2014 Jun;4(3):206-15. [Full text \(http://www.ncbi.nlm.nih.gov/pmc/articles/PMC4121461\)](http://www.ncbi.nlm.nih.gov/pmc/articles/PMC4121461) [Abstract \(http://www.ncbi.nlm.nih.gov/pubmed/25110619?tool=bestpractice.bmj.com\)](http://www.ncbi.nlm.nih.gov/pubmed/25110619?tool=bestpractice.bmj.com)
34. Britton PN, Eastwood K, Paterson B, et al. Consensus guidelines for the investigation and management of encephalitis in adults and children in Australia and New Zealand. *Intern Med J*. 2015 May;45(5):563-76. [Full text \(http://onlinelibrary.wiley.com/doi/10.1111/imj.12749/full\)](http://onlinelibrary.wiley.com/doi/10.1111/imj.12749/full) [Abstract \(http://www.ncbi.nlm.nih.gov/pubmed/25955462?tool=bestpractice.bmj.com\)](http://www.ncbi.nlm.nih.gov/pubmed/25955462?tool=bestpractice.bmj.com)
35. Vogrig A, Tartaglia S, Dentoni M, et al. Central nervous system immune-related disorders after SARS-CoV-2 vaccination: a multicenter study. *Front Immunol*. 2024;15:1344184. [Full text \(https://www.ncbi.nlm.nih.gov/pmc/articles/PMC10876052\)](https://www.ncbi.nlm.nih.gov/pmc/articles/PMC10876052) [Abstract \(http://www.ncbi.nlm.nih.gov/pubmed/38375477?tool=bestpractice.bmj.com\)](http://www.ncbi.nlm.nih.gov/pubmed/38375477?tool=bestpractice.bmj.com)
36. Nabizadeh F, Noori M, Rahmani S, et al. Acute disseminated encephalomyelitis (ADEM) following COVID-19 vaccination: a systematic review. *J Clin Neurosci*. 2023 May;111:57-70. [Full text](#)

- (<https://www.ncbi.nlm.nih.gov/pmc/articles/PMC10030273>) Abstract (<http://www.ncbi.nlm.nih.gov/pubmed/36963124?tool=bestpractice.bmj.com>)
37. Mekki M, Eley B, Hardie D, et al. Subacute sclerosing panencephalitis: clinical phenotype, epidemiology, and preventive interventions. *Dev Med Child Neurol*. 2019 Oct;61(10):1139-44. Abstract (<http://www.ncbi.nlm.nih.gov/pubmed/30680706?tool=bestpractice.bmj.com>)
 38. Srinivasan A, Burton EC, Kuehnert MJ, et al. Transmission of rabies virus from an organ donor to four transplant recipients. *N Engl J Med*. 2005 Mar 17;352(11):1103-11. Full text (<http://www.nejm.org/doi/full/10.1056/NEJMoa043018#t=article>) Abstract (<http://www.ncbi.nlm.nih.gov/pubmed/15784663?tool=bestpractice.bmj.com>)
 39. Abboud H, Probasco JC, Irani S, et al. Autoimmune encephalitis: proposed best practice recommendations for diagnosis and acute management. *J Neurol Neurosurg Psychiatry*. 2021 Jul;92(7):757-68. Full text (<https://www.ncbi.nlm.nih.gov/pmc/articles/PMC8223680>) Abstract (<http://www.ncbi.nlm.nih.gov/pubmed/33649022?tool=bestpractice.bmj.com>)
 40. World Health Organization. Tick-borne encephalitis: prevention. 2021 [internet publication]. Full text (https://www.who.int/health-topics/tick-borne-encephalitis#tab=tab_3)
 41. World Health Organization. Immunization, vaccines and biologicals: tick-borne encephalitis. [internet publication]. Full text (<https://www.who.int/teams/immunization-vaccines-and-biologicals/diseases/tick-borne-encephalitis>)
 42. US Centers for Disease Control and Prevention. Tick-borne encephalitis vaccine. Aug 2021 [internet publication]. Full text (https://www.cdc.gov/ticks/tbe_vaccine/index.html)
 43. US Centers for Disease Control and Prevention. Tick-borne encephalitis. For healthcare providers. Vaccine. Mar 2022 [internet publication]. Full text (<https://www.cdc.gov/tick-borne-encephalitis/healthcare-providers/hcp-vaccine.html>)
 44. Centers for Disease Control and Prevention. Japanese encephalitis vaccine information for healthcare providers. May 2024 [internet publication]. Full text (https://www.cdc.gov/japanese-encephalitis/hcp/vaccine/?CDC_AAref_Val=https://www.cdc.gov/japaneseencephalitis/vaccine/index.html)
 45. Hsu HE, Shutt KA, Moore MR, et al. Effect of pneumococcal conjugate vaccine on pneumococcal meningitis. *N Engl J Med*. 2009 Jan 15;360(3):244-56. Full text (<http://www.nejm.org/doi/full/10.1056/NEJMoa0800836#t=article>) Abstract (<http://www.ncbi.nlm.nih.gov/pubmed/19144940?tool=bestpractice.bmj.com>)
 46. Koelman DLH, Brouwer MC, van de Beek D. Resurgence of pneumococcal meningitis in Europe and Northern America. *Clin Microbiol Infect*. 2020 Feb;26(2):199-204. Full text ([https://www.clinicalmicrobiologyandinfection.com/article/S1198-743X\(19\)30210-1/fulltext](https://www.clinicalmicrobiologyandinfection.com/article/S1198-743X(19)30210-1/fulltext)) Abstract (<http://www.ncbi.nlm.nih.gov/pubmed/31100424?tool=bestpractice.bmj.com>)
 47. Stahl JP, Azouvi P, Bruneel F, et al. Guidelines on the management of infectious encephalitis in adults. *Med Mal Infect*. 2017 May;47(3):179-94. Full text (<https://www.sciencedirect.com/science/article/>)

pii/S0399077X17300240?via%3Dihub) Abstract (<http://www.ncbi.nlm.nih.gov/pubmed/28412044?tool=bestpractice.bmj.com>)

48. Irani SR, Michell AW, Lang B, et al. Faciobrachial dystonic seizures precede Lgi1 antibody limbic encephalitis. *Ann Neurol*. 2011 May;69(5):892-900. Abstract (<http://www.ncbi.nlm.nih.gov/pubmed/21416487?tool=bestpractice.bmj.com>)
49. Gadoth A, Pittock SJ, Dubey D, et al. Expanded phenotypes and outcomes among 256 LGI1/CASPR2-IgG-positive patients. *Ann Neurol*. 2017 Jul;82(1):79-92. Abstract (<http://www.ncbi.nlm.nih.gov/pubmed/28628235?tool=bestpractice.bmj.com>)
50. Graus F, Titulaer MJ, Balu R, et al. A clinical approach to diagnosis of autoimmune encephalitis. *Lancet Neurol*. 2016 Apr;15(4):391-404. Full text (<https://www.ncbi.nlm.nih.gov/pmc/articles/PMC5066574>) Abstract (<http://www.ncbi.nlm.nih.gov/pubmed/26906964?tool=bestpractice.bmj.com>)
51. Dalmau J, Graus F. Antibody-mediated encephalitis. *N Engl J Med*. 2018 Mar 1;378(9):840-51. Full text (http://diposit.ub.edu/dspace/bitstream/2445/147222/1/12474_3406239_antibody-mediated_encephalitis.pdf) Abstract (<http://www.ncbi.nlm.nih.gov/pubmed/29490181?tool=bestpractice.bmj.com>)
52. van Sonderen A, Schreurs MW, Wirtz PW, et al. From VGKC to LGI1 and Caspr2 encephalitis: The evolution of a disease entity over time. *Autoimmun Rev*. 2016 Oct;15(10):970-4. Full text (<https://www.sciencedirect.com/science/article/pii/S156899721630163X?via%3Dihub>) Abstract (<http://www.ncbi.nlm.nih.gov/pubmed/27485013?tool=bestpractice.bmj.com>)
53. Graus F, Vogrig A, Muñoz-Castrillo S, et al. Updated diagnostic criteria for paraneoplastic neurologic syndromes. *Neurol Neuroimmunol Neuroinflamm*. 2021 Jul;8(4):e1014. Full text (<https://www.ncbi.nlm.nih.gov/pmc/articles/PMC8237398>) Abstract (<http://www.ncbi.nlm.nih.gov/pubmed/34006622?tool=bestpractice.bmj.com>)
54. Gresa-Arribas N, Titulaer MJ, Torrents A, et al. Antibody titres at diagnosis and during follow-up of anti-NMDA receptor encephalitis: a retrospective study. *Lancet Neurol*. 2014 Feb;13(2):167-77. Full text (<https://www.ncbi.nlm.nih.gov/pmc/articles/PMC4006368>) Abstract (<http://www.ncbi.nlm.nih.gov/pubmed/24360484?tool=bestpractice.bmj.com>)
55. Prüss H, Finke C, Höltje M, et al. N-methyl-D-aspartate receptor antibodies in herpes simplex encephalitis. *Ann Neurol*. 2012 Dec;72(6):902-11. Full text (<https://www.ncbi.nlm.nih.gov/pmc/articles/PMC3725636>) Abstract (<http://www.ncbi.nlm.nih.gov/pubmed/23280840?tool=bestpractice.bmj.com>)
56. Armangue T, Leypoldt F, Málaga I, et al. Herpes simplex virus encephalitis is a trigger of brain autoimmunity. *Ann Neurol*. 2014 Feb;75(2):317-23. Full text (<https://www.ncbi.nlm.nih.gov/pmc/articles/PMC3961499>) Abstract (<http://www.ncbi.nlm.nih.gov/pubmed/24318406?tool=bestpractice.bmj.com>)
57. Armangue T, Moris G, Cantarín-Extremuera V, et al. Autoimmune post-herpes simplex encephalitis of adults and teenagers. *Neurology*. 2015 Nov 17;85(20):1736-43. Full text (<https://www.ncbi.nlm.nih.gov/pmc/articles/PMC4653102>) Abstract (<http://www.ncbi.nlm.nih.gov/pubmed/26491084?tool=bestpractice.bmj.com>)

58. Nosadini M, Mohammad SS, Corazza F, et al. Herpes simplex virus-induced anti-N-methyl-d-aspartate receptor encephalitis: a systematic literature review with analysis of 43 cases. *Dev Med Child Neurol*. 2017 Aug;59(8):796-805. [Full text \(https://www.doi.org/10.1111/dmcn.13448\)](https://www.doi.org/10.1111/dmcn.13448) [Abstract \(http://www.ncbi.nlm.nih.gov/pubmed/28439890?tool=bestpractice.bmj.com\)](http://www.ncbi.nlm.nih.gov/pubmed/28439890?tool=bestpractice.bmj.com)
59. Gelfand JM, Genrich G, Green AJ, et al. Encephalitis of unclear origin diagnosed by brain biopsy: a diagnostic challenge. *JAMA Neurol*. 2015 Jan;72(1):66-72. [Abstract \(http://www.ncbi.nlm.nih.gov/pubmed/25365755?tool=bestpractice.bmj.com\)](http://www.ncbi.nlm.nih.gov/pubmed/25365755?tool=bestpractice.bmj.com)
60. McGill F, Heyderman RS, Michael BD, et al. The UK joint specialist societies guideline on the diagnosis and management of acute meningitis and meningococcal sepsis in immunocompetent adults. *J Infect*. 2016 Apr;72(4):405-38. [Full text \(https://www.journalofinfection.com/article/S0163-4453\(16\)00024-4/fulltext\)](https://www.journalofinfection.com/article/S0163-4453(16)00024-4/fulltext) [Abstract \(http://www.ncbi.nlm.nih.gov/pubmed/26845731?tool=bestpractice.bmj.com\)](http://www.ncbi.nlm.nih.gov/pubmed/26845731?tool=bestpractice.bmj.com)
61. Sanchez-Juan P, Green A, Ladogana A, et al. CSF tests in the differential diagnosis of Creutzfeldt-Jakob disease. *Neurology*. 2006 Aug 22;67(4):637-43. [Abstract \(http://www.ncbi.nlm.nih.gov/pubmed/16924018?tool=bestpractice.bmj.com\)](http://www.ncbi.nlm.nih.gov/pubmed/16924018?tool=bestpractice.bmj.com)
62. Glaser CA, Honarmand S, Anderson LJ, et al. Beyond viruses: clinical profiles and etiologies associated with encephalitis. *Clin Infect Dis*. 2006 Dec 15;43(12):1565-77. [Full text \(https://academic.oup.com/cid/article/43/12/1565/278153/Beyond-Viruses-Clinical-Profiles-and-Etiologies\)](https://academic.oup.com/cid/article/43/12/1565/278153/Beyond-Viruses-Clinical-Profiles-and-Etiologies) [Abstract \(http://www.ncbi.nlm.nih.gov/pubmed/17109290?tool=bestpractice.bmj.com\)](http://www.ncbi.nlm.nih.gov/pubmed/17109290?tool=bestpractice.bmj.com)
63. Baumgartner A, Rauer S, Mader I, et al. Cerebral FDG-PET and MRI findings in autoimmune limbic encephalitis: correlation with autoantibody types. *J Neurol*. 2013 Nov;260(11):2744-53. [Abstract \(http://www.ncbi.nlm.nih.gov/pubmed/23900756?tool=bestpractice.bmj.com\)](http://www.ncbi.nlm.nih.gov/pubmed/23900756?tool=bestpractice.bmj.com)
64. Lai CW, Gragasin ME. Electroencephalography in herpes simplex encephalitis. *J Clin Neurophysiol*. 1988 Jan;5(1):87-103. [Abstract \(http://www.ncbi.nlm.nih.gov/pubmed/3150762?tool=bestpractice.bmj.com\)](http://www.ncbi.nlm.nih.gov/pubmed/3150762?tool=bestpractice.bmj.com)
65. Gutierrez J, Issacson RS, Koppel BS. Subacute sclerosing panencephalitis: an update. *Dev Med Child Neurol*. 2010 Oct;52(1):901-7. [Abstract \(http://www.ncbi.nlm.nih.gov/pubmed/20561004?tool=bestpractice.bmj.com\)](http://www.ncbi.nlm.nih.gov/pubmed/20561004?tool=bestpractice.bmj.com)
66. Westmoreland BF. The EEG in cerebral inflammatory processes. In: Niedermeyer E, Lopes Da Silva F, eds. *Electroencephalography*. 4th ed. Baltimore, MD: Williams and Wilkins; 1999:302-16.
67. Hahn C, Budhram A, Alikhani K, et al. Canadian consensus guidelines for the diagnosis and treatment of autoimmune encephalitis in adults. *Can J Neurol Sci*. 2024 Feb 5;1-21. [Full text \(https://www.cambridge.org/core/journals/canadian-journal-of-neurological-sciences/article/canadian-consensus-guidelines-for-the-diagnosis-and-treatment-of-autoimmune-encephalitis-in-adults/DC88204486B656B85324E93AF2CCCFC7\)](https://www.cambridge.org/core/journals/canadian-journal-of-neurological-sciences/article/canadian-consensus-guidelines-for-the-diagnosis-and-treatment-of-autoimmune-encephalitis-in-adults/DC88204486B656B85324E93AF2CCCFC7) [Abstract \(http://www.ncbi.nlm.nih.gov/pubmed/38312020?tool=bestpractice.bmj.com\)](http://www.ncbi.nlm.nih.gov/pubmed/38312020?tool=bestpractice.bmj.com)
68. Schmitt SE, Pargeon K, Frechette ES, et al. Extreme delta brush: a unique EEG pattern in adults with anti-NMDA receptor encephalitis. *Neurology*. 2012 Sep 11;79(11):1094-100. [Full text](#)

- (<https://www.ncbi.nlm.nih.gov/pmc/articles/PMC3525298>) Abstract (<http://www.ncbi.nlm.nih.gov/pubmed/22933737?tool=bestpractice.bmj.com>)
69. Dubey D, Pittcock SJ, Kelly CR, et al. Autoimmune encephalitis epidemiology and a comparison to infectious encephalitis. *Ann Neurol*. 2018 Jan;83(1):166-77. Full text (<https://www.ncbi.nlm.nih.gov/pmc/articles/PMC6011827>) Abstract (<http://www.ncbi.nlm.nih.gov/pubmed/29293273?tool=bestpractice.bmj.com>)
 70. Jakob NJ, Lenhard T, Schnitzler P, et al. Herpes simplex virus encephalitis despite normal cell count in the cerebrospinal fluid. *Crit Care Med*. 2012 Apr;40(4):1304-8. Abstract (<http://www.ncbi.nlm.nih.gov/pubmed/22067626?tool=bestpractice.bmj.com>)
 71. Mook-Kanamori B, van de Beek D, Wijdicks EF. Herpes simplex encephalitis with normal initial cerebrospinal fluid examination. *J Am Geriatr Soc*. 2009 Aug;57(8):1514-5. Abstract (<http://www.ncbi.nlm.nih.gov/pubmed/19682154?tool=bestpractice.bmj.com>)
 72. Weil AA, Glaser CA, Amad Z, et al. Patients with suspected herpes simplex encephalitis: rethinking an initial negative polymerase chain reaction result. *Clin Infect Dis*. 2003 Apr 15;34(8):1154-7. Full text (<https://academic.oup.com/cid/article/34/8/1154/284302/Patients-with-Suspected-Herpes-Simplex>) Abstract (<http://www.ncbi.nlm.nih.gov/pubmed/11915008?tool=bestpractice.bmj.com>)
 73. Fodor PA, Levin MJ, Weinberg A, et al. Atypical herpes simplex virus encephalitis diagnosed by PCR amplification of viral DNA from CSF. *Neurology*. 1998 Aug;51(2):554-9. Abstract (<http://www.ncbi.nlm.nih.gov/pubmed/9710034?tool=bestpractice.bmj.com>)
 74. De Biasi RL, Tyler KL. Viral meningitis and encephalitis. *Continuum: Lifelong Learn Neurol*. 2006;12:36.
 75. Chaudhuri A, Kennedy PG. Diagnosis and treatment of viral encephalitis. *Postgrad Med J*. 2002 Oct;78(924):575-83. Full text (<http://pmj.bmj.com/content/78/924/575.long>) Abstract (<http://www.ncbi.nlm.nih.gov/pubmed/12415078?tool=bestpractice.bmj.com>)
 76. Sano K, Satoh K, Atarashi R, et al. Early detection of abnormal prion protein in genetic human prion diseases now possible using real-time QUIC assay. *PLoS One*. 2013;8(1):e54915. Full text (<http://journals.plos.org/plosone/article?id=10.1371/journal.pone.0054915>) Abstract (<http://www.ncbi.nlm.nih.gov/pubmed/23372790?tool=bestpractice.bmj.com>)
 77. Wilson MR, Naccache SN, Samayoa E, et al. Actionable diagnosis of neuroleptospirosis by next-generation sequencing. *N Engl J Med*. 2014 Jun 19;370(25):2408-17. Full text (<http://www.nejm.org/doi/full/10.1056/NEJMoa1401268#t=article>) Abstract (<http://www.ncbi.nlm.nih.gov/pubmed/24896819?tool=bestpractice.bmj.com>)
 78. Schraeder PL, Burns RA. Hemiplegic migraine associated with an aseptic meningeal reaction. *Arch Neurol*. 1980 Jun;37(6):377-9. Abstract (<http://www.ncbi.nlm.nih.gov/pubmed/7387469?tool=bestpractice.bmj.com>)

79. Feely MP, O'Hare J, Veale D, et al. Episodes of acute confusion or psychosis in familial hemiplegic migraine. *Acta Neurol Scand*. 1982 Apr;65(4):369-75. [Abstract \(http://www.ncbi.nlm.nih.gov/pubmed/7102264?tool=bestpractice.bmj.com\)](http://www.ncbi.nlm.nih.gov/pubmed/7102264?tool=bestpractice.bmj.com)
80. Chakrapani A, Cleary MA, Wraith JE. Detection of inborn errors of metabolism in the newborn. *Arch Dis Child Fetal Neonatal Ed*. 2001 May;84(3):F205-10. [Full text \(http://fn.bmj.com/content/84/3/F205.long\)](http://fn.bmj.com/content/84/3/F205.long) [Abstract \(http://www.ncbi.nlm.nih.gov/pubmed/11320051?tool=bestpractice.bmj.com\)](http://www.ncbi.nlm.nih.gov/pubmed/11320051?tool=bestpractice.bmj.com)
81. Burton BK. Inborn errors of metabolism in infancy: a guide to diagnosis. *Pediatrics*. 1998 Dec;102(6):e69. [Full text \(http://pediatrics.aappublications.org/content/102/6/e69.full\)](http://pediatrics.aappublications.org/content/102/6/e69.full) [Abstract \(http://www.ncbi.nlm.nih.gov/pubmed/9832597?tool=bestpractice.bmj.com\)](http://www.ncbi.nlm.nih.gov/pubmed/9832597?tool=bestpractice.bmj.com)
82. Tunkel AR, Hartman BJ, Kaplan SL, et al. Practice guidelines for the management of bacterial meningitis. *Clin Infect Dis*. 2004 Nov 1;39(9):1267-84. [Full text \(https://academic.oup.com/cid/article/39/9/1267/402080/Practice-Guidelines-for-the-Management-of\)](https://academic.oup.com/cid/article/39/9/1267/402080/Practice-Guidelines-for-the-Management-of) [Abstract \(http://www.ncbi.nlm.nih.gov/pubmed/15494903?tool=bestpractice.bmj.com\)](http://www.ncbi.nlm.nih.gov/pubmed/15494903?tool=bestpractice.bmj.com)
83. Greenberg BM. Central nervous system infections in the intensive care unit. *Semin Neurol*. 2008 Nov;28(5):682-9. [Abstract \(http://www.ncbi.nlm.nih.gov/pubmed/19115174?tool=bestpractice.bmj.com\)](http://www.ncbi.nlm.nih.gov/pubmed/19115174?tool=bestpractice.bmj.com)
84. Portegies P, Solod L, Cinque P, et al. Guidelines for the diagnosis and management of neurological complications of HIV infection. *Eur J Neurol*. 2004 May;11(5):297-304. [Abstract \(http://www.ncbi.nlm.nih.gov/pubmed/15142222?tool=bestpractice.bmj.com\)](http://www.ncbi.nlm.nih.gov/pubmed/15142222?tool=bestpractice.bmj.com)
85. Shenoy A, Marwaha PK, Worku DA. CD8 encephalitis in HIV: a review of this emerging entity. *J Clin Med*. 2023 Jan 18;12(3):770. [Full text \(https://www.ncbi.nlm.nih.gov/pmc/articles/PMC9917721\)](https://www.ncbi.nlm.nih.gov/pmc/articles/PMC9917721) [Abstract \(http://www.ncbi.nlm.nih.gov/pubmed/36769419?tool=bestpractice.bmj.com\)](http://www.ncbi.nlm.nih.gov/pubmed/36769419?tool=bestpractice.bmj.com)
86. World Health Organization. Consolidated guidelines on the use of antiretroviral drugs for treating and preventing HIV infection: recommendations for a public health approach, 2nd ed. Jun 2016 [internet publication]. [Full text \(https://www.who.int/publications/i/item/9789241549684\)](https://www.who.int/publications/i/item/9789241549684)
87. Makadzange AT, Mothobi N. Delaying initiation of ART for 5 weeks improves survival in patients with HIV infection with cryptococcal meningitis. *Evid Based Med*. 2015 Feb;20(1):15. [Abstract \(http://www.ncbi.nlm.nih.gov/pubmed/25358332?tool=bestpractice.bmj.com\)](http://www.ncbi.nlm.nih.gov/pubmed/25358332?tool=bestpractice.bmj.com)
88. National Institutes of Health, Centers for Disease Control and Prevention, HIV Medicine Association, and Infectious Diseases Society of America. Panel on Guidelines for the Prevention and Treatment of Opportunistic Infections in Adults and Adolescents with HIV. Guidelines for the prevention and treatment of opportunistic infections in adults and adolescents with HIV: Cryptococcosis. 2024 [internet publication]. [Full text \(https://clinicalinfo.hiv.gov/en/guidelines/hiv-clinical-guidelines-adult-and-adolescent-opportunistic-infections/cryptococcosis\)](https://clinicalinfo.hiv.gov/en/guidelines/hiv-clinical-guidelines-adult-and-adolescent-opportunistic-infections/cryptococcosis)
89. Cook AM, Morgan Jones G, Hawryluk GWJ, et al. Guidelines for the acute treatment of cerebral edema in neurocritical care patients. *Neurocrit Care*. 2020 Jun;32(3):647-66. [Full text \(https://www.ncbi.nlm.nih.gov/pmc/articles/PMC7272487\)](https://www.ncbi.nlm.nih.gov/pmc/articles/PMC7272487) [Abstract \(http://www.ncbi.nlm.nih.gov/pubmed/32227294?tool=bestpractice.bmj.com\)](http://www.ncbi.nlm.nih.gov/pubmed/32227294?tool=bestpractice.bmj.com)

90. Schizodimos T, Soulountsi V, Iasonidou C, et al. An overview of management of intracranial hypertension in the intensive care unit. *J Anesth*. 2020 Oct;34(5):741-57. [Full text \(https://www.ncbi.nlm.nih.gov/pmc/articles/PMC7241587\)](https://www.ncbi.nlm.nih.gov/pmc/articles/PMC7241587) [Abstract \(http://www.ncbi.nlm.nih.gov/pubmed/32440802?tool=bestpractice.bmj.com\)](http://www.ncbi.nlm.nih.gov/pubmed/32440802?tool=bestpractice.bmj.com)
91. Kumar R, Singhi S, Singhi P, et al. Randomized controlled trial comparing cerebral perfusion pressure-targeted therapy versus intracranial pressure-targeted therapy for raised intracranial pressure due to acute CNS infections in children. *Crit Care Med*. 2014 Aug;42(8):1775-87. [Abstract \(http://www.ncbi.nlm.nih.gov/pubmed/24690571?tool=bestpractice.bmj.com\)](http://www.ncbi.nlm.nih.gov/pubmed/24690571?tool=bestpractice.bmj.com)
92. Whitley RJ, Alford CA, Hirsch MS, et al. Vidarabine versus acyclovir therapy in herpes simplex encephalitis. *N Engl J Med*. 1986 Jan 16;314(3):144-9. [Abstract \(http://www.ncbi.nlm.nih.gov/pubmed/3001520?tool=bestpractice.bmj.com\)](http://www.ncbi.nlm.nih.gov/pubmed/3001520?tool=bestpractice.bmj.com)
93. Kneen R, Michael BD, Menson E, et al. Management of suspected viral encephalitis in children - Association of British Neurologists and British Paediatric Allergy, Immunology and Infection Group national guidelines. *J Infect*. 2012 May;64(5):449-77. [Full text \(https://www.doi.org/10.1016/j.jinf.2011.11.013\)](https://www.doi.org/10.1016/j.jinf.2011.11.013) [Abstract \(http://www.ncbi.nlm.nih.gov/pubmed/22120594?tool=bestpractice.bmj.com\)](http://www.ncbi.nlm.nih.gov/pubmed/22120594?tool=bestpractice.bmj.com)
94. Beckham JD, Tyler KL. Encephalitis. In: Mandell GL, Bennett JE, Dolin R, eds. *Mandell, Douglas, and Bennett's principles and practice of infectious diseases*. 7th ed. Philadelphia, PA: Churchill Livingstone; 2010.
95. Alam AM, Easton A, Nicholson TR, et al. Encephalitis: diagnosis, management and recent advances in the field of encephalitides. *Postgrad Med J*. 2023 Jul 21;99(1174):815-25. [Full text \(https://academic.oup.com/pmj/article/99/1174/815/7227945?login=false\)](https://academic.oup.com/pmj/article/99/1174/815/7227945?login=false) [Abstract \(http://www.ncbi.nlm.nih.gov/pubmed/37490360?tool=bestpractice.bmj.com\)](http://www.ncbi.nlm.nih.gov/pubmed/37490360?tool=bestpractice.bmj.com)
96. Allana A, Samannodi M, Hansen MA, et al. Adjunctive steroids in adults with encephalitis: a propensity score analysis. *J Neurol*. 2021 Jun;268(6):2151-60. [Abstract \(http://www.ncbi.nlm.nih.gov/pubmed/33475823?tool=bestpractice.bmj.com\)](http://www.ncbi.nlm.nih.gov/pubmed/33475823?tool=bestpractice.bmj.com)
97. Hodzic E, Hasbun R, Granillo A, et al. Steroids for the treatment of viral encephalitis: a systematic literature review and meta-analysis. *J Neurol*. 2023 Jul;270(7):3603-15. [Full text \(https://www.ncbi.nlm.nih.gov/pmc/articles/PMC10105360\)](https://www.ncbi.nlm.nih.gov/pmc/articles/PMC10105360) [Abstract \(http://www.ncbi.nlm.nih.gov/pubmed/37060361?tool=bestpractice.bmj.com\)](http://www.ncbi.nlm.nih.gov/pubmed/37060361?tool=bestpractice.bmj.com)
98. Whitfield T, Fernandez C, Davies K, et al. Protocol for DexEnceph: a randomised controlled trial of dexamethasone therapy in adults with herpes simplex virus encephalitis. *BMJ Open*. 2021 Jul 22;11(7):e041808. [Full text \(https://www.ncbi.nlm.nih.gov/pmc/articles/PMC8728349\)](https://www.ncbi.nlm.nih.gov/pmc/articles/PMC8728349) [Abstract \(http://www.ncbi.nlm.nih.gov/pubmed/34301646?tool=bestpractice.bmj.com\)](http://www.ncbi.nlm.nih.gov/pubmed/34301646?tool=bestpractice.bmj.com)
99. Steiner I, Budka H, Chaudhuri A, et al. Viral meningoencephalitis: a review of diagnostic methods and guidelines for management. *Eur J Neurol*. 2010 Aug;17(8):999-e57. [Full text \(http://onlinelibrary.wiley.com/doi/10.1111/j.1468-1331.2010.02970.x/full\)](http://onlinelibrary.wiley.com/doi/10.1111/j.1468-1331.2010.02970.x/full) [Abstract \(http://www.ncbi.nlm.nih.gov/pubmed/20236175?tool=bestpractice.bmj.com\)](http://www.ncbi.nlm.nih.gov/pubmed/20236175?tool=bestpractice.bmj.com)

100. Yan HJ. Herpes simplex encephalitis: the role of surgical decompression. *Surg Neurol*. 2002 Jan;57(1):20-4. [Abstract \(http://www.ncbi.nlm.nih.gov/pubmed/11834266?tool=bestpractice.bmj.com\)](http://www.ncbi.nlm.nih.gov/pubmed/11834266?tool=bestpractice.bmj.com)
101. Uy CE, Binks S, Irani SR. Autoimmune encephalitis: clinical spectrum and management. *Pract Neurol*. 2021 Oct;21(5):412-23. [Full text \(https://www.ncbi.nlm.nih.gov/pmc/articles/PMC8461404\)](https://www.ncbi.nlm.nih.gov/pmc/articles/PMC8461404) [Abstract \(http://www.ncbi.nlm.nih.gov/pubmed/34108243?tool=bestpractice.bmj.com\)](http://www.ncbi.nlm.nih.gov/pubmed/34108243?tool=bestpractice.bmj.com)
102. Dalmau J, Lancaster E, Martinez-Hernandez E, et al. Clinical experience and laboratory investigations in patients with anti-NMDAR encephalitis. *Lancet Neurol*. 2011 Jan;10(1):63-74. [Full text \(http://www.ncbi.nlm.nih.gov/pmc/articles/PMC3158385\)](http://www.ncbi.nlm.nih.gov/pmc/articles/PMC3158385) [Abstract \(http://www.ncbi.nlm.nih.gov/pubmed/21163445?tool=bestpractice.bmj.com\)](http://www.ncbi.nlm.nih.gov/pubmed/21163445?tool=bestpractice.bmj.com)
103. McKeon A. Paraneoplastic and other autoimmune disorders of the central nervous system. *Neurohospitalist*. 2013 Apr;3(2):53-64. [Full text \(http://www.ncbi.nlm.nih.gov/pmc/articles/PMC3726118\)](http://www.ncbi.nlm.nih.gov/pmc/articles/PMC3726118) [Abstract \(http://www.ncbi.nlm.nih.gov/pubmed/23983888?tool=bestpractice.bmj.com\)](http://www.ncbi.nlm.nih.gov/pubmed/23983888?tool=bestpractice.bmj.com)
104. Stingl C, Cardinale K, Van Mater H. An update on the treatment of pediatric autoimmune encephalitis. *Curr Treatm Opt Rheumatol*. 2018 Mar;4(1):14-28. [Full text \(https://www.ncbi.nlm.nih.gov/pmc/articles/PMC5957495\)](https://www.ncbi.nlm.nih.gov/pmc/articles/PMC5957495) [Abstract \(http://www.ncbi.nlm.nih.gov/pubmed/29780690?tool=bestpractice.bmj.com\)](http://www.ncbi.nlm.nih.gov/pubmed/29780690?tool=bestpractice.bmj.com)
105. Nosadini M, Thomas T, Eyre M, et al. International consensus recommendations for the treatment of pediatric NMDAR antibody encephalitis. *Neurol Neuroimmunol Neuroinflamm*. 2021 Jul 22;8(5):e1052. [Full text \(https://www.ncbi.nlm.nih.gov/pmc/articles/PMC8299516\)](https://www.ncbi.nlm.nih.gov/pmc/articles/PMC8299516) [Abstract \(http://www.ncbi.nlm.nih.gov/pubmed/34301820?tool=bestpractice.bmj.com\)](http://www.ncbi.nlm.nih.gov/pubmed/34301820?tool=bestpractice.bmj.com)
106. Bartolini L, Muscal E. Differences in treatment of anti-NMDA receptor encephalitis: results of a worldwide survey. *J Neurol*. 2017 Apr;264(4):647-53. [Abstract \(http://www.ncbi.nlm.nih.gov/pubmed/28154970?tool=bestpractice.bmj.com\)](http://www.ncbi.nlm.nih.gov/pubmed/28154970?tool=bestpractice.bmj.com)
107. Dalmau J, Gleichman AJ, Hughes EG, et al. Anti-NMDA-receptor encephalitis: case series and analysis of the effects of antibodies. *Lancet Neurol*. 2008 Dec;7(12):1091-8. [Full text \(https://www.ncbi.nlm.nih.gov/pmc/articles/PMC2607118\)](https://www.ncbi.nlm.nih.gov/pmc/articles/PMC2607118) [Abstract \(http://www.ncbi.nlm.nih.gov/pubmed/18851928?tool=bestpractice.bmj.com\)](http://www.ncbi.nlm.nih.gov/pubmed/18851928?tool=bestpractice.bmj.com)
108. Connelly-Smith L, Alquist CR, Aqui NA, et al. Guidelines on the use of therapeutic apheresis in clinical practice - evidence-based approach from the Writing Committee of the American Society for Apheresis: the ninth special issue. *J Clin Apher*. 2023 Apr;38(2):77-278. [Abstract \(http://www.ncbi.nlm.nih.gov/pubmed/37017433?tool=bestpractice.bmj.com\)](http://www.ncbi.nlm.nih.gov/pubmed/37017433?tool=bestpractice.bmj.com)
109. Fillatre P, Crabol Y, Morand P, et al. Infectious encephalitis: management without etiological diagnosis 48 hours after onset. *Med Mal Infect*. 2017 May;47(3):236-51. [Full text \(https://www.ncbi.nlm.nih.gov/pmc/articles/PMC7131623\)](https://www.ncbi.nlm.nih.gov/pmc/articles/PMC7131623) [Abstract \(http://www.ncbi.nlm.nih.gov/pubmed/28314470?tool=bestpractice.bmj.com\)](http://www.ncbi.nlm.nih.gov/pubmed/28314470?tool=bestpractice.bmj.com)
110. Christie S, Chan V, Mollayeva T, et al. Systematic review of rehabilitation intervention outcomes of adult and paediatric patients with infectious encephalitis. *BMJ Open*. 2018 May 14;8(5):e015928. [Full text \(https://bmjopen.bmj.com/content/8/5/e015928.long\)](https://bmjopen.bmj.com/content/8/5/e015928.long) [Abstract \(http://www.ncbi.nlm.nih.gov/pubmed/29764868?tool=bestpractice.bmj.com\)](http://www.ncbi.nlm.nih.gov/pubmed/29764868?tool=bestpractice.bmj.com)

111. Moorthi S, Schneider WN, Dombovy ML. Rehabilitation outcomes in encephalitis - a retrospective study 1990-1997. *Brain Inj.* 1999 Feb;13(2):139-46. [Abstract \(http://www.ncbi.nlm.nih.gov/pubmed/10079959?tool=bestpractice.bmj.com\)](http://www.ncbi.nlm.nih.gov/pubmed/10079959?tool=bestpractice.bmj.com)
112. Lane-Brown AT, Tate RL. Apathy after acquired brain impairment: a systematic review of non-pharmacological interventions. *Neuropsychol Rehabil.* 2009 Aug;19(4):481-516. [Abstract \(http://www.ncbi.nlm.nih.gov/pubmed/19533496?tool=bestpractice.bmj.com\)](http://www.ncbi.nlm.nih.gov/pubmed/19533496?tool=bestpractice.bmj.com)
113. Pöhlmann C, Schetelig J, Reuner U, et al. Cidofovir and foscarnet for treatment of Human Herpes Virus 6 encephalitis in a neutropenic stem cell transplant recipient. *Clin Infect Dis.* 2007 Jun 15;44(12):e118-20. [Full text \(https://academic.oup.com/cid/article/44/12/e118/280766/Cidofovir-and-Foscarnet-for-Treatment-of-Human\)](https://academic.oup.com/cid/article/44/12/e118/280766/Cidofovir-and-Foscarnet-for-Treatment-of-Human) [Abstract \(http://www.ncbi.nlm.nih.gov/pubmed/17516391?tool=bestpractice.bmj.com\)](http://www.ncbi.nlm.nih.gov/pubmed/17516391?tool=bestpractice.bmj.com)
114. Tunkel AR, Glaser CA, Bloch KC, et al; Infectious Diseases Society of America. The management of encephalitis: clinical practice guidelines by the Infectious Diseases Society of America. [Archived] *Clin Infect Dis.* 2008 Aug 1;47(3):303-27. [Full text \(https://academic.oup.com/cid/article/47/3/303/313455/The-Management-of-Encephalitis-Clinical-Practice\)](https://academic.oup.com/cid/article/47/3/303/313455/The-Management-of-Encephalitis-Clinical-Practice) [Abstract \(http://www.ncbi.nlm.nih.gov/pubmed/18582201?tool=bestpractice.bmj.com\)](http://www.ncbi.nlm.nih.gov/pubmed/18582201?tool=bestpractice.bmj.com)
115. Teixeira Urzêdo Queiroz D, de Cássia Marques Leocádio J, Poggianella Esteves Santana LH, et al. Neurosyphilis masquerading as autoimmune encephalitis. *Pract Neurol.* 2024 Mar 19;24(2):152-4. [Abstract \(http://www.ncbi.nlm.nih.gov/pubmed/38071547?tool=bestpractice.bmj.com\)](http://www.ncbi.nlm.nih.gov/pubmed/38071547?tool=bestpractice.bmj.com)
116. Szilak I, Marty F, Helft J, et al. Neurosyphilis presenting as herpes simplex encephalitis. *Clin Infect Dis.* 2001 Apr 1;32(7):1108-9. [Full text \(https://academic.oup.com/cid/article/32/7/1108/335186?login=false\)](https://academic.oup.com/cid/article/32/7/1108/335186?login=false) [Abstract \(http://www.ncbi.nlm.nih.gov/pubmed/11264042?tool=bestpractice.bmj.com\)](http://www.ncbi.nlm.nih.gov/pubmed/11264042?tool=bestpractice.bmj.com)
117. Wei P, Bao R, Fan Y. Brainstem encephalitis caused by *Listeria monocytogenes*. *Pathogens.* 2020 Aug 30;9(9):715. [Full text \(https://www.ncbi.nlm.nih.gov/pmc/articles/PMC7558588\)](https://www.ncbi.nlm.nih.gov/pmc/articles/PMC7558588) [Abstract \(http://www.ncbi.nlm.nih.gov/pubmed/32872638?tool=bestpractice.bmj.com\)](http://www.ncbi.nlm.nih.gov/pubmed/32872638?tool=bestpractice.bmj.com)
118. Meyer Sauter PM, Jacobs BC, Spuesens EB, et al. Antibody responses to *Mycoplasma pneumoniae*: role in pathogenesis and diagnosis of encephalitis? *PLoS Pathog.* 2014 June 12;10(6):e1003983. [Full text \(http://journals.plos.org/plospathogens/article?id=10.1371/journal.ppat.1003983\)](http://journals.plos.org/plospathogens/article?id=10.1371/journal.ppat.1003983) [Abstract \(http://www.ncbi.nlm.nih.gov/pubmed/24945969?tool=bestpractice.bmj.com\)](http://www.ncbi.nlm.nih.gov/pubmed/24945969?tool=bestpractice.bmj.com)
119. Bradshaw MJ, Lalor KB, Vu N, et al. Child Neurology: Rocky Mountain spotted fever encephalitis. *Neurology.* 2017 Mar 14;88(11):e92-5. [Full text \(https://www.neurology.org/doi/10.1212/WNL.0000000000003722?url_ver=Z39.88-2003&rfr_id=ori:rid:crossref.org&rfr_dat=cr_pub%20%20pubmed\)](https://www.neurology.org/doi/10.1212/WNL.0000000000003722?url_ver=Z39.88-2003&rfr_id=ori:rid:crossref.org&rfr_dat=cr_pub%20%20pubmed) [Abstract \(http://www.ncbi.nlm.nih.gov/pubmed/28289173?tool=bestpractice.bmj.com\)](http://www.ncbi.nlm.nih.gov/pubmed/28289173?tool=bestpractice.bmj.com)
120. Iro MA, Martin NG, Absoud M, et al. Intravenous immunoglobulin for the treatment of childhood encephalitis. *Cochrane Database Syst Rev.* 2017 Oct 2;(10):CD011367. [Full text \(https://www.cochranelibrary.com/cdsr/doi/10.1002/14651858.CD011367.pub2/full\)](https://www.cochranelibrary.com/cdsr/doi/10.1002/14651858.CD011367.pub2/full) [Abstract \(http://www.ncbi.nlm.nih.gov/pubmed/28967695?tool=bestpractice.bmj.com\)](http://www.ncbi.nlm.nih.gov/pubmed/28967695?tool=bestpractice.bmj.com)

121. Ben-Nathan D, Gershoni-Yahalom O, Samina I, et al. Using high titer West Nile intravenous immunoglobulin from selected Israeli donors for treatment of West Nile virus infection. *BMC Infect Dis.* 2009 Feb 17;9:18. [Full text \(https://bmcinfectdis.biomedcentral.com/articles/10.1186/1471-2334-9-18\)](https://bmcinfectdis.biomedcentral.com/articles/10.1186/1471-2334-9-18) [Abstract \(http://www.ncbi.nlm.nih.gov/pubmed/19222853?tool=bestpractice.bmj.com\)](http://www.ncbi.nlm.nih.gov/pubmed/19222853?tool=bestpractice.bmj.com)
122. Wagner JN, Leibetseder A, Troescher A, et al. Efficacy and safety of intravenous immunoglobulins for the treatment of viral encephalitis: a systematic literature review. *J Neurol.* 2022 Feb;269(2):712-24. [Full text \(https://link.springer.com/article/10.1007%2Fs00415-021-10494-w\)](https://link.springer.com/article/10.1007%2Fs00415-021-10494-w) [Abstract \(http://www.ncbi.nlm.nih.gov/pubmed/33675421?tool=bestpractice.bmj.com\)](http://www.ncbi.nlm.nih.gov/pubmed/33675421?tool=bestpractice.bmj.com)
123. Committee on Infectious Diseases. Recommendations for prevention and control of influenza in children, 2020-2021. *Pediatrics.* 2020 Oct;146(4):e2020024588. [Full text \(https://pediatrics.aappublications.org/content/146/4/e2020024588.long\)](https://pediatrics.aappublications.org/content/146/4/e2020024588.long) [Abstract \(http://www.ncbi.nlm.nih.gov/pubmed/32900875?tool=bestpractice.bmj.com\)](http://www.ncbi.nlm.nih.gov/pubmed/32900875?tool=bestpractice.bmj.com)
124. Singh TD, Fugate JE, Rabinstein AA. The spectrum of acute encephalitis: causes, management, and predictors of outcome. *Neurology.* 2015 Jan 27;84(4):359-66. [Abstract \(http://www.ncbi.nlm.nih.gov/pubmed/25540320?tool=bestpractice.bmj.com\)](http://www.ncbi.nlm.nih.gov/pubmed/25540320?tool=bestpractice.bmj.com)
125. Thakur KT, Motta M, Asemota AO, et al. Predictors of outcome in acute encephalitis. *Neurology.* 2013 Aug 27;81(9):793-800. [Full text \(http://www.ncbi.nlm.nih.gov/pmc/articles/PMC3908458\)](http://www.ncbi.nlm.nih.gov/pmc/articles/PMC3908458) [Abstract \(http://www.ncbi.nlm.nih.gov/pubmed/23892708?tool=bestpractice.bmj.com\)](http://www.ncbi.nlm.nih.gov/pubmed/23892708?tool=bestpractice.bmj.com)
126. Michaeli O, Kassis I, Shachor-Meyouhas Y, et al. Long-term motor and cognitive outcome of acute encephalitis. *Pediatrics.* 2014 Mar;133(3):e546-52. [Abstract \(http://www.ncbi.nlm.nih.gov/pubmed/24534397?tool=bestpractice.bmj.com\)](http://www.ncbi.nlm.nih.gov/pubmed/24534397?tool=bestpractice.bmj.com)
127. McJunkin JE, Khan R, de los Reyes EC, et al. Treatment of severe La Crosse encephalitis with intravenous ribavirin following diagnosis by brain biopsy. *Pediatrics.* 1997 Feb;99(2):261-7. [Abstract \(http://www.ncbi.nlm.nih.gov/pubmed/9024460?tool=bestpractice.bmj.com\)](http://www.ncbi.nlm.nih.gov/pubmed/9024460?tool=bestpractice.bmj.com)
128. Fowler A, Stöddberg T, Eriksson M, et al. Childhood encephalitis in Sweden: etiology, clinical presentation and outcome. *Eur J Paediatr Neurol.* 2008 Nov;12(6):484-90. [Abstract \(http://www.ncbi.nlm.nih.gov/pubmed/18313340?tool=bestpractice.bmj.com\)](http://www.ncbi.nlm.nih.gov/pubmed/18313340?tool=bestpractice.bmj.com)
129. Elbers JM, Bitnun A, Richardson SE, et al. A 12-year prospective study of childhood herpes simplex encephalitis: is there a broader spectrum of disease? *Pediatrics.* 2007 Feb;119(2):e399-407. [Abstract \(http://www.ncbi.nlm.nih.gov/pubmed/17272602?tool=bestpractice.bmj.com\)](http://www.ncbi.nlm.nih.gov/pubmed/17272602?tool=bestpractice.bmj.com)
130. Annegers JF, Hauser WA, Beghi E, et al. The risk of unprovoked seizures after encephalitis and meningitis. *Neurology.* 1988 Sep;38(9):1407-10. [Abstract \(http://www.ncbi.nlm.nih.gov/pubmed/3412588?tool=bestpractice.bmj.com\)](http://www.ncbi.nlm.nih.gov/pubmed/3412588?tool=bestpractice.bmj.com)
131. Singh TD, Fugate JE, Hocker SE, et al. Postencephalitic epilepsy: clinical characteristics and predictors. *Epilepsia.* 2015 Jan;56(1):133-8. [Full text \(http://onlinelibrary.wiley.com/doi/10.1111/epi.12879/full\)](http://onlinelibrary.wiley.com/doi/10.1111/epi.12879/full) [Abstract \(http://www.ncbi.nlm.nih.gov/pubmed/25523929?tool=bestpractice.bmj.com\)](http://www.ncbi.nlm.nih.gov/pubmed/25523929?tool=bestpractice.bmj.com)
132. McGrath N, Anderson NE, Croxson MC, et al. Herpes simplex encephalitis treated with acyclovir: diagnosis and long term outcome. *J Neurol Neurosurg Psychiatry.* 1997 Sep;63(3):321-6. [Full text](#)

(<https://www.ncbi.nlm.nih.gov/pmc/articles/PMC2169720/pdf/v063p00321.pdf>) Abstract (<http://www.ncbi.nlm.nih.gov/pubmed/9328248?tool=bestpractice.bmj.com>)

133. Armangue T, Spatola M, Vlagea A, et al. Frequency, symptoms, risk factors, and outcomes of autoimmune encephalitis after herpes simplex encephalitis: a prospective observational study and retrospective analysis. *Lancet Neurol*. 2018 Sep;17(9):760-72. Full text (<https://www.ncbi.nlm.nih.gov/pmc/articles/PMC6128696>) Abstract (<http://www.ncbi.nlm.nih.gov/pubmed/30049614?tool=bestpractice.bmj.com>)
134. Gabilondo I, Saiz A, Galán L, et al. Analysis of relapses in anti-NMDAR encephalitis. *Neurology*. 2011 Sep 6;77(10):996-9. Abstract (<http://www.ncbi.nlm.nih.gov/pubmed/21865579?tool=bestpractice.bmj.com>)
135. Irani SR, Bera K, Waters P, et al. N-methyl-D-aspartate antibody encephalitis: temporal progression of clinical and paraclinical observations in a predominantly non-paraneoplastic disorder of both sexes. *Brain*. 2010 Jun;133(pt 6):1655-67. Full text (<https://www.ncbi.nlm.nih.gov/pmc/articles/PMC2877907>) Abstract (<http://www.ncbi.nlm.nih.gov/pubmed/20511282?tool=bestpractice.bmj.com>)
136. Yeshokumar AK, Gordon-Lipkin E, Arenivas A, et al. Neurobehavioral outcomes in autoimmune encephalitis. *J Neuroimmunol*. 2017 Nov 15;312:8-14. Abstract (<http://www.ncbi.nlm.nih.gov/pubmed/28889962?tool=bestpractice.bmj.com>)
137. Ariño H, Armangué T, Petit-Pedrol M, et al. Anti-LGI1-associated cognitive impairment: Presentation and long-term outcome. *Neurology*. 2016 Aug 23;87(8):759-65. Full text (<https://www.ncbi.nlm.nih.gov/pmc/articles/PMC4999321>) Abstract (<http://www.ncbi.nlm.nih.gov/pubmed/27466467?tool=bestpractice.bmj.com>)
138. van Sonderen A, Thijs RD, Coenders EC, et al. Anti-LGI1 encephalitis: clinical syndrome and long-term follow-up. *Neurology*. 2016 Oct 4;87(14):1449-56. Abstract (<http://www.ncbi.nlm.nih.gov/pubmed/27590293?tool=bestpractice.bmj.com>)
139. Mailles A, De Broucker T, Costanzo P, et al; Steering Committee and Investigators Group. Long-term outcome of patients presenting with acute infectious encephalitis of various causes in France. *Clin Infect Dis*. 2012 May;54(10):1455-64. Full text (<https://academic.oup.com/cid/article/54/10/1455/353171/Long-term-Outcome-of-Patients-Presenting-With>) Abstract (<http://www.ncbi.nlm.nih.gov/pubmed/22460967?tool=bestpractice.bmj.com>)
140. Chou IC, Lin CC, Kao CH. Enterovirus encephalitis increases the risk of attention deficit hyperactivity disorder: a Taiwanese population-based case-control study. *Medicine (Baltimore)*. 2015 Apr;94(16):e707. Abstract (<http://www.ncbi.nlm.nih.gov/pubmed/25906098?tool=bestpractice.bmj.com>)
141. Lowenstein DH, Bleck T, Macdonald RL. It's time to revise the definition of status epilepticus. *Epilepsia*. 1999 Jan;40(1):120-2. Full text (<https://onlinelibrary.wiley.com/resolve/openurl?genre=article&sid=nlm:pubmed&issn=0013-9580&date=1999&volume=40&issue=1&spage=120>) Abstract (<http://www.ncbi.nlm.nih.gov/pubmed/9924914?tool=bestpractice.bmj.com>)

142. Brophy GM, Bell R, Claassen J, et al. Guidelines for the evaluation and management of status epilepticus. *Neurocrit Care*. 2012 Aug;17(1):3-23. [Abstract \(http://www.ncbi.nlm.nih.gov/pubmed/22528274?tool=bestpractice.bmj.com\)](http://www.ncbi.nlm.nih.gov/pubmed/22528274?tool=bestpractice.bmj.com)
143. Behan PO, Bakheit AM. Clinical spectrum of postviral fatigue syndrome. *Br Med Bull*. 1991 Oct;47(4):793-808. [Abstract \(http://www.ncbi.nlm.nih.gov/pubmed/1794085?tool=bestpractice.bmj.com\)](http://www.ncbi.nlm.nih.gov/pubmed/1794085?tool=bestpractice.bmj.com)
144. Armangué T, Olivé-Cirera G, Martínez-Hernandez E, et al. Neurologic complications in herpes simplex encephalitis: clinical, immunological and genetic studies. *Brain*. 2023 Oct 3;146(10):4306-19. [Full text \(https://academic.oup.com/brain/article/146/10/4306/7224774\)](https://academic.oup.com/brain/article/146/10/4306/7224774) [Abstract \(http://www.ncbi.nlm.nih.gov/pubmed/37453099?tool=bestpractice.bmj.com\)](http://www.ncbi.nlm.nih.gov/pubmed/37453099?tool=bestpractice.bmj.com)
145. Pradhan S, Pandey N, Shashank S, et al. Parkinsonism due to predominant involvement of substantia nigra in Japanese encephalitis. *Neurology*. 1999 Nov 10;53(8):1781-6. [Abstract \(http://www.ncbi.nlm.nih.gov/pubmed/10563628?tool=bestpractice.bmj.com\)](http://www.ncbi.nlm.nih.gov/pubmed/10563628?tool=bestpractice.bmj.com)
146. Muñoz-Lopetegi A, Graus F, Dalmau J, et al. Sleep disorders in autoimmune encephalitis. *Lancet Neurol*. 2020 Dec;19(12):1010-22. [Abstract \(http://www.ncbi.nlm.nih.gov/pubmed/33212053?tool=bestpractice.bmj.com\)](http://www.ncbi.nlm.nih.gov/pubmed/33212053?tool=bestpractice.bmj.com)
147. Blattner MS, de Bruin GS, Bucelli RC, et al. Sleep disturbances are common in patients with autoimmune encephalitis. *J Neurol*. 2019 Apr;266(4):1007-15. [Full text \(https://www.ncbi.nlm.nih.gov/pmc/articles/PMC6421090\)](https://www.ncbi.nlm.nih.gov/pmc/articles/PMC6421090) [Abstract \(http://www.ncbi.nlm.nih.gov/pubmed/30741377?tool=bestpractice.bmj.com\)](http://www.ncbi.nlm.nih.gov/pubmed/30741377?tool=bestpractice.bmj.com)
148. Anderson KN, Kelly TP, Griffiths TD. Primary sleep disorders can cause long-term sleep disturbance in patients with autoimmune mediated limbic encephalitis. *Clin Neurol Neurosurg*. 2013 Jul;115(7):1079-82. [Full text \(https://www.sciencedirect.com/science/article/abs/pii/S0303846712005653?via%3DiHub\)](https://www.sciencedirect.com/science/article/abs/pii/S0303846712005653?via%3DiHub) [Abstract \(http://www.ncbi.nlm.nih.gov/pubmed/23177184?tool=bestpractice.bmj.com\)](http://www.ncbi.nlm.nih.gov/pubmed/23177184?tool=bestpractice.bmj.com)
149. Blattner MS, Day GS. Sleep disturbances in patients with autoimmune encephalitis. *Curr Neurol Neurosci Rep*. 2020 Jun 10;20(7):28. [Full text \(https://www.ncbi.nlm.nih.gov/pmc/articles/PMC7295028\)](https://www.ncbi.nlm.nih.gov/pmc/articles/PMC7295028) [Abstract \(http://www.ncbi.nlm.nih.gov/pubmed/32524504?tool=bestpractice.bmj.com\)](http://www.ncbi.nlm.nih.gov/pubmed/32524504?tool=bestpractice.bmj.com)
150. de Seze J, Debouverie M, Zephir H, et al. Acute fulminant demyelinating disease: a descriptive study of 60 patients. *Arch Neurol*. 2007 Oct;64(10):1426-32. [Full text \(https://jamanetwork.com/journals/jamaneurology/fullarticle/794629\)](https://jamanetwork.com/journals/jamaneurology/fullarticle/794629) [Abstract \(http://www.ncbi.nlm.nih.gov/pubmed/17923626?tool=bestpractice.bmj.com\)](http://www.ncbi.nlm.nih.gov/pubmed/17923626?tool=bestpractice.bmj.com)
151. Macniven JA, Poz R, Bainbridge K, et al. Emotional adjustment following cognitive recovery from 'persistent vegetative state': psychological and personal perspectives. *Brain Inj*. 2003 Jun;17(6):525-33. [Abstract \(http://www.ncbi.nlm.nih.gov/pubmed/12745707?tool=bestpractice.bmj.com\)](http://www.ncbi.nlm.nih.gov/pubmed/12745707?tool=bestpractice.bmj.com)
152. Easton A, Atkin K, Hare P. 'A light in a very dark place': the role of a voluntary organisation providing support for those affected by encephalitis. *Neuropsychol Rehabil*. 2007 Aug-Oct;17(4-5):638-47. [Full](#)

text (https://core.ac.uk/reader/52222?utm_source=linkout) Abstract (<http://www.ncbi.nlm.nih.gov/pubmed/17676539?tool=bestpractice.bmj.com>)

153. Solomon T, Hart IJ, Beeching NJ. Viral encephalitis: a clinician's guide. *Pract Neurol*. 2007 Oct;7(5):288-305. Abstract (<http://www.ncbi.nlm.nih.gov/pubmed/17885268?tool=bestpractice.bmj.com>)
154. Centers for Disease Control (CDC). West Nile virus transmission via organ transplantation and blood transfusion - Louisiana, 2008. *MMWR Morb Mortal Wkly Rep*. 2009 Nov 20;58(45):1263-7. Full text (<http://www.cdc.gov/mmwr/preview/mmwrhtml/mm5845a3.htm>) Abstract (<http://www.ncbi.nlm.nih.gov/pubmed/19940831?tool=bestpractice.bmj.com>)
155. Pisani G, Cristiano K, Pupella S, et al. West Nile virus in Europe and safety of blood transfusion. *Transfus Med Hemother*. 2016 May;43(3):158-67. Full text (<https://www.ncbi.nlm.nih.gov/pmc/articles/PMC4924479>) Abstract (<http://www.ncbi.nlm.nih.gov/pubmed/27403087?tool=bestpractice.bmj.com>)

Images

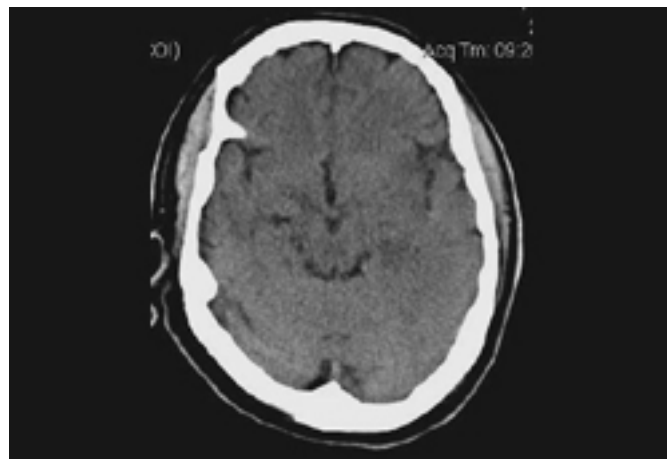


Figure 1: Noncontrast head CT of a patient with HSV encephalitis: shows subtle hypodensities involving the left insular region. Some blurring of gray-white margins and sulcal effacement over the left temporal region is discernible

From the personal collection of Catalina C. Ionita, MD; used with permission

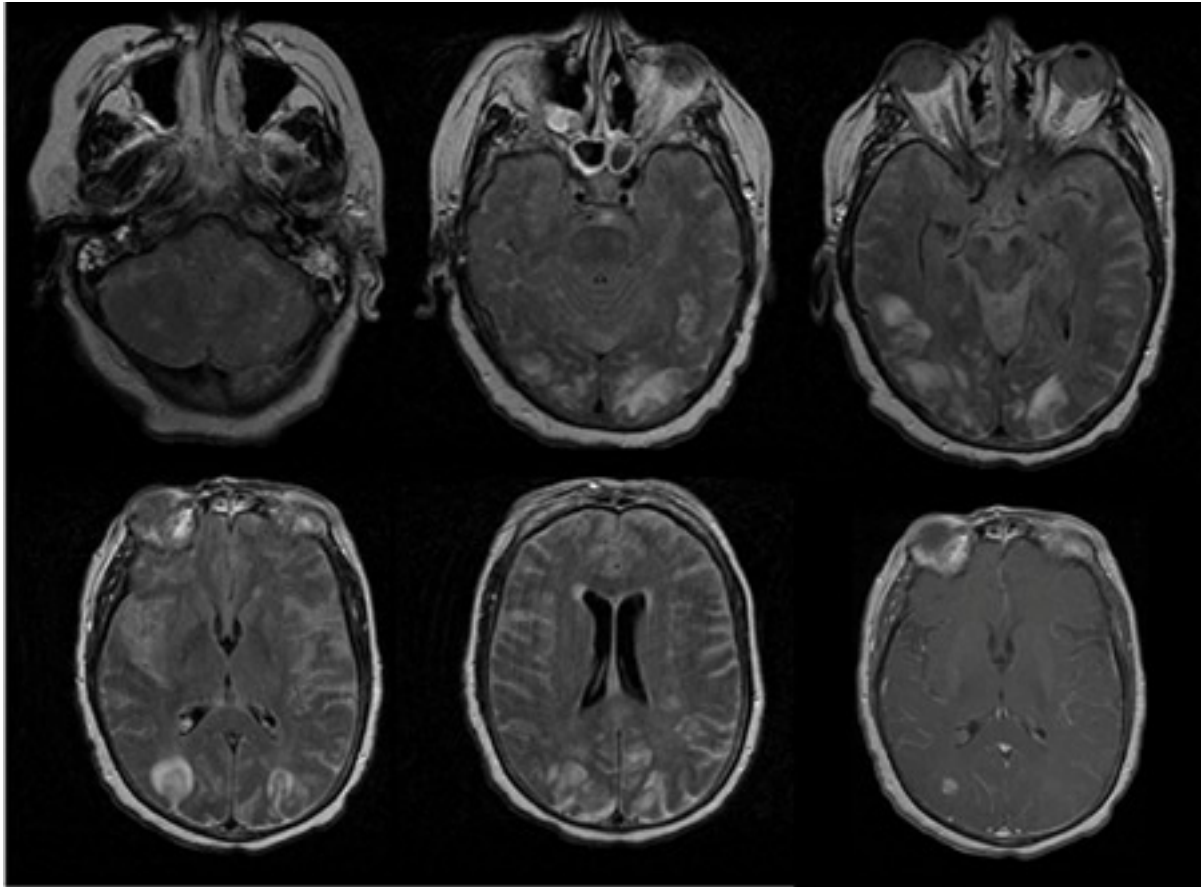


Figure 2: The first 5 images are FLAIR images of patient with varicella zoster virus meningoencephalitis showing white and gray matter hyperintensities. The last image is T1 image with contrast showing parenchymal and diffuse leptomeningeal enhancement

From the personal collection of Eric E. Kraus; used with permission

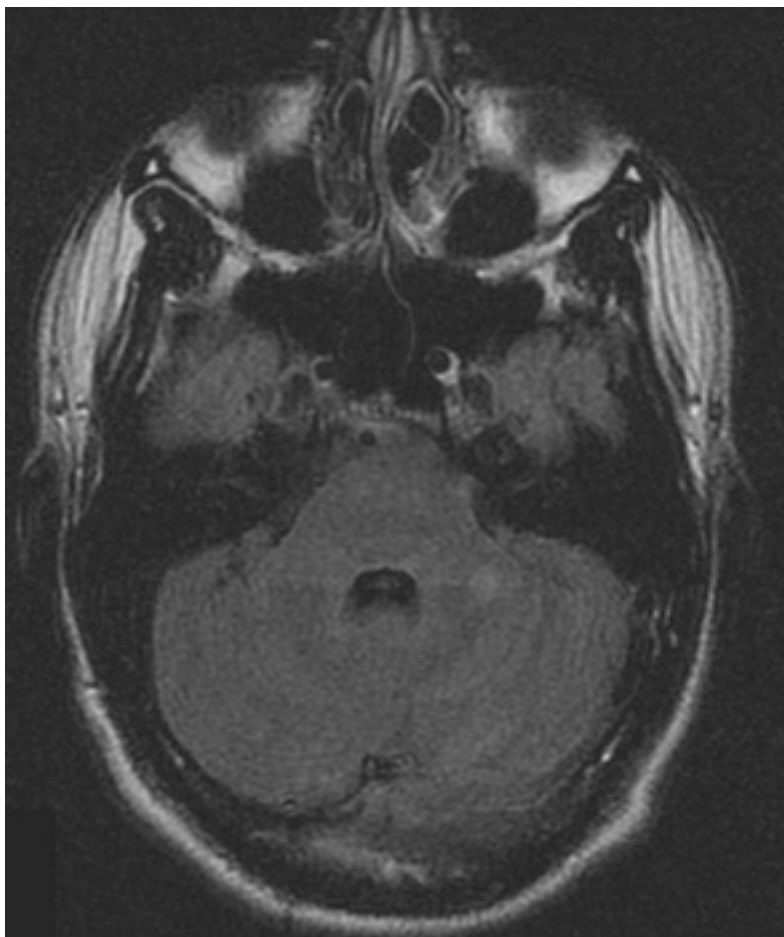


Figure 3: Series of MRI images of brain of patient with acute disseminated encephalomyelitis: hyperintense lesions of fluid attenuated inversion recovery (FLAIR) involving the left cerebellar peduncle

From the personal collection of Catalina C. Ionita, MD; used with permission

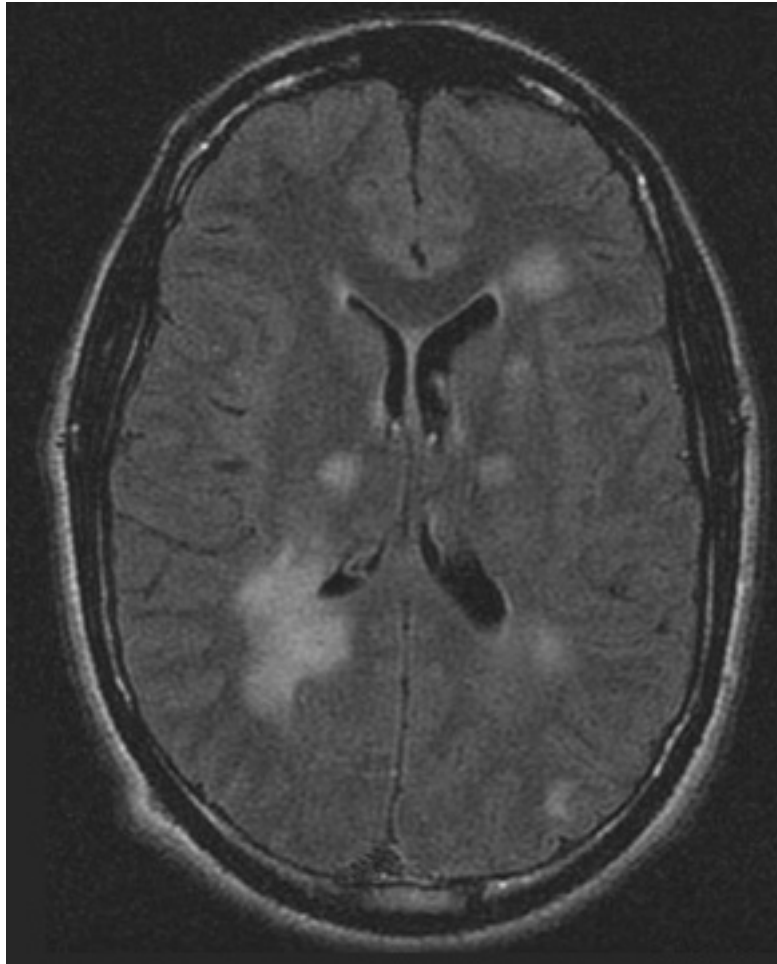


Figure 4: Series of MRI images of brain of patient with acute disseminated encephalomyelitis: asymmetric "fluffy" lesions over the bilateral ventricular horns and thalami

From the personal collection of Catalina C. Ionita, MD; used with permission

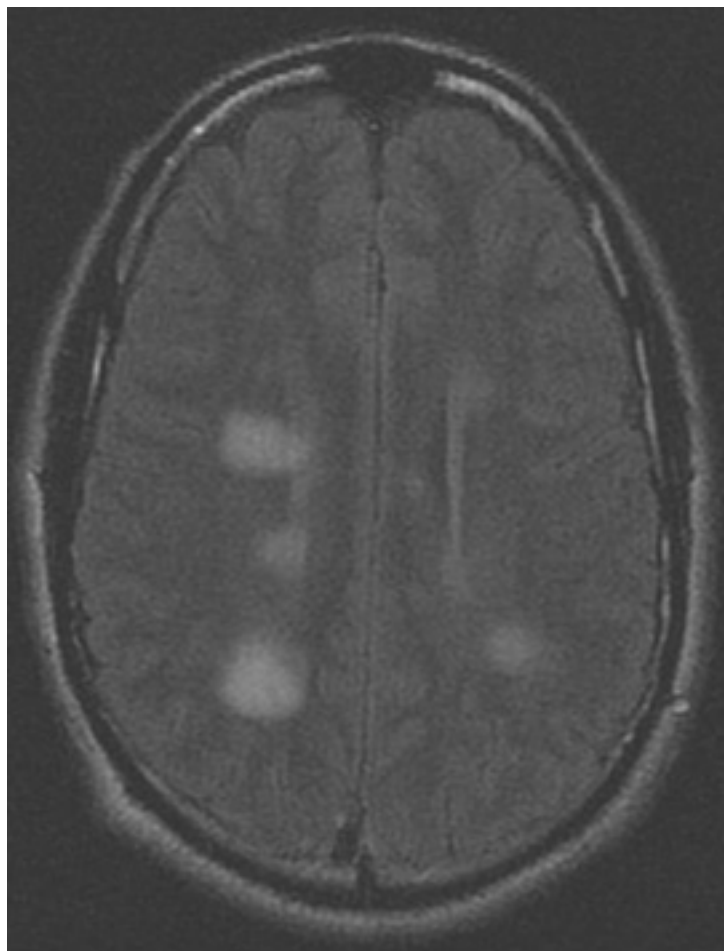


Figure 5: Series of MRI images of brain of patient with acute disseminated encephalomyelitis: periventricular regions

From the personal collection of Catalina C. Ionita, MD; used with permission

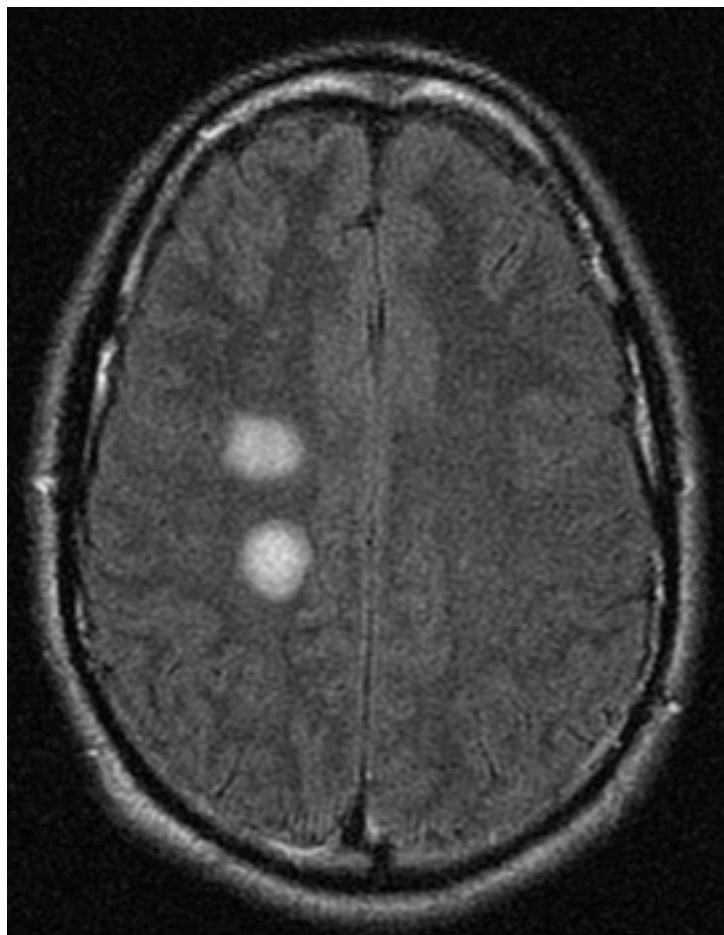


Figure 6: Series of MRI images of brain of patient with acute disseminated encephalomyelitis: centrum semiovale

From the personal collection of Catalina C. Ionita, MD; used with permission

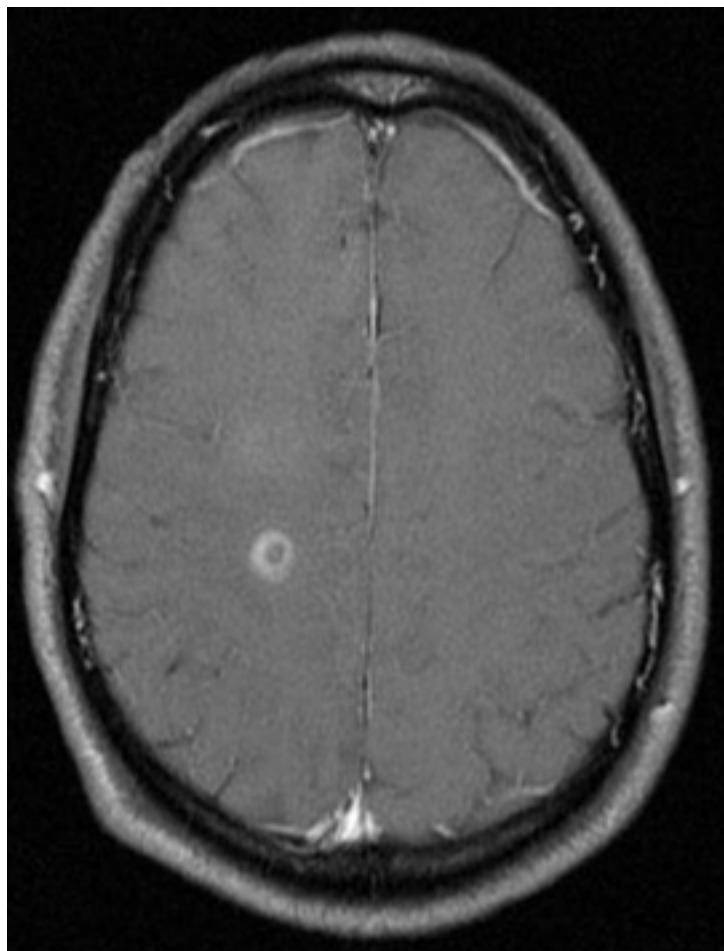


Figure 7: Series of MRI images of brain of patient with acute disseminated encephalomyelitis: T1 post-gadolinium enhanced image shows ring enhancement around a lesion in the right centrum semiovale region and faint diffuse enhancement just above this area

From the personal collection of Catalina C. Ionita, MD; used with permission

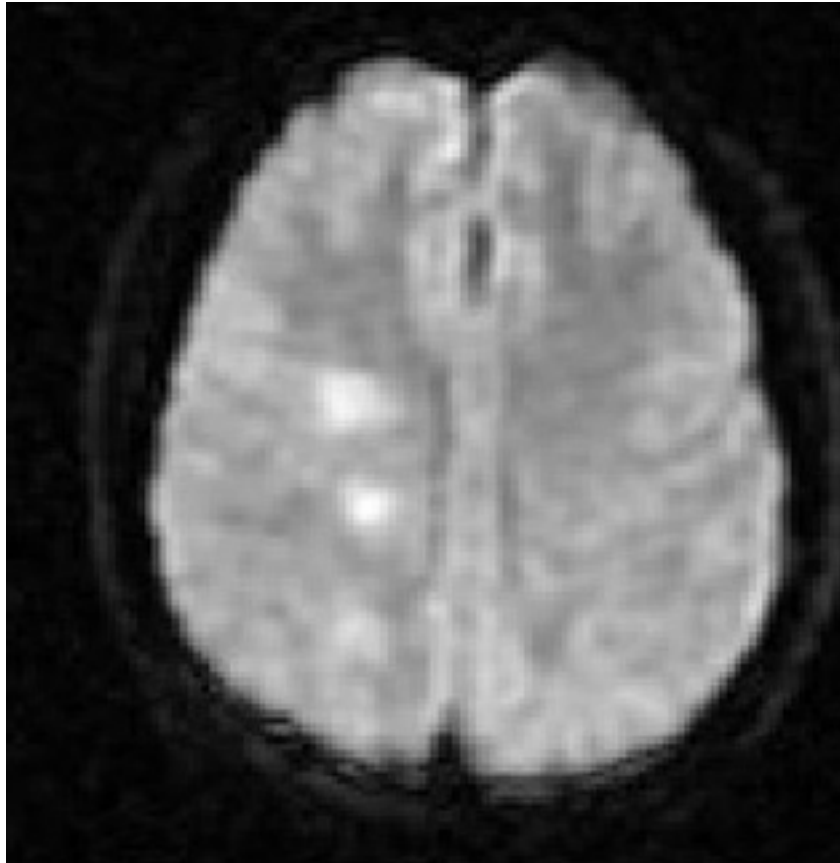


Figure 8: Series of MRI images of brain of patient with acute disseminated encephalomyelitis: diffusion-weighted image from the same patient shows high signal intensity in the same area, and this correlates with increased (bright on ADC maps) diffusion

From the personal collection of Catalina C. Ionita, MD; used with permission

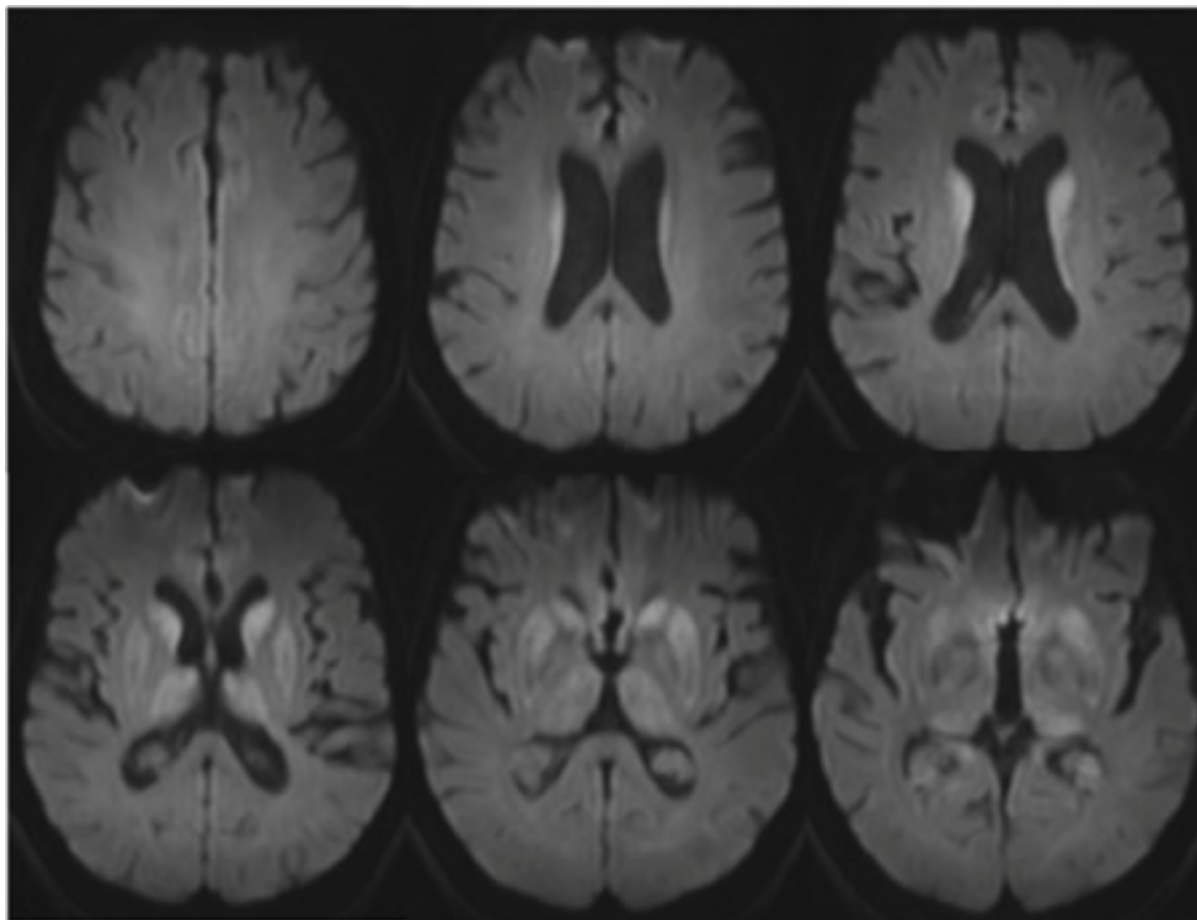


Figure 9: MRI brain: the pulvinar sign (a term referencing bilateral pulvinar hyperintensity) in a patient with Creutzfeldt-Jakob disease on diffusion-weighted images

From the personal collection of Leo H. Wang; used with permission

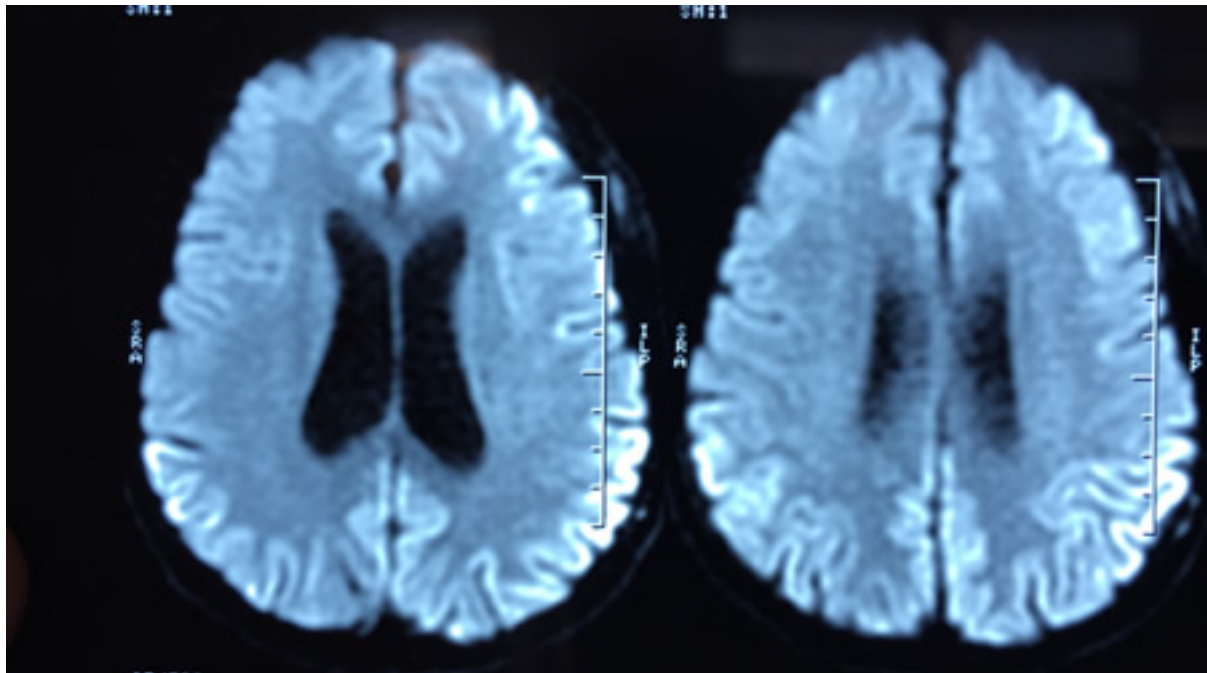


Figure 10: MRI brain: cortical ribboning in a patient with Creutzfeldt-Jakob disease on diffusion-weighted images

From the personal collection of Leo H. Wang; used with permission

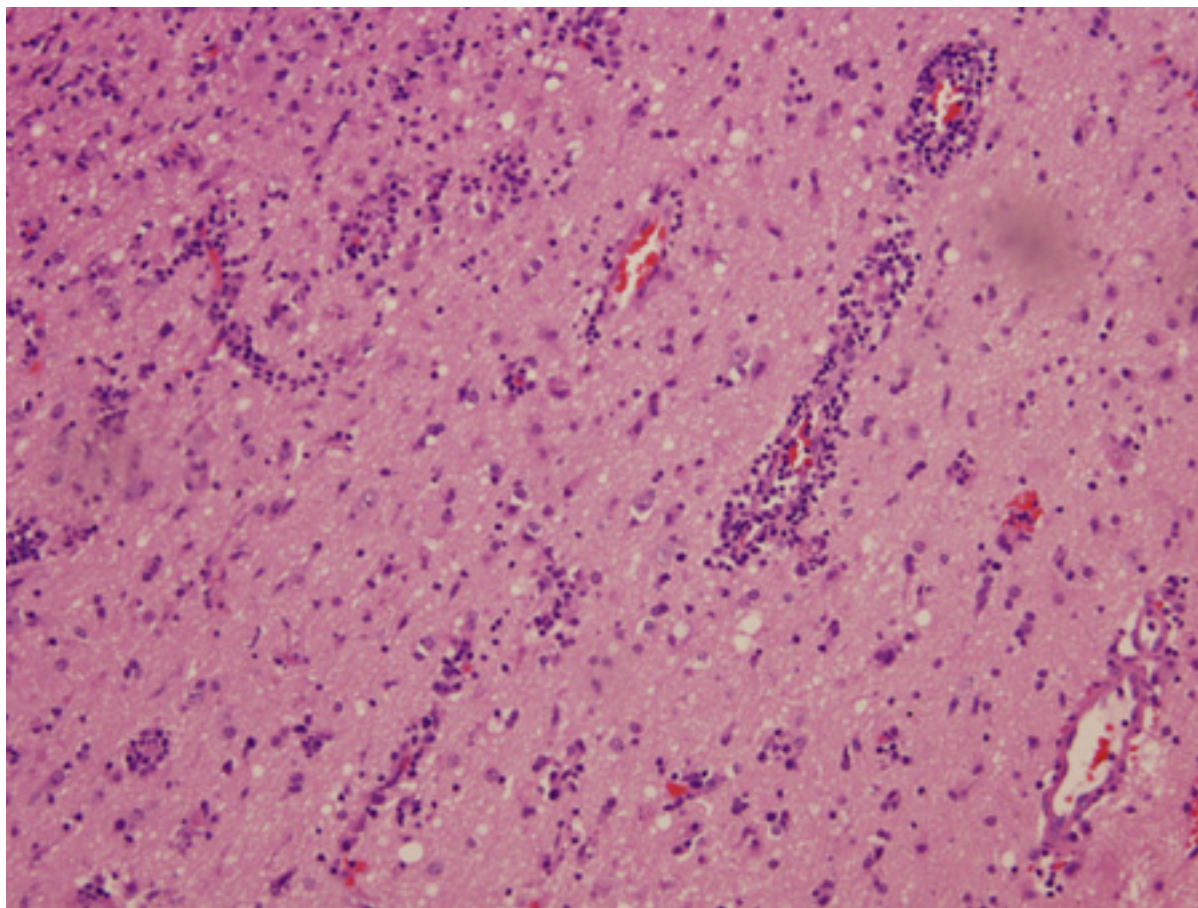


Figure 11: Biopsy of brain from right temporal lobe: the classic H&E stain shows evidence of patchy but extensive inflammatory infiltrate of small mononuclear cells (lymphocytes) in the brain parenchyma, predominantly around the blood vessel walls. PCR studies of the biopsy sample were positive for EBV infection

From the personal collection of Catalina C. Ionita, MD; used with permission

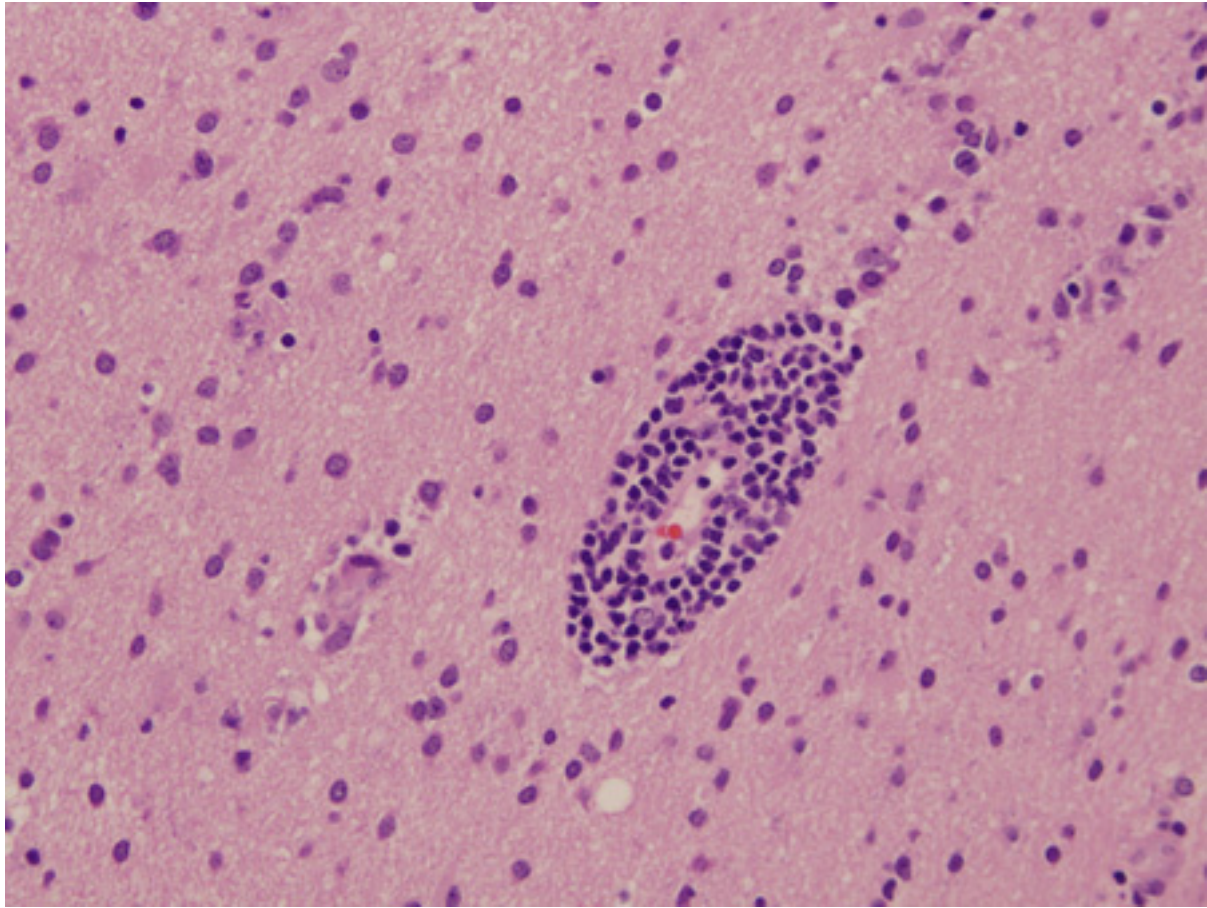


Figure 12: Biopsy of brain from right temporal lobe: a close-up view of a blood vessel with its surrounding marked inflammatory infiltrate is also seen. PCR studies of the biopsy sample were positive for EBV infection.

From the personal collection of Catalina C. Ionita, MD; used with permission

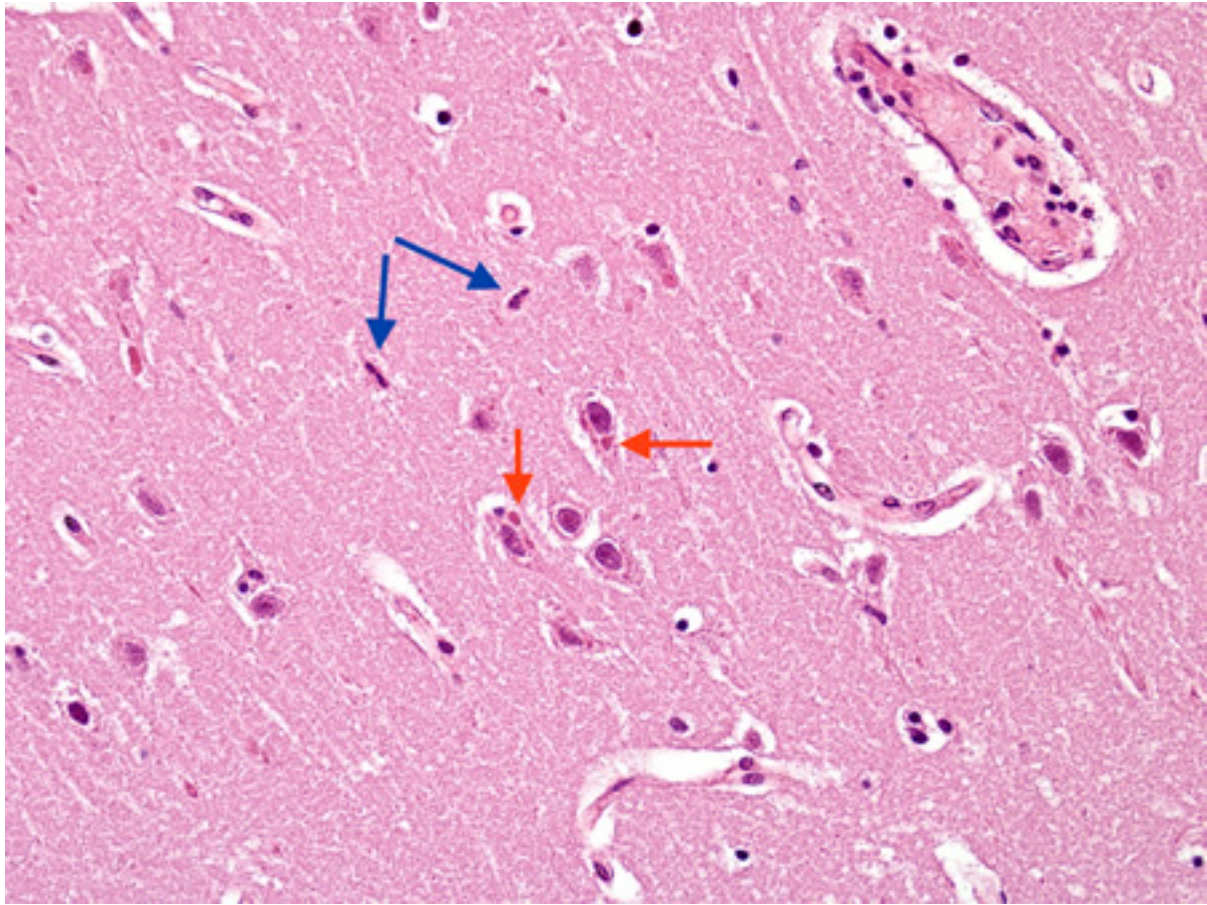


Figure 13: Biopsy from hippocampus of patient with rabies showing 2 neurons with eosinophilic Negri bodies (red arrows). These are found in areas, often with little inflammatory reaction. The blue arrows highlight microglial cells

From the personal collection of Robert E. Schmidt; used with permission

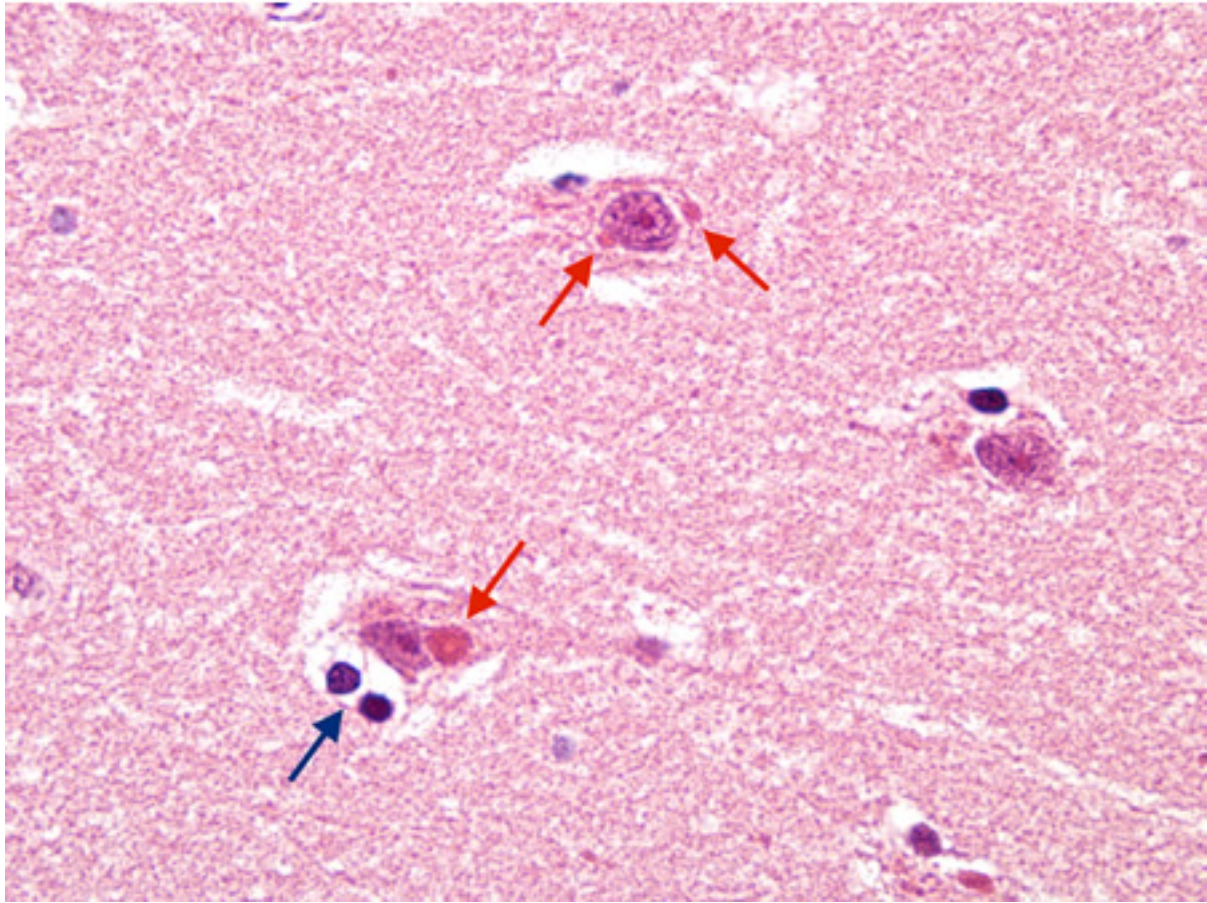


Figure 14: Biopsy from hippocampus of patient with rabies showing neurons with eosinophilic Negri bodies (red arrow). The blue arrow highlights a collection of satelliting oligodendrocytes

From the personal collection of Robert E. Schmidt; used with permission

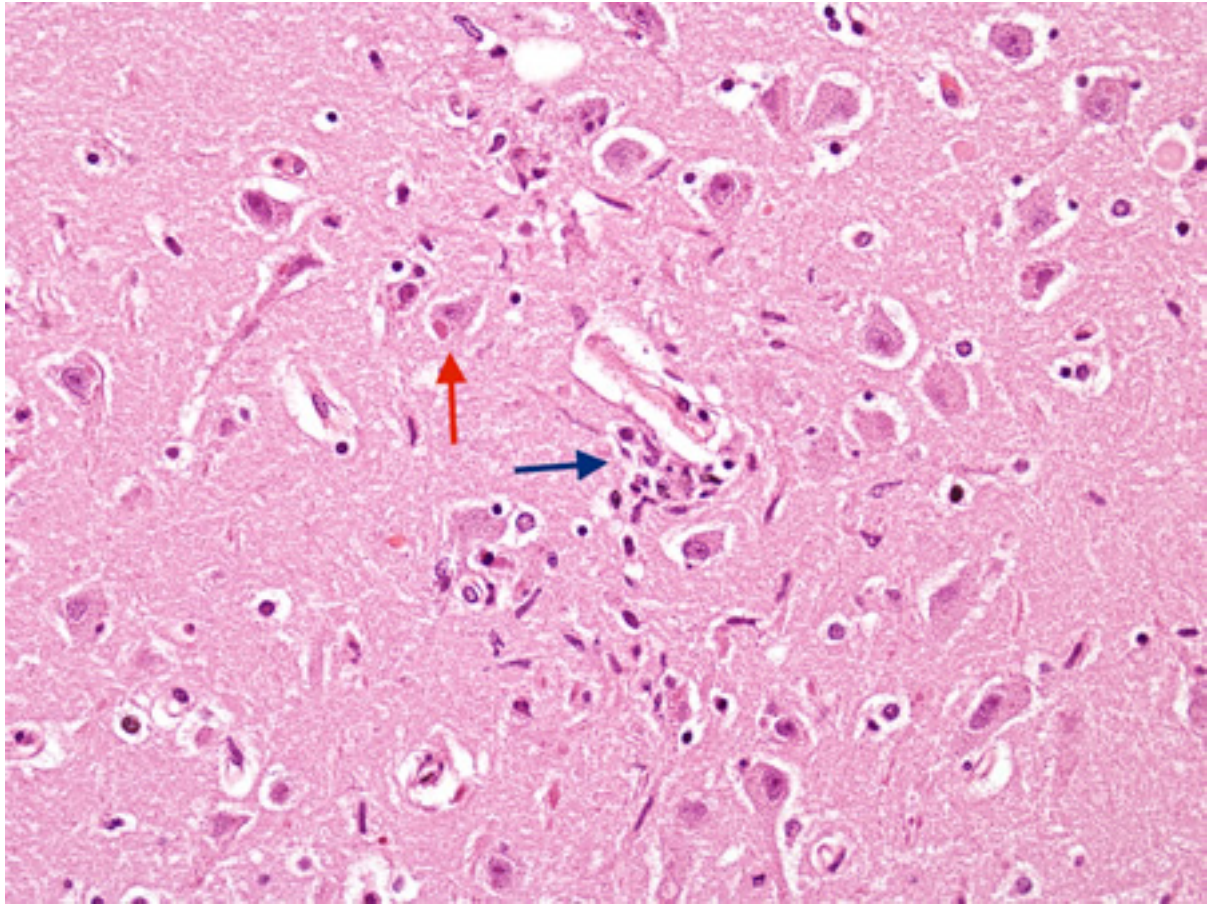


Figure 15: Biopsy from hippocampus of patient with rabies showing a neuron with an eosinophilic cytoplasmic Negri body (red arrow). The blue arrow highlights a collection of microglial cells next to a blood vessel

From the personal collection of Robert E. Schmidt; used with permission

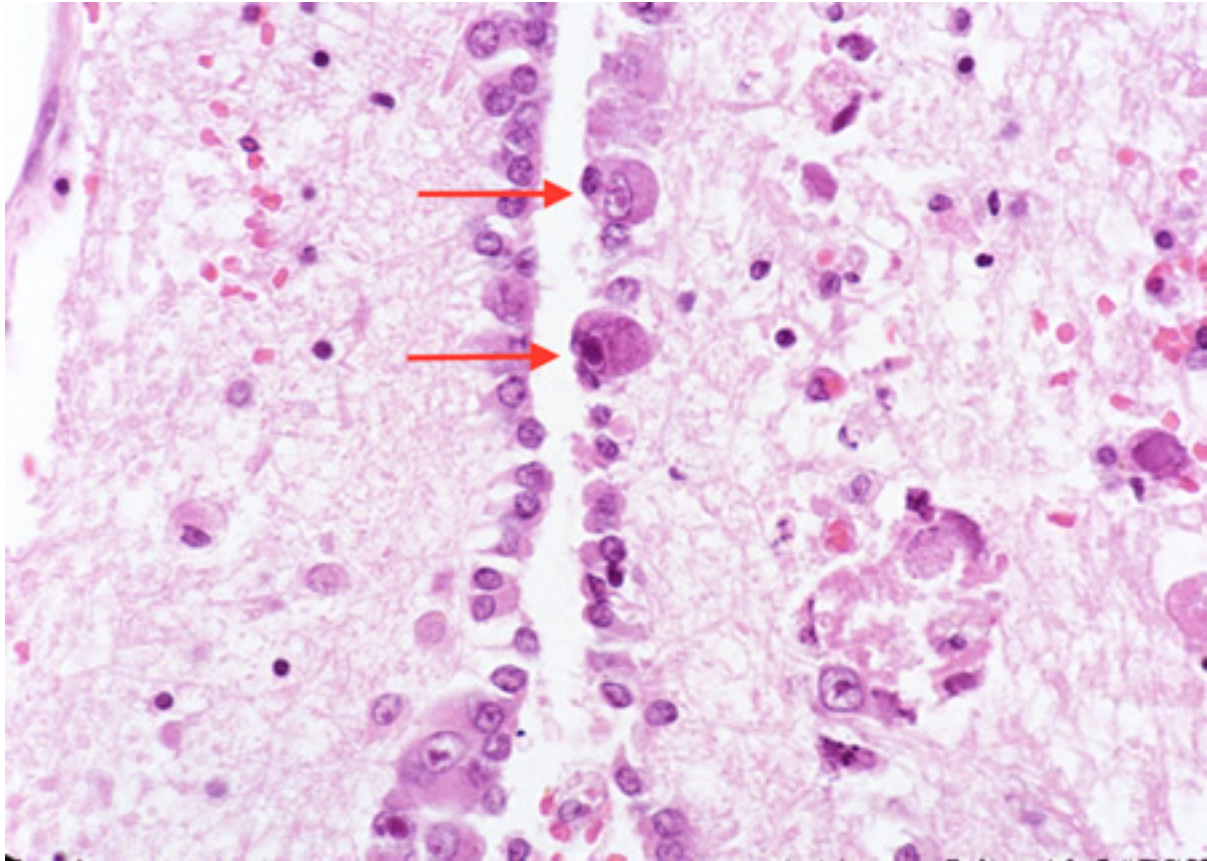


Figure 16: Biopsy from the brainstem of HIV patient with CMV encephalitis. The ependymal lining shows enlarged cells (arrows) with intranuclear inclusions

From the personal collection of Robert E. Schmidt; used with permission

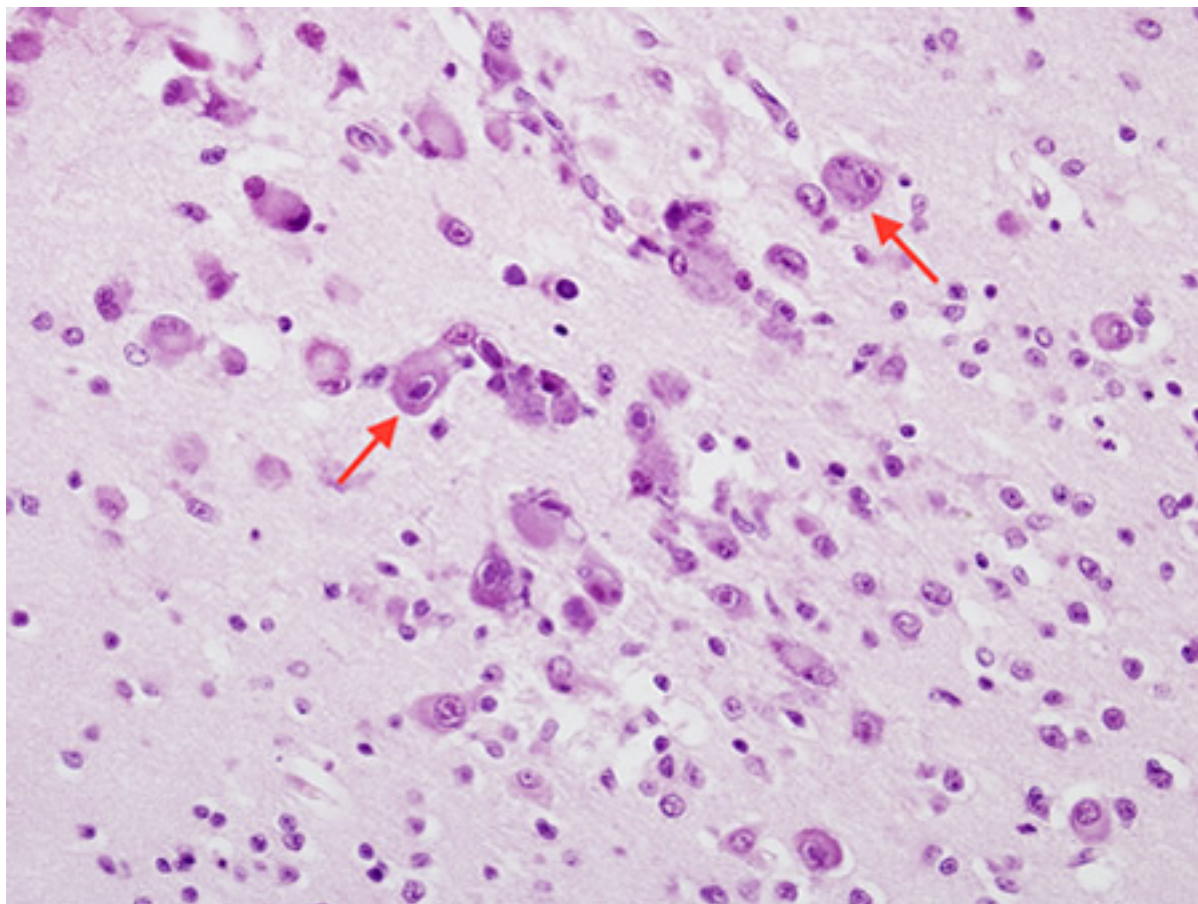


Figure 17: Biopsy from cortex of neonate with CMV encephalitis showing enlarged cells (arrows) with intranuclear inclusions. The top arrow points to a neuron with two nuclei each with a nuclear inclusion

From the personal collection of Robert E. Schmidt; used with permission

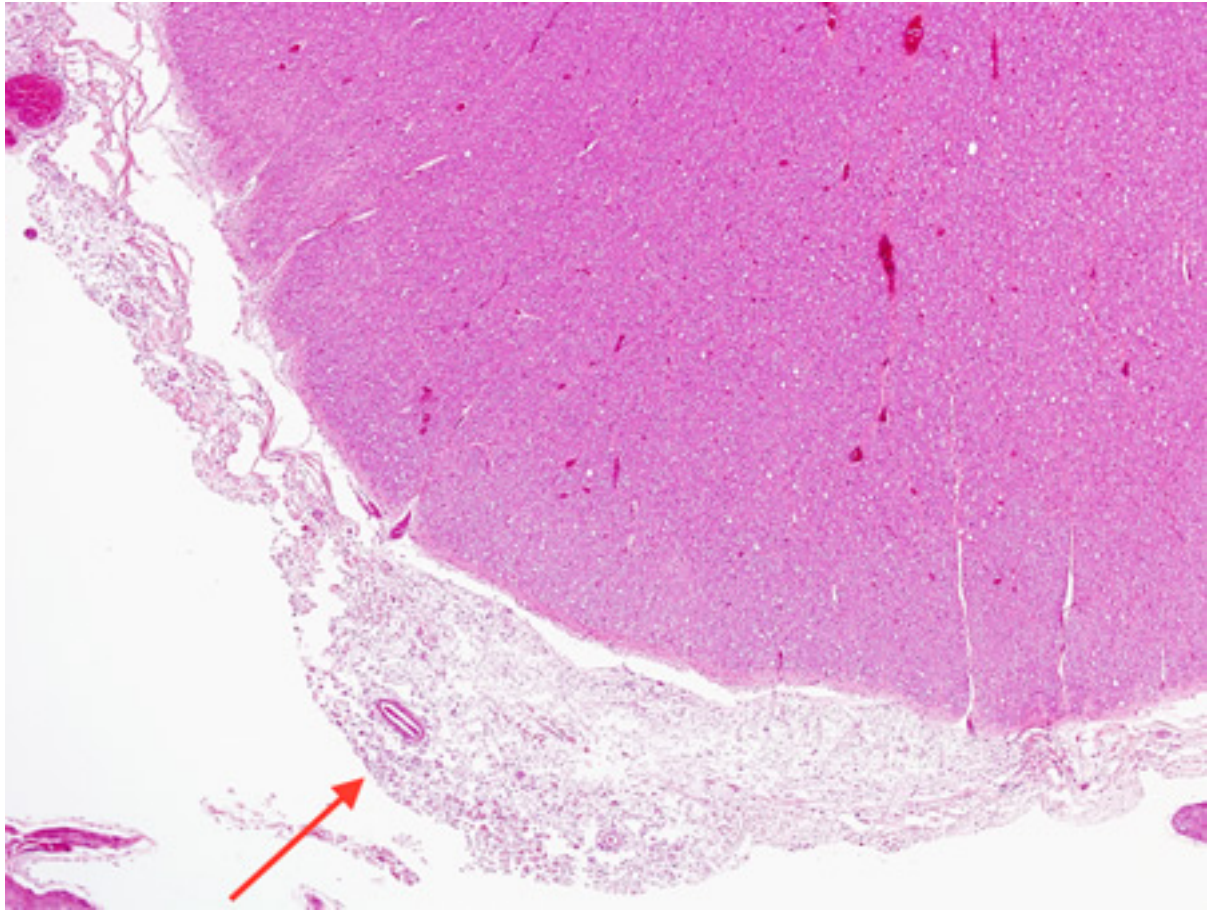


Figure 18: Biopsy from brain of immunocompromised patient with cryptococcal meningitis at low magnification. The meninges are expanded (arrow), but the cortex is histologically relatively uninvolved

From the personal collection of Robert E. Schmidt; used with permission

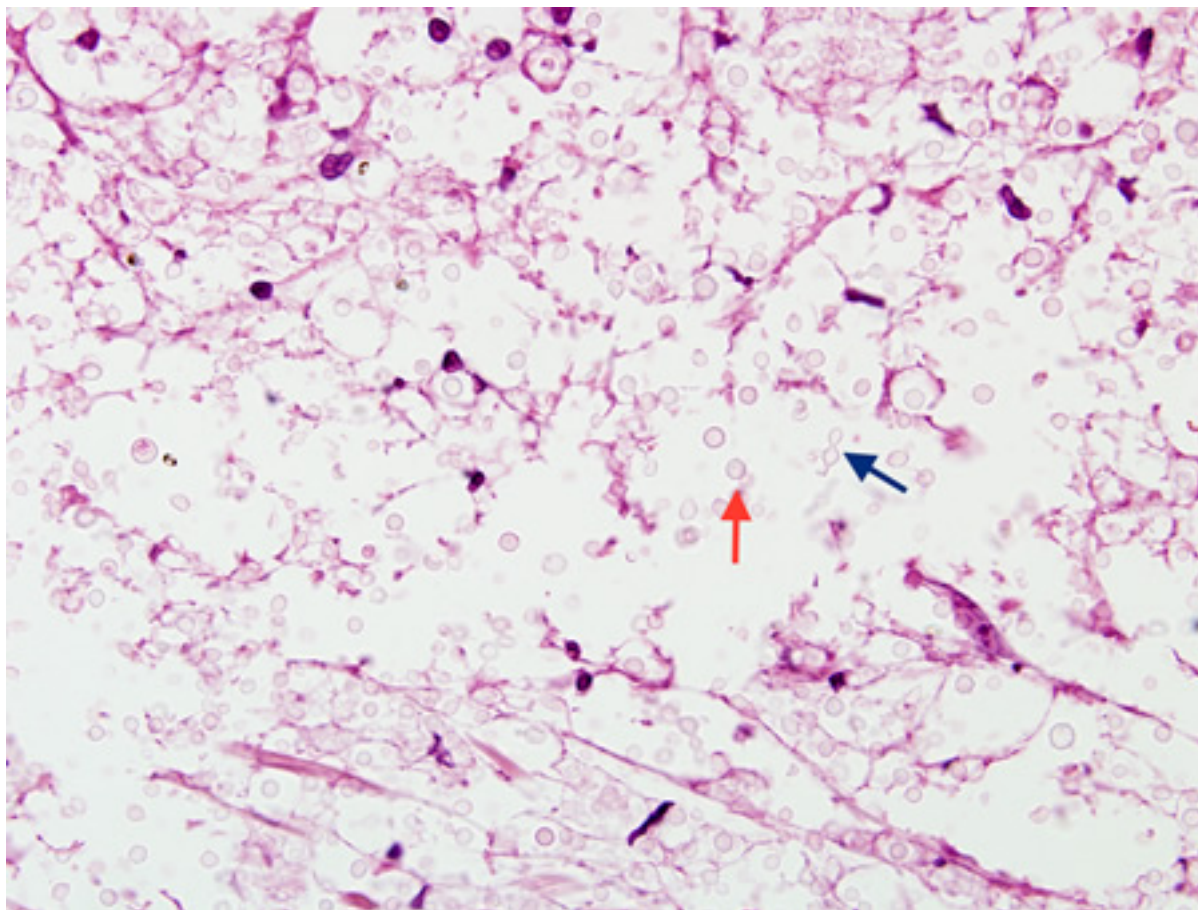


Figure 19: Biopsy from brain of immunocompromised patient with cryptococcal meningitis showing the meninges with round translucent cryptococcal organism (red arrow) as well as a budding yeast (blue arrow)

From the personal collection of Robert E. Schmidt; used with permission

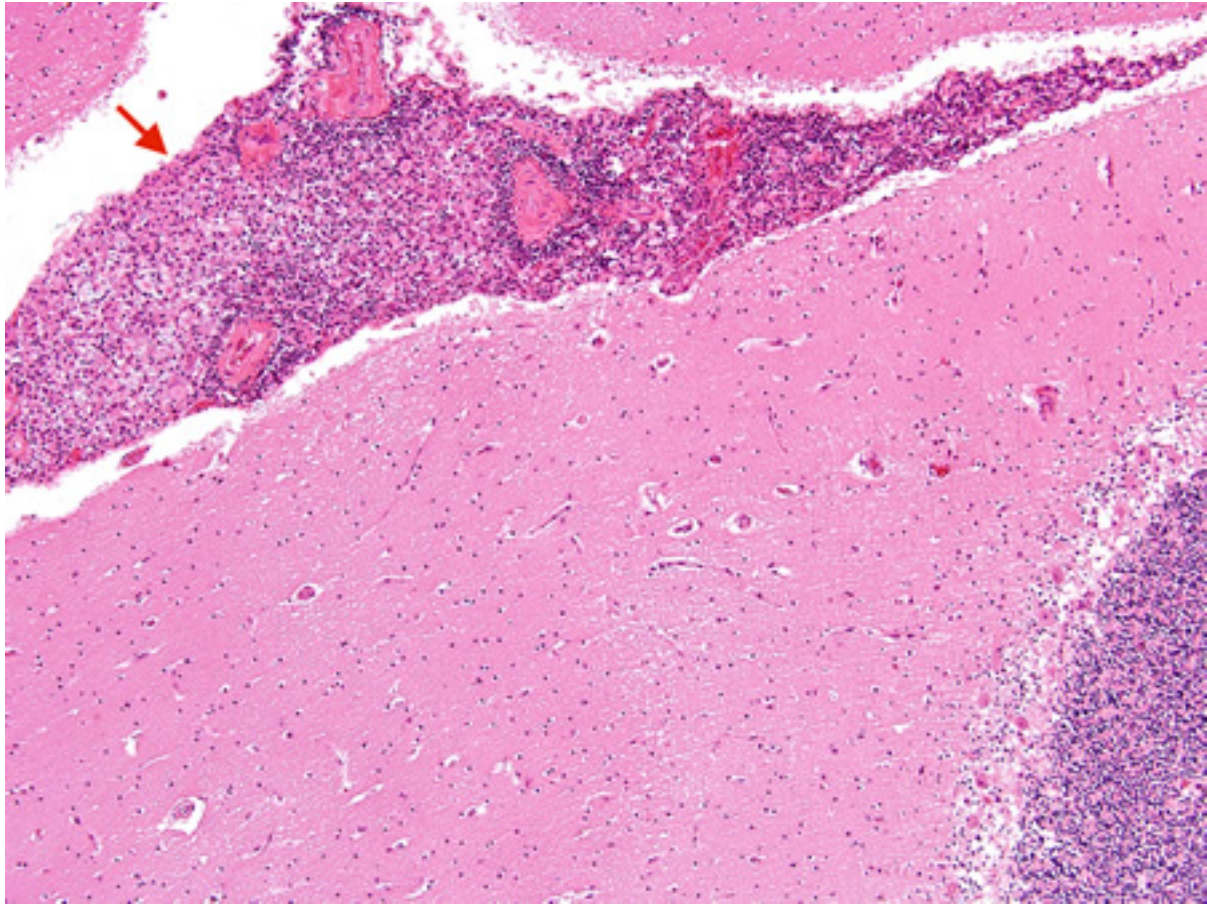


Figure 20: Biopsy from brain of an immunocompetent patient with cryptococcal meningitis at low magnification showing the meninges with inflammation (red arrow)

From the personal collection of Robert E. Schmidt; used with permission

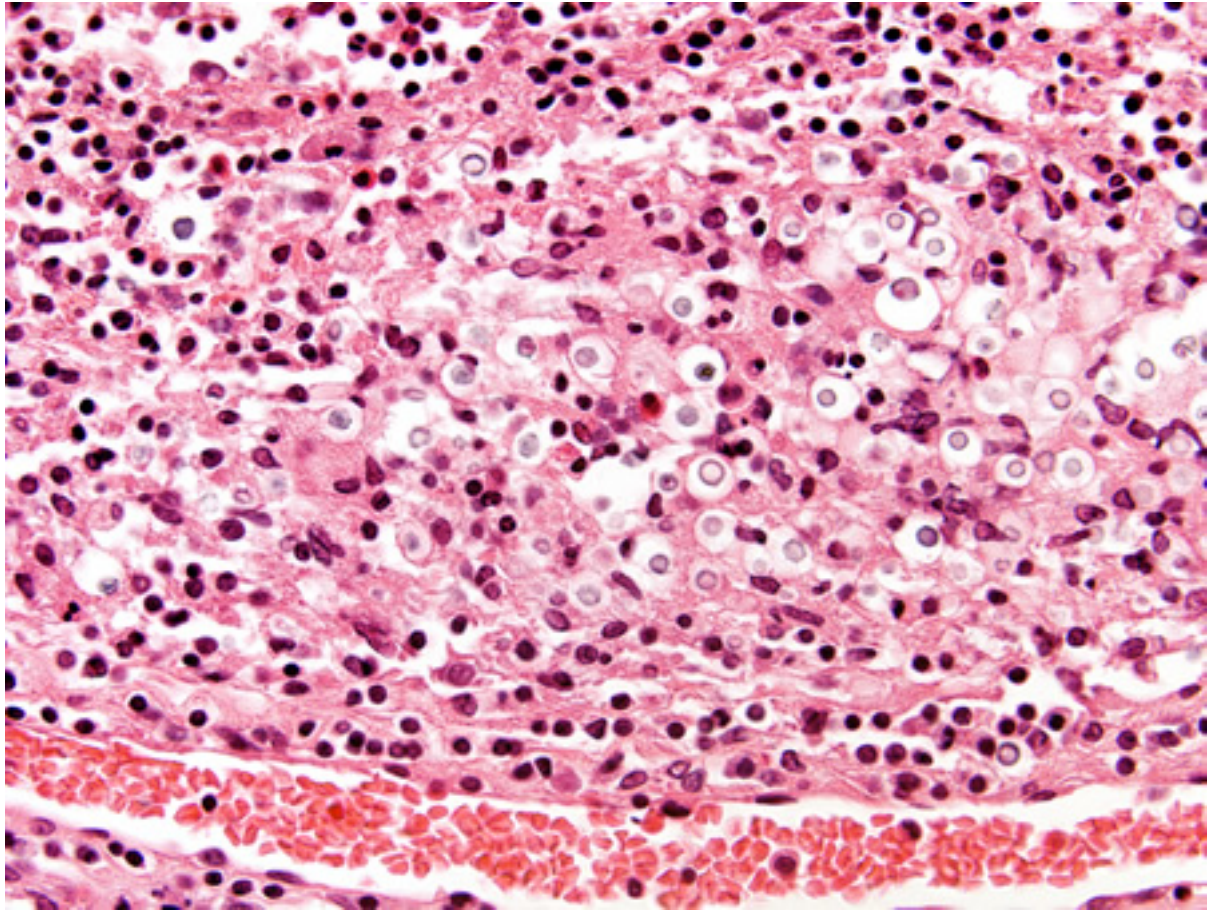


Figure 21: Biopsy from brain of immunocompetent patient with cryptococcal meningitis showing the meninges with inflammatory cells and Cryptococcus

From the personal collection of Robert E. Schmidt; used with permission

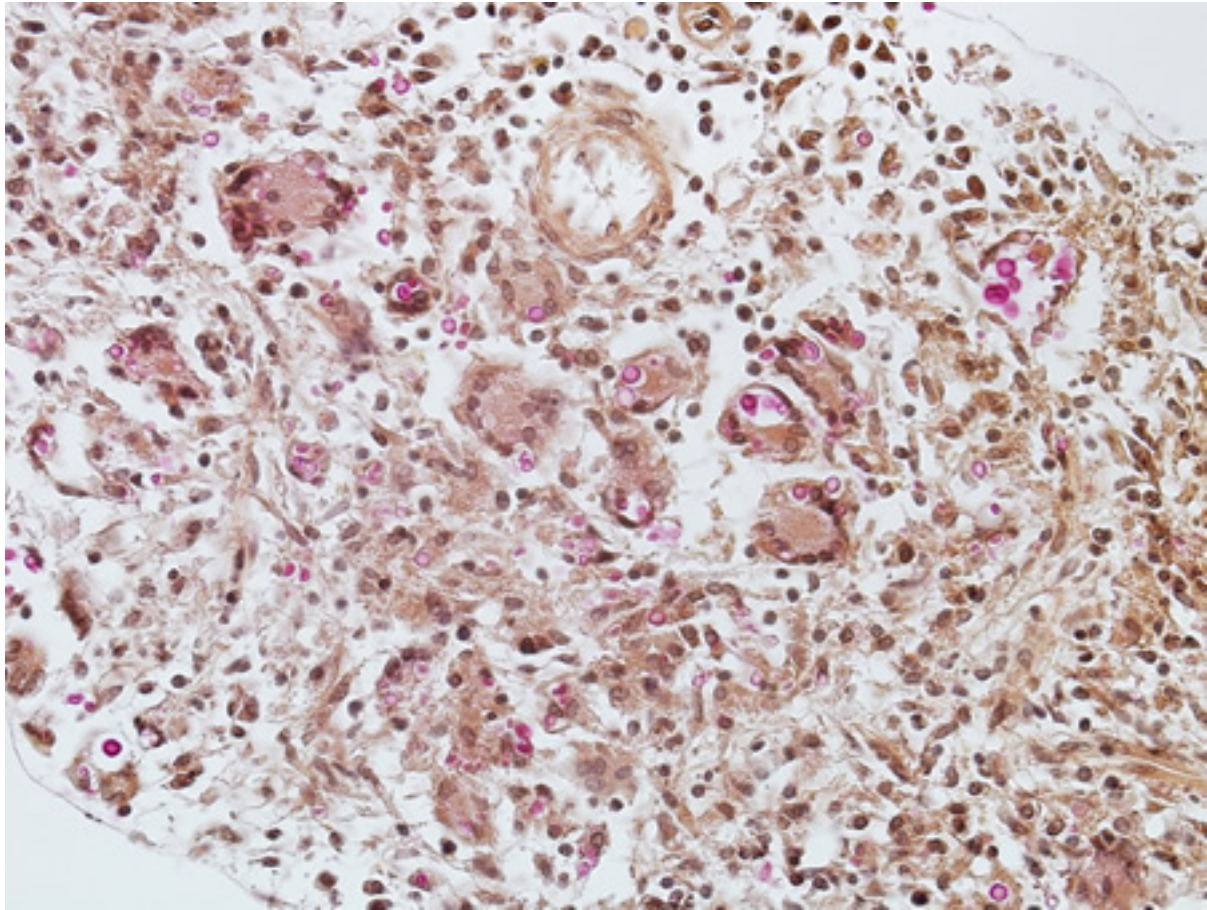


Figure 22: Biopsy from meninges of patient with cryptococcal meningitis stained with mucicarmine, demonstrating fungal organisms, particularly in giant cells

From the personal collection of Robert E. Schmidt; used with permission

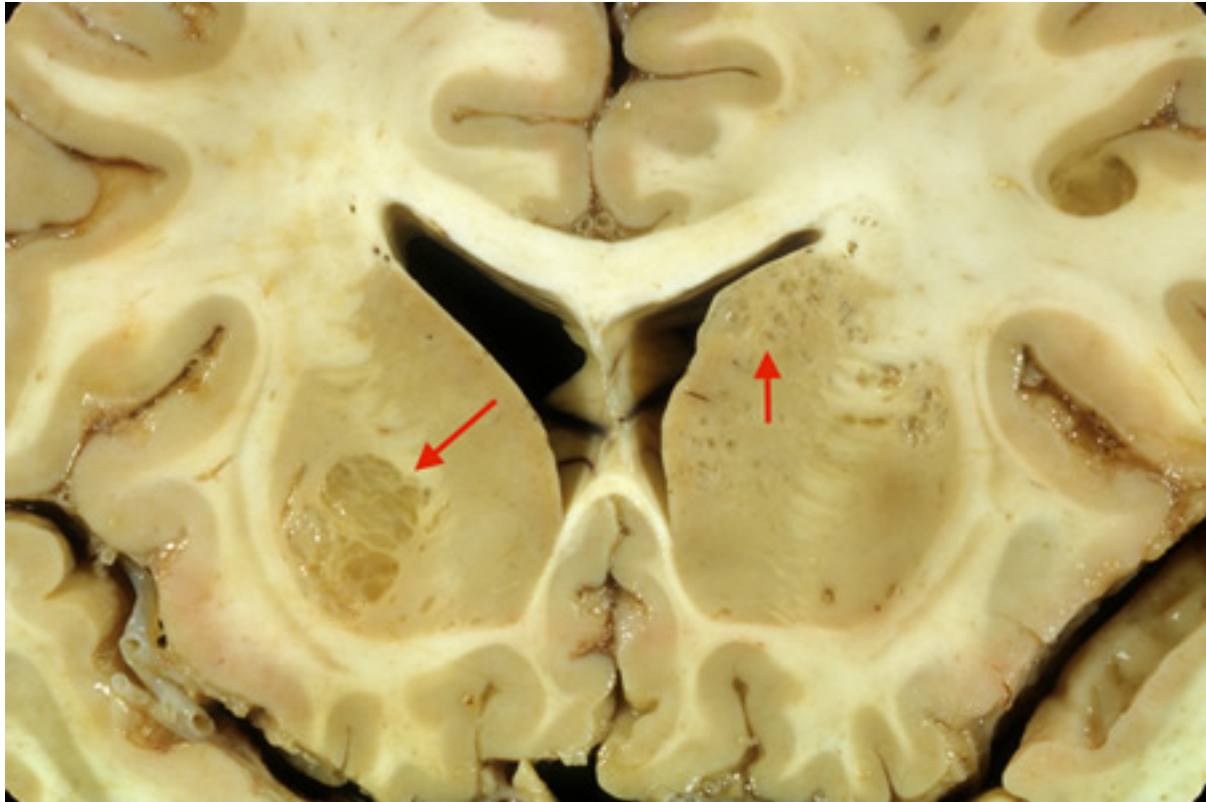


Figure 23: Coronal slice of the brain of patient with cryptococcal meningoencephalitis showing classical appearance of “soap bubble” structures in the basal ganglia (arrows) resulting from the cryptococcal expansion of Virchow-Robin spaces around the lenticulostriate vessels

From the personal collection of Robert E. Schmidt; used with permission

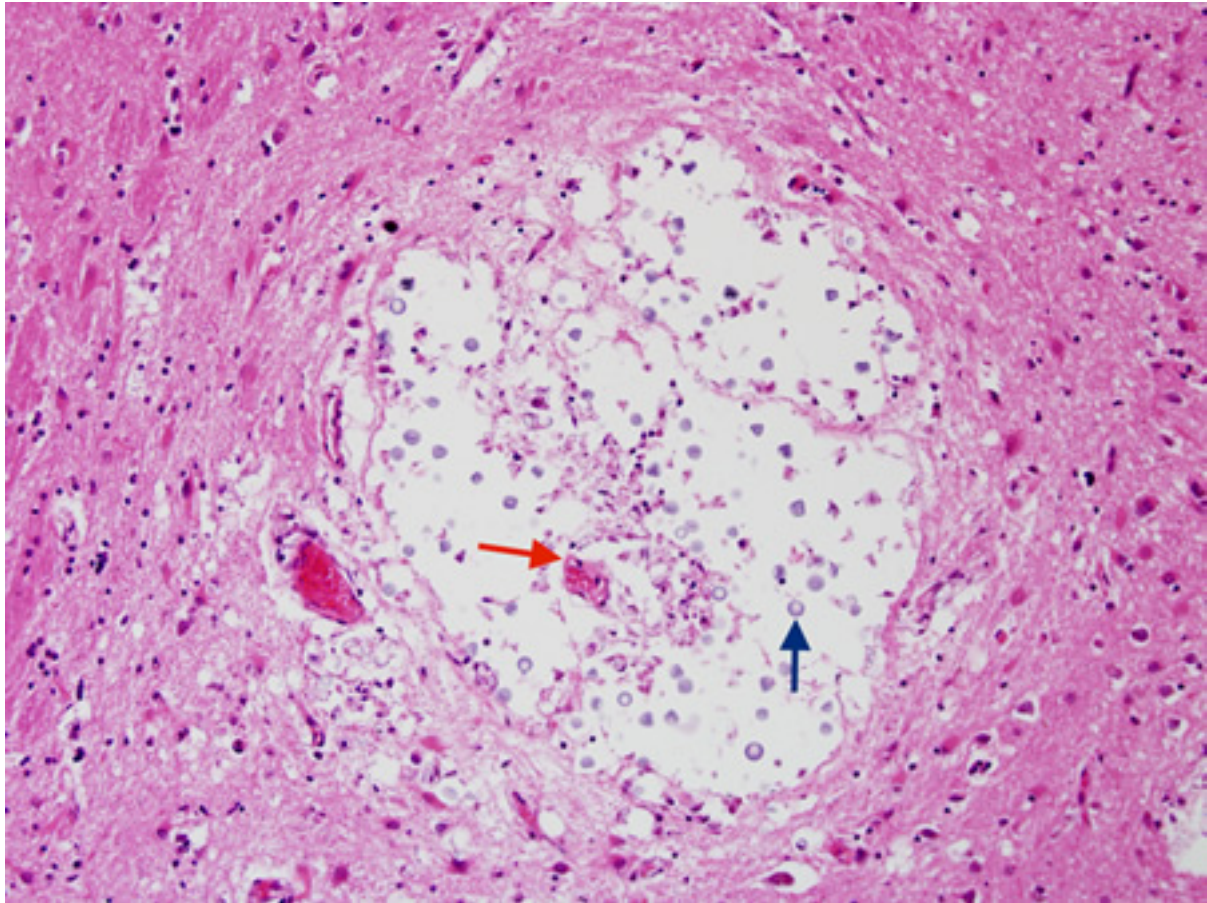


Figure 24: Biopsy from basal ganglia of patient with cryptococcal meningoencephalitis showing cryptococcal (blue arrow) expansion of Virchow-Robbin spaces around a lenticulostriate vessel (red arrow)

From the personal collection of Robert E. Schmidt; used with permission

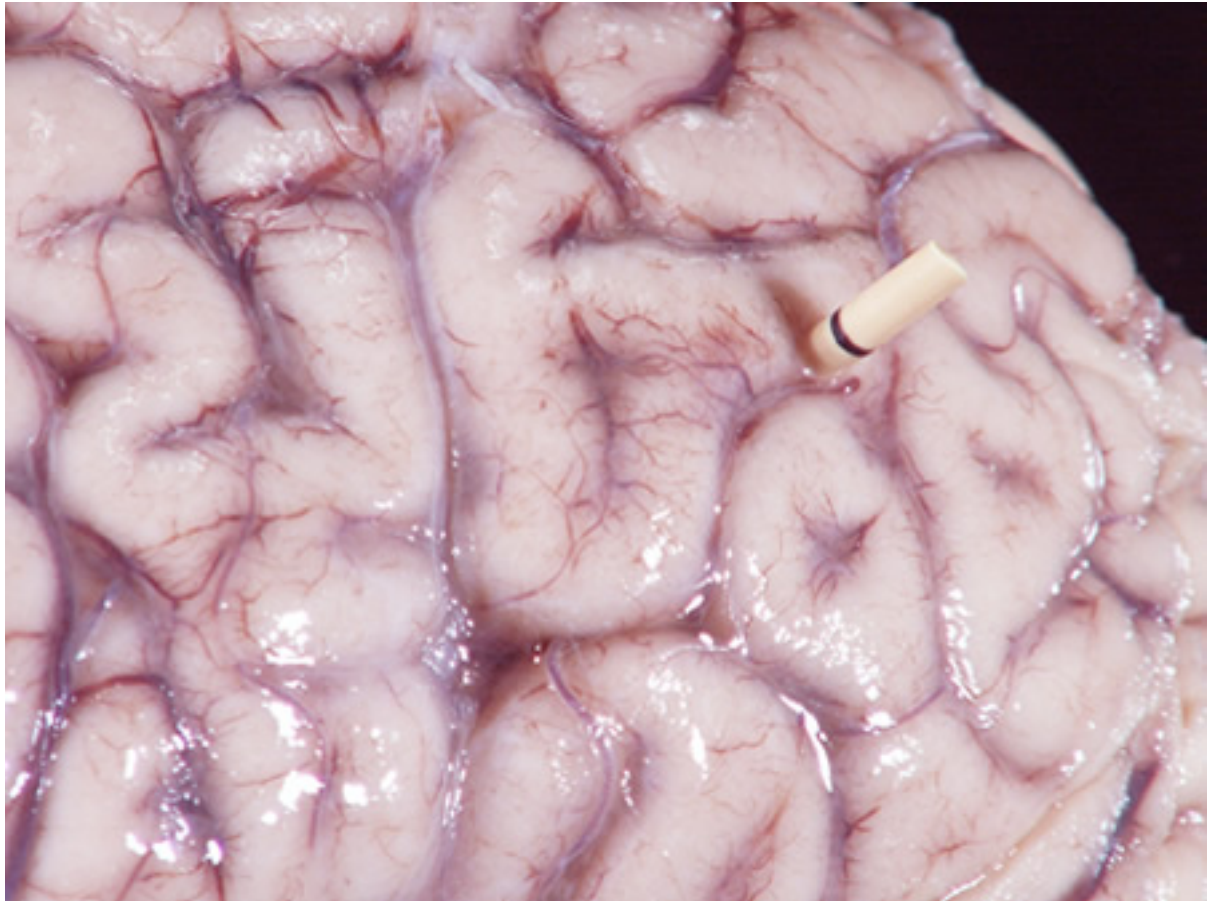

Figure 25: Gross autopsy of brain of patient with cryptococcal meningitis showing the surface with a "glazed" look. There is also a shunt present

From the personal collection of Robert E. Schmidt; used with permission

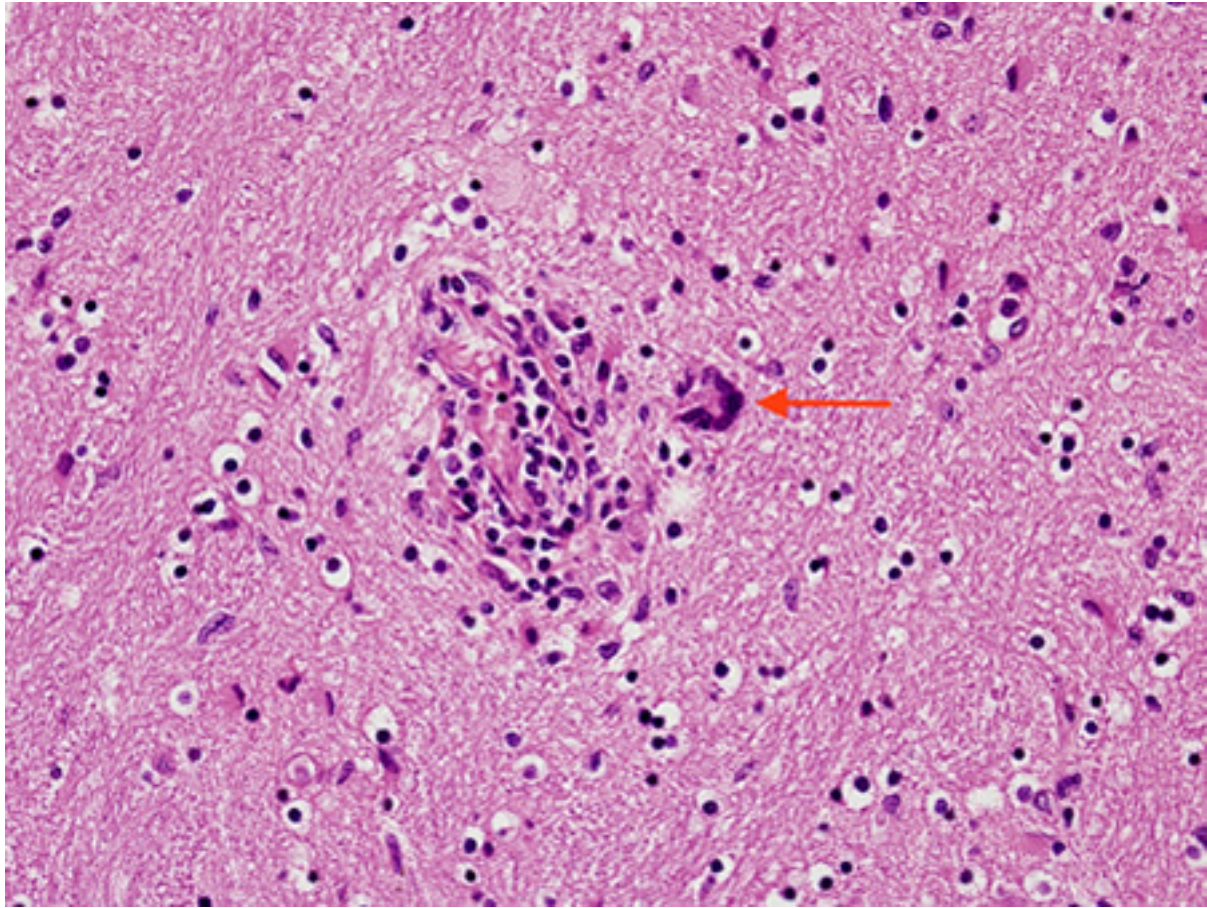


Figure 26: Biopsy from brain of patient with subacute HIV leukoencephalitis showing the distinctive multinucleated cell (red arrow) in the white matter next to inflammatory cells in the Virchow-Robin space

From the personal collection of Robert E. Schmidt; used with permission

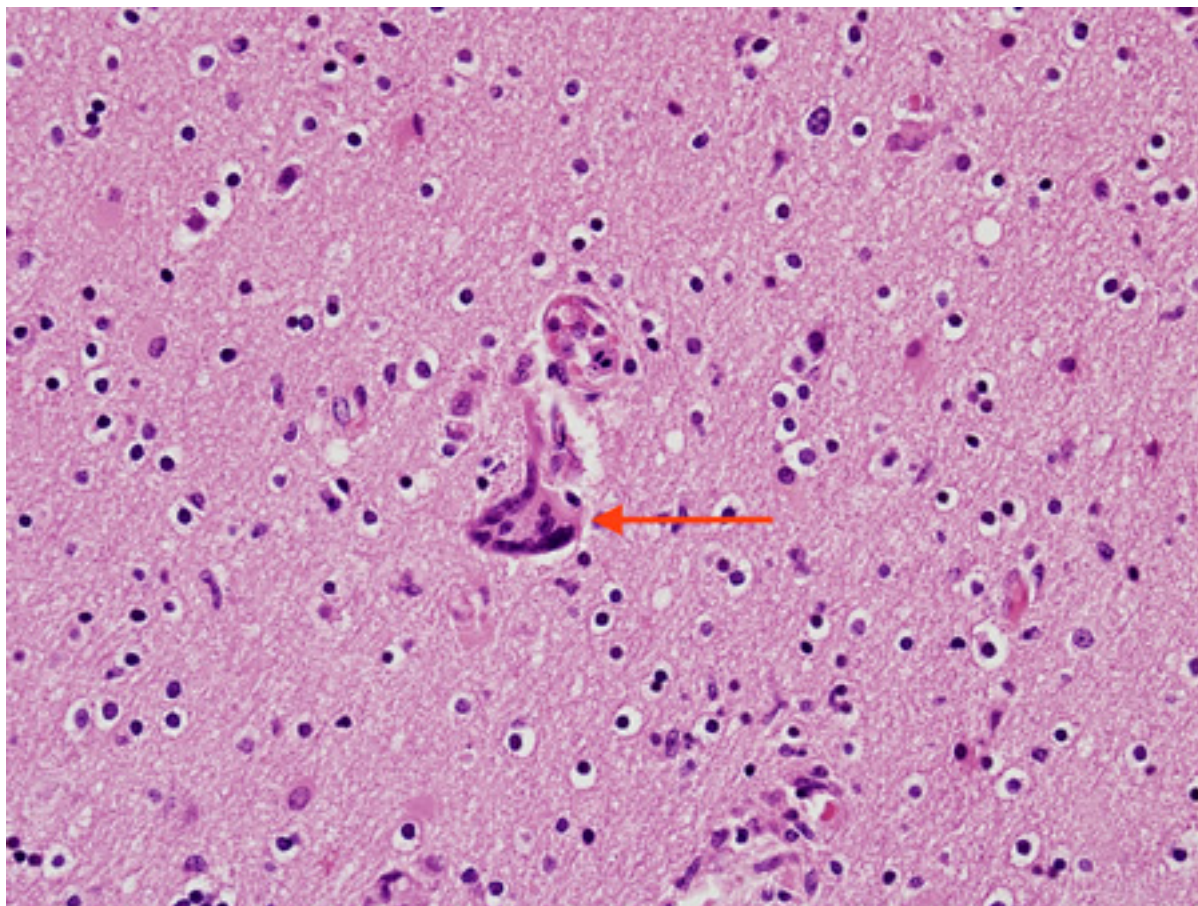


Figure 27: Biopsy from brain of patient with subacute HIV leukoencephalitis showing the distinctive multinucleated cell (red arrow) in the white matter

From the personal collection of Robert E. Schmidt; used with permission

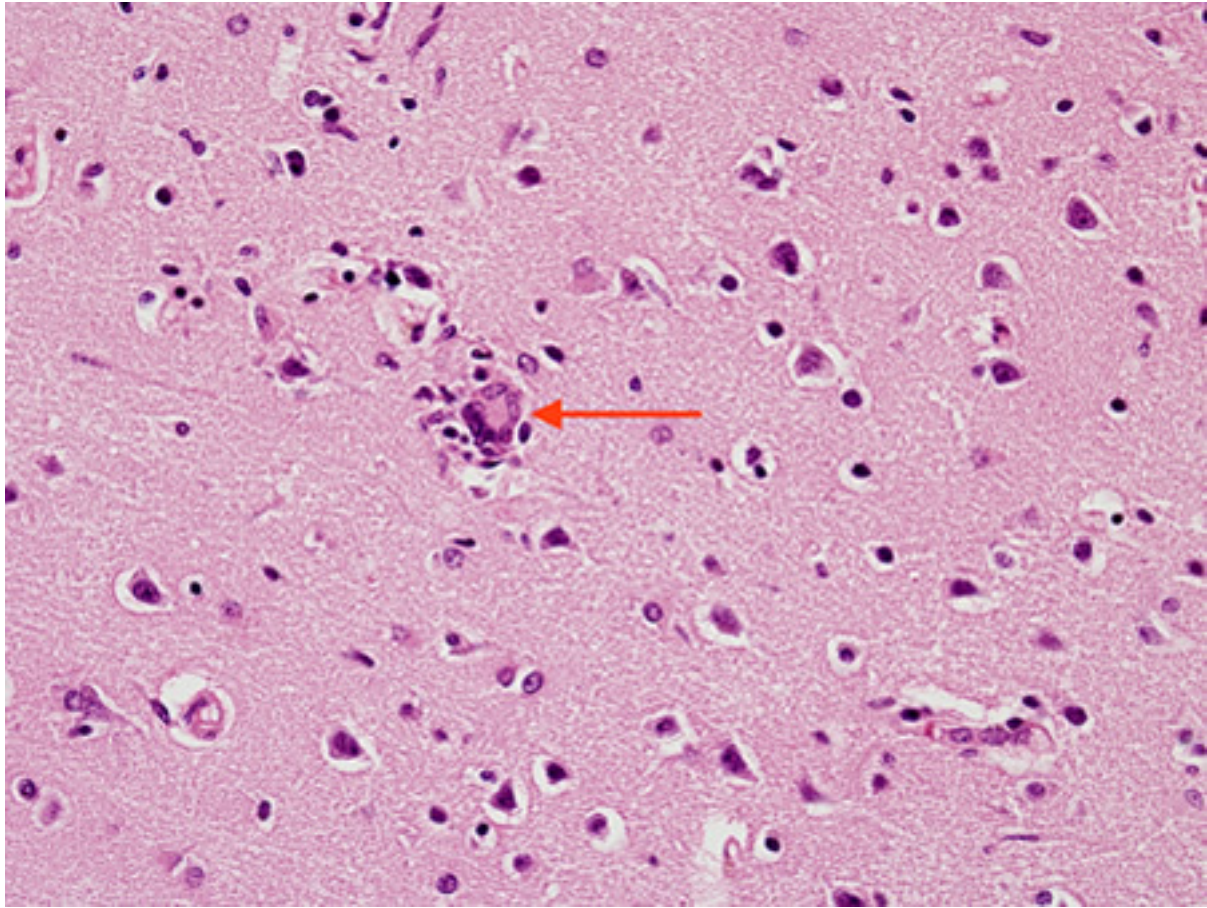


Figure 28: Biopsy from brain of patient with subacute HIV encephalitis showing the distinctive multinucleated giant cell (red arrow), which contains the HIV virus. The multinucleated giant cells are from histiocyte/macrophage lineage. There is also associated astrocytosis

From the personal collection of Robert E. Schmidt; used with permission

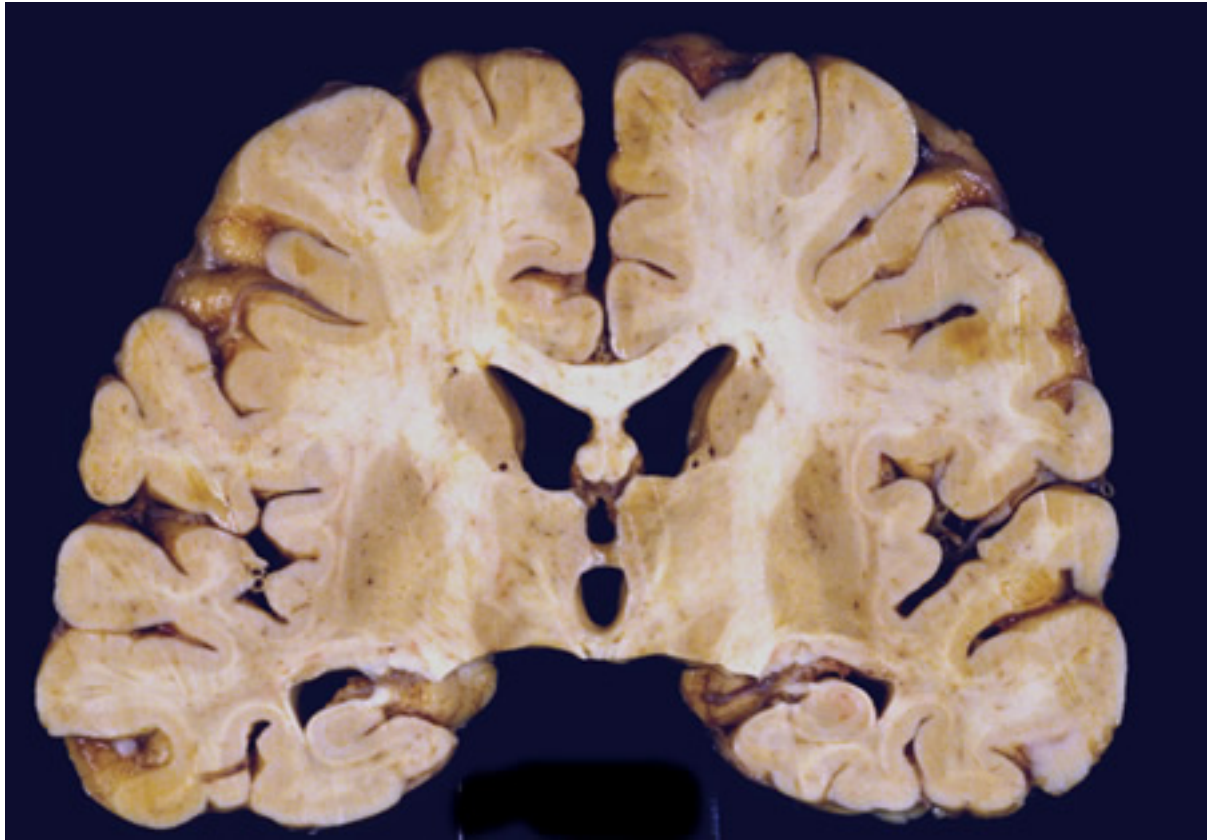


Figure 29: Coronal slice of the brain of HIV patient in his 30s. He had subacute HIV encephalitis involving both the white matter and gray matter diffusely. The ventricles were enlarged reflecting white matter and cortical loss

From the personal collection of Robert E. Schmidt; used with permission

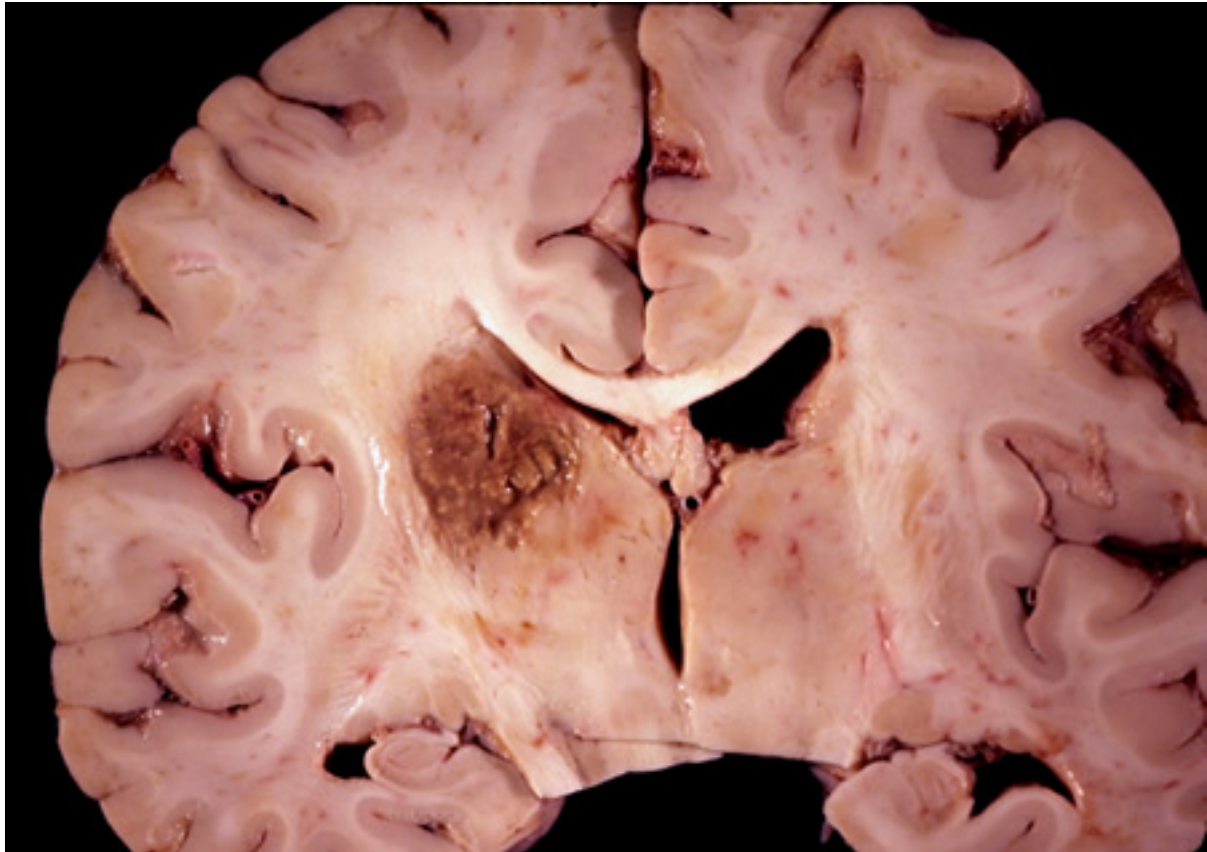


Figure 30: Coronal slice of the brain of HIV patient with toxoplasmosis, showing infection of the periventricular superior part of the left thalamus

From the personal collection of Robert E. Schmidt; used with permission

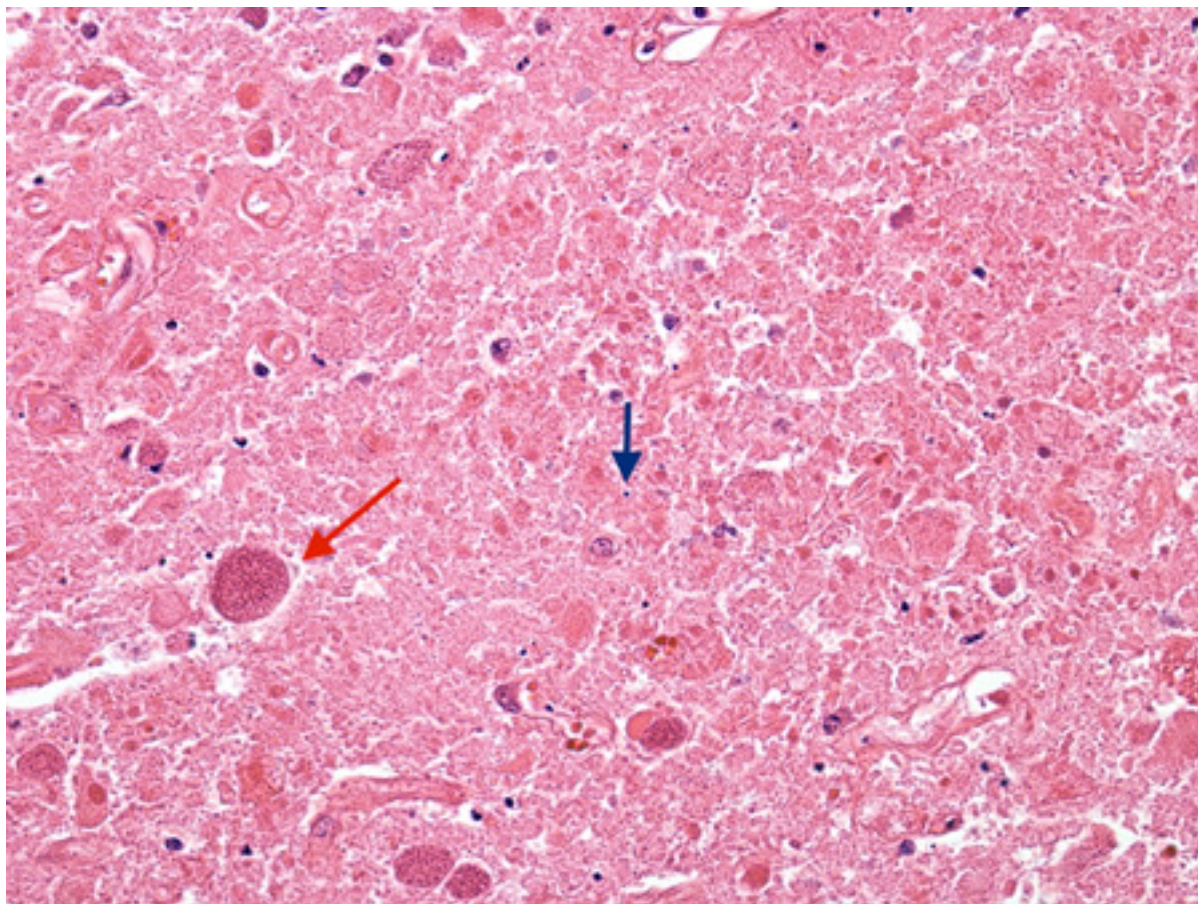


Figure 31: Biopsy of the brain of an HIV patient with toxoplasmosis, showing encysted bradyzoites (red arrow) and tachyzoites (blue arrow)

From the personal collection of Robert E. Schmidt; used with permission

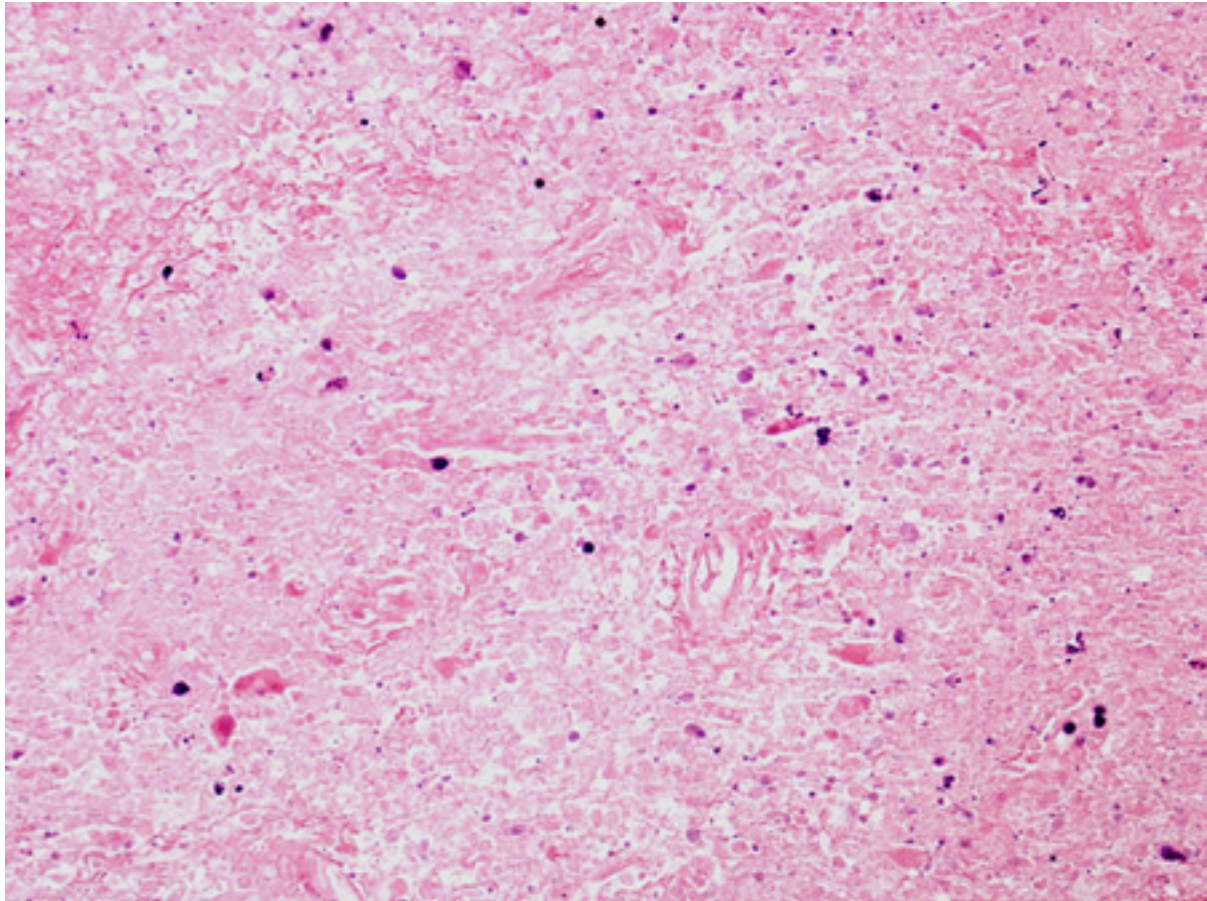


Figure 32: Biopsy of HIV patient with toxoplasmosis, showing both pieces of cellular debris and tachyzoites. The tachyzoites are round, smooth, and hard to identify without antibody staining (see next image)

From the personal collection of Robert E. Schmidt; used with permission

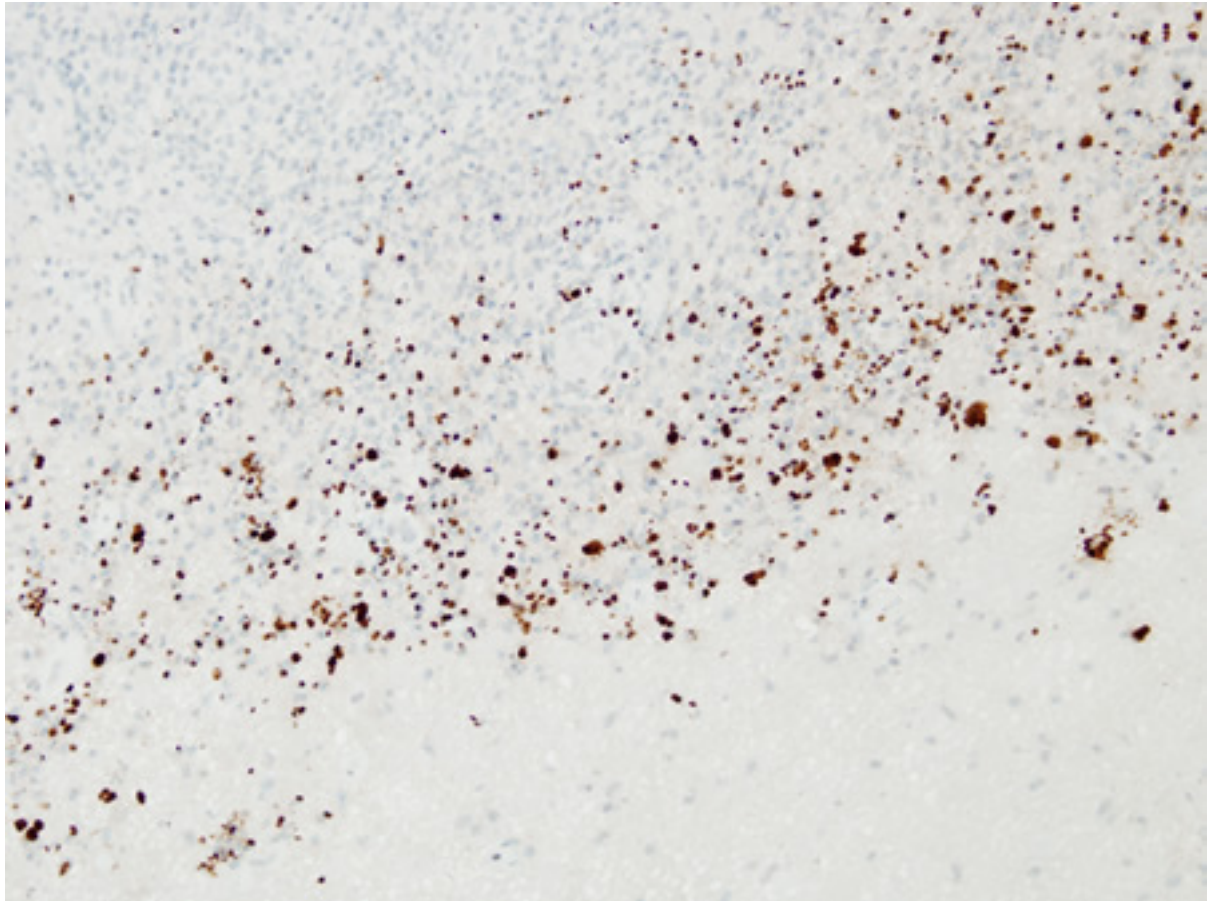


Figure 33: Biopsy of HIV patient with toxoplasmosis, with the tachyzoites identified using immunohistochemistry

From the personal collection of Robert E. Schmidt; used with permission

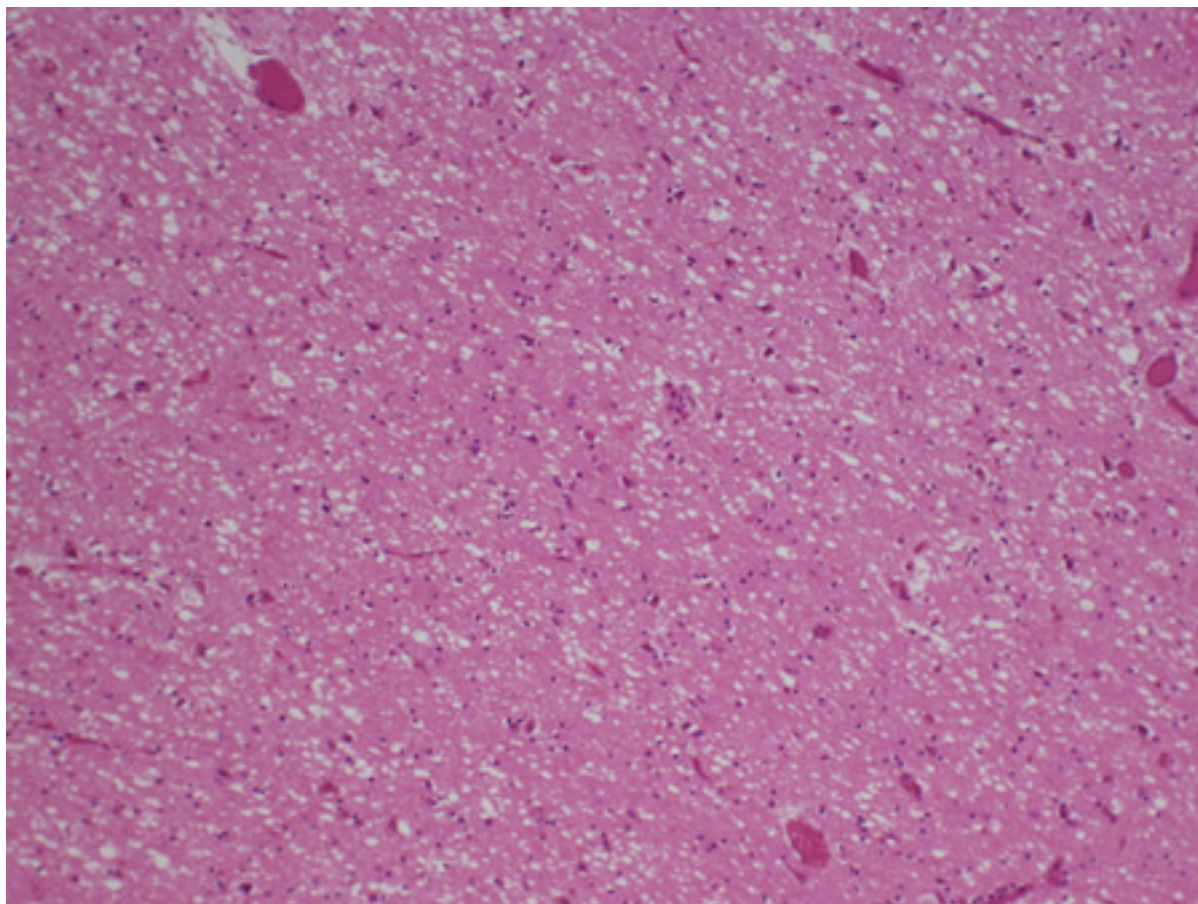


Figure 34: Biopsy of the posterior thalamus of patient with Creutzfeldt-Jakob disease showing the spongiform changes

From the personal collection of Robert E. Schmidt; used with permission

Disclaimer

BMJ Best Practice is intended for licensed medical professionals. BMJ Publishing Group Ltd (BMJ) does not advocate or endorse the use of any drug or therapy contained within this publication nor does it diagnose patients. As a medical professional you retain full responsibility for the care and treatment of your patients and you should use your own clinical judgement and expertise when using this product.

This content is not intended to cover all possible diagnosis methods, treatments, follow up, drugs and any contraindications or side effects. In addition, since such standards and practices in medicine change as new data become available, you should consult a variety of sources. We strongly recommend that you independently verify specified diagnosis, treatments and follow-up and ensure it is appropriate for your patient within your region. In addition, with respect to prescription medication, you are advised to check the product information sheet accompanying each drug to verify conditions of use and identify any changes in dosage schedule or contraindications, particularly if the drug to be administered is new, infrequently used, or has a narrow therapeutic range. You must always check that drugs referenced are licensed for the specified use and at the specified doses in your region.

Information included in BMJ Best Practice is provided on an “as is” basis without any representations, conditions or warranties that it is accurate and up to date. BMJ and its licensors and licensees assume no responsibility for any aspect of treatment administered to any patients with the aid of this information. To the fullest extent permitted by law, BMJ and its licensors and licensees shall not incur any liability, including without limitation, liability for damages, arising from the content. All conditions, warranties and other terms which might otherwise be implied by the law including, without limitation, the warranties of satisfactory quality, fitness for a particular purpose, use of reasonable care and skill and non-infringement of proprietary rights are excluded.

Where BMJ Best Practice has been translated into a language other than English, BMJ does not warrant the accuracy and reliability of the translations or the content provided by third parties (including but not limited to local regulations, clinical guidelines, terminology, drug names and drug dosages). BMJ is not responsible for any errors and omissions arising from translation and adaptation or otherwise. Where BMJ Best Practice lists drug names, it does so by recommended International Nonproprietary Names (rINNs) only. It is possible that certain drug formularies might refer to the same drugs using different names.

Please note that recommended formulations and doses may differ between drug databases drug names and brands, drug formularies, or locations. A local drug formulary should always be consulted for full prescribing information.

Treatment recommendations in BMJ Best Practice are specific to patient groups. Care is advised when selecting the integrated drug formulary as some treatment recommendations are for adults only, and external links to a paediatric formulary do not necessarily advocate use in children (and vice-versa). Always check that you have selected the correct drug formulary for your patient.

Where your version of BMJ Best Practice does not integrate with a local drug formulary, you should consult a local pharmaceutical database for comprehensive drug information including contraindications, drug interactions, and alternative dosing before prescribing.

Interpretation of numbers

Regardless of the language in which the content is displayed, numerals are displayed according to the original English-language numerical separator standard. For example 4 digit numbers shall not include a comma nor a decimal point; numbers of 5 or more digits shall include commas; and numbers stated to be less than 1 shall be depicted using decimal points. See Figure 1 below for an explanatory table.

BMJ accepts no responsibility for misinterpretation of numbers which comply with this stated numerical separator standard.

This approach is in line with the guidance of the [International Bureau of Weights and Measures Service](#).

Figure 1 – BMJ Best Practice Numeral Style

5-digit numerals: 10,000

4-digit numerals: 1000

numerals < 1: 0.25

Our full website and application terms and conditions can be found here: [Website Terms and Conditions](#).

Contact us

+ 44 (0) 207 111 1105

support@bmj.com

BMJ

BMA House

Tavistock Square

London

WC1H 9JR

UK

BMJ Best Practice

Contributors:

// Authors:

Sung G Ji, MD, PhD

Behavioral Neurology Fellow

Department of Neurology, University of Washington, Seattle, WA

DISCLOSURES: SGJ declares that he has no competing interests.

Payal B. Patel, MD

Assistant Professor of Neurology

Department of Neurology, University of Washington, Seattle, WA

DISCLOSURES: PBP has received research funding support from the National Institute of Health and Bayer Pharmaceuticals. PBP has received an honorarium as an author from Medlink Neurology and Continuum Neurology.

// Acknowledgements:

Dr Payal B. Patel would like to gratefully acknowledge Dr Leo H. Wang, Dr Louise T. Wang, Dr Catalina C. Ionita, Dr Manjunath Markandaya, Dr David Janicke, Dr Robert Schmidt, and Dr Kimiko Domoto-Reilly, previous contributors to this topic.

DISCLOSURES: LHW, LTW, CCI, MM, DJ, RS, and KDR declare that they have no competing interests.

// Peer Reviewers:

Alejandro Rabinstein, MD

Professor of Neurology

Mayo Clinic, Rochester, MN

DISCLOSURES: AR has participated in advisory board meetings for Astra Zeneca, Chiesi, and Shionogi.

Rodrigo Hasbun, MD, MPH, FIDSA

Professor of Medicine

UT Health McGovern Medical School, Houston, TX

DISCLOSURES: RH has received research support and personal fees from Biomerieux (Biofare Diagnostics).

Russel Dale, MBChB, MRCPCH, MSc, PhD

Professor of Paediatric Neurology

The University of Sydney, Consultant Neurologist, The Children's Hospital at Westmead, Sydney, Australia

DISCLOSURES: RD declares that he has no competing interests.