

BMJ Best Practice

Omphalocele and gastroschisis

Straight to the point of care



Last updated: Apr 29, 2022

Table of Contents

Overview	3
Summary	3
Definition	3
Theory	4
Epidemiology	4
Etiology	4
Pathophysiology	4
Case history	5
Diagnosis	7
Approach	7
History and exam	10
Risk factors	13
Investigations	14
Differentials	14
Management	16
Approach	16
Treatment algorithm overview	24
Treatment algorithm	25
Primary prevention	31
Patient discussions	31
Follow up	32
Monitoring	32
Complications	33
Prognosis	34
Guidelines	35
Treatment guidelines	35
Online resources	36
References	37
Images	42
Disclaimer	51

Summary

Gastroschisis and omphalocele are defects of the abdominal wall that occur in utero, can be detected prenatally using fetal ultrasonography, and result in herniation of abdominal contents.

The significant fluid balance changes and heat loss from exposed intestines in gastroschisis require emergency surgical intervention to establish abdominal wall closure or temporary coverage.

The lack of a protective sac in gastroschisis exposes the intestines to amniotic fluid in utero, leading to a thick inflammatory film or peel overlying the intestine and causing delay of return of normal bowel function after closure.

Intestinal atresia, occurs in 10% to 15% of infants with gastroschisis, and is related to ischemia of the exposed gut caused by constriction of its mesenteric blood supply at the level of the abdominal wall defect.

The most common cause of mortality in omphalocele relates to associated organ system and chromosomal anomalies such as pentalogy of Cantrell and Beckwith-Wiedemann syndrome, which are characterized by cardiac anomalies and chromosomal defects.

Successful postnatal management of all abdominal wall defects is focused on timely abdominal wall closure, temperature maintenance, fluid resuscitation, and prevention of additional fluid loss from the abdominal contents, as well as prevention of ischemia and infarction of the intestine.

Definition

Gastroschisis and omphalocele are congenital defects of the abdominal wall resulting in intestinal herniation from the abdominal cavity. In contrast to omphalocele, there is no sac covering the intestines in gastroschisis. They can both be detected prenatally using fetal ultrasonography. Limited studies have attempted to categorize gastroschisis defects into subsets of simple or complex defects, with simple gastroschisis existing as an isolated defect, and complex gastroschisis occurring with other gastrointestinal anomalies such as intestinal atresia, perforation, necrosis, or volvulus.

Epidemiology

The reported incidence of gastroschisis is 1-6 in 10,000 live births.[1] [2] Gastroschisis occurs more commonly in infants of young mothers, with a 10- to 16-fold higher incidence in children born to women aged younger than 20 years compared with children born to women aged 25-29 years, and it is slightly more frequent in male than female infants.[3] [4] Some studies suggest the incidence of gastroschisis is increasing worldwide with the use of vasoconstrictive medications.[5] [6]

Small omphaloceles occur in 1 in 5000 live births, while large omphaloceles are less common, occurring in 1 in 10,000 live births.[7] The frequency of omphalocele is the same in the US and Europe.[8] In contrast to gastroschisis, omphalocele occurs more often in older mothers, aged >40 years.[9] [10]

Etiology

The etiology of gastroschisis and omphalocele is unclear, and many theories have been proposed to explain these abdominal wall defects. Due to the poor understanding of the etiology of these conditions, it is difficult to propose modifiable factors for prevention. Some studies suggest that maternal use of recreational drugs may be a risk factor for gastroschisis.[11] Others suggest that the incidence of gastroschisis is less in young mothers taking daily multivitamins during pregnancy.[12] Conversely, the incidence of gastroschisis in babies of teenage mothers who smoke is increasing.[3] [4] [9] [10]

Evidence supporting an association between smoking during pregnancy and the development of abdominal wall defects in the fetus is well described for both gastroschisis and omphalocele. It is suggested that cigarette smoke causes vasoconstriction that contributes to placental insufficiency and failed development of the vascular system.[11] [13] [14] [15] Maternal infections and illness during pregnancy are seen in mothers who deliver infants with omphalocele and gastroschisis. It is proposed that maternal illness can contribute to placental insufficiency that may, in turn, contribute to the development of abdominal wall defects.[4] Genitourinary infection during pregnancy has also been shown to be associated with abdominal wall defects.[16]

Pathophysiology

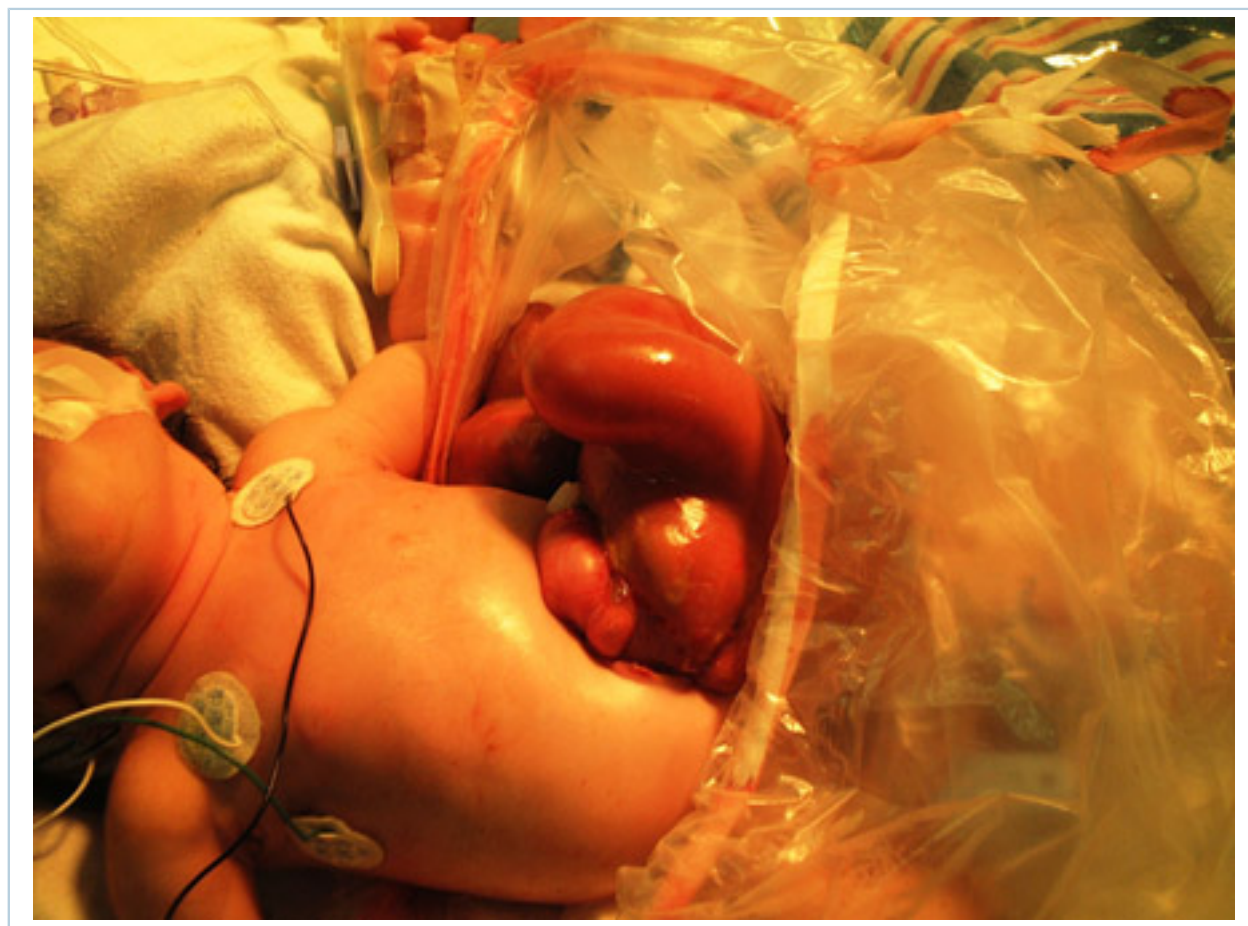Several theories have been proposed to explain the development of gastroschisis. One theory suggests that the full-thickness defect results from abnormal involution of the right umbilical vein causing rupture of the anterior abdominal wall at the weakened point.[17] Another theory suggests that premature interruption of the right omphalomesenteric artery results in ischemia of the anterior abdominal wall, allowing herniation of abdominal contents.[1] [18] In utero rupture of an omphalocele leading to the development of gastroschisis has also been suggested.[19] However, the lack of associated anomalies in gastroschisis does not support this theory. The thickened peel covering the intestine in gastroschisis may be due to exposure of the extruded abdominal contents to fetal urine or meconium in utero or mesenteric venous obstruction resulting in edema.

Many theories have also been suggested to explain the development of omphalocele. These include failure of intestinal migration into the abdomen by 10 to 12 weeks of embryological development, failure of central migration of the lateral body folds of mesoderm, and persistence of a body stalk beyond 12 weeks' gestation.[20]

Case history

Case history #1

A newborn infant is transferred to the neonatal intensive care unit following a spontaneous vaginal delivery at which the neonatal resuscitation team was present and performed an intubation for respiratory distress. The abdomen of the infant is noted to have thickened loops of dark intestine outside of the abdominal cavity and to the right of the umbilical cord. The infant is placed feet first into a clear bowel bag containing warm saline-soaked gauze pads, and vascular access is obtained via the neck or upper extremity.

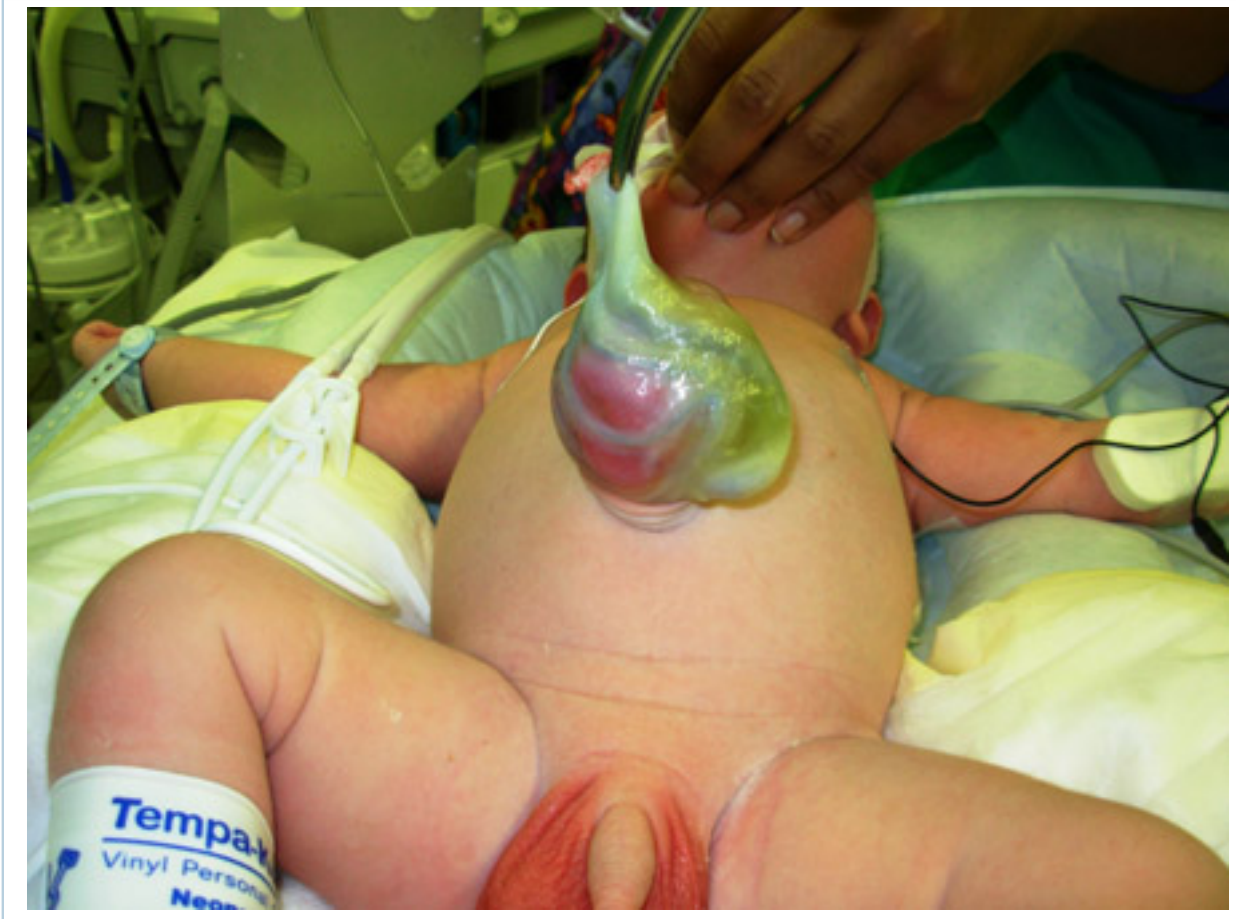

Immediately after delivery, an infant with gastroschisis is placed in a protective bowel bag

From collection of J.J. Tepas III, MD, FACS, FAAP

Case history #2

A newborn boy, with an estimated gestational age of 35 weeks, was delivered by spontaneous vaginal delivery. On initial examination, his Apgar score was noted to be five at 1 minute and nine at 5 minutes. There is a large clear membrane covering his abdomen, through which intestine is visible.



Note the membrane covering the abdominal contents in this omphalocele

From collection of J.J. Tepas III, MD, FACS, FAAP

Approach

Risk factors related to the development of abdominal wall defects are generally thought to be unmodifiable. However, maternal health factors associated with the development of abdominal wall defects include smoking and the use of certain recreational drugs.[3] [4] [9] [10] There are strong associations related to the discovery of these abdominal wall defects, which include maternal age <20 years for the development of gastroschisis and maternal age >40 years for omphalocele. Additionally, gastroschisis is more likely to be seen in male infants than in female infants. Weak factors associated with the development of abdominal wall defects include infections during pregnancy.

Abdominal wall defects of the fetus are routinely detected on prenatal ultrasound in the second trimester, when an abdominal mass may be visualized outside of the abdominal wall. Elevated alpha-fetoprotein levels, measured as part of the routine maternal triple screen at 16 to 18 weeks' gestation, suggest the presence of an abdominal wall defect and warrant further investigation with prenatal ultrasonography.[21] Definitive diagnosis is achieved at birth through a careful physical exam of the infant revealing abdominal contents external to the abdominal wall.

Detection of abdominal wall defects in the prenatal period allows parental counseling and the development of a postdelivery treatment plan, as well as arrangements for the delivery to take place at a tertiary care center equipped to handle the resuscitative and surgical needs of the newborn infant.[9] [17] [20] [22] [23]

Prenatal assessment

Elevated maternal serum alpha-fetoprotein levels reflect protein loss from the intestine floating in the amniotic fluid, and are a reliable but nonspecific marker for the presence of gastroschisis. Abnormal maternal serum screening results warrant additional imaging to confirm the diagnosis of an abdominal wall defect, with high-definition ultrasound in addition to routine abdominal ultrasonography to visualize the developing fetus.

If evidence of omphalocele is confirmed on ultrasonography, invasive procedures such as amniocentesis performed at 15 to 20 weeks' gestation or chorionic villus sampling performed at 10 to 12 weeks' gestation may be undertaken to evaluate the possibility of associated chromosomal abnormalities, such as trisomy 13, trisomy 18, trisomy 21, Turner syndrome, Klinefelter syndrome, or triploidy.[9] [17] [20] Chromosomal abnormalities are more common in omphalocele than gastroschisis.

In many pregnancies, despite normal serum screening results, an abdominal wall defect may be detected on a routine prenatal ultrasound. During second-trimester ultrasonography, these defects are characterized by abdominal wall masses and echogenic bowel outside of the abdominal wall.

As associated genetic anomalies can occur in as many as 30% to 40% of infants with prenatal evidence of omphalocele, prenatal genetic testing for chromosomal abnormalities, and an echocardiogram for detection of cardiac anomalies, are routinely performed.[24] [25] Infants with prenatal evidence of gastroschisis do not routinely receive prenatal genetic testing.

In gastroschisis, dilated, fluid-filled loops of bowel floating freely in the amniotic fluid, and in some cases intestinal atresia, may be detected on ultrasound. If omphalocele is suspected, sternal and cardiac defects should be evaluated on ultrasound to determine the potential presence of pentalogy of Cantrell and Beckwith-Wiedemann syndrome, the latter being confirmed by the presence of macroglossia and visceromegaly.[17] [22]

When an abdominal wall defect is visualized on ultrasound, in addition to the diagnosis of gastroschisis or omphalocele, it is important to consider the possibility of cloacal exstrophy, which is characterized by a portion of the large intestine lying outside of the body and splitting the bladder into two halves. In boys, the penis is usually flat and short, with the exposed inner surface of the urethra on top. The penis is sometimes split into a right and left half. In girls, the clitoris is split and there may be one or two vaginal openings. Cloacal exstrophy is a very rare birth defect, affecting 1 in every 200,000 to 400,000 births.^[26]

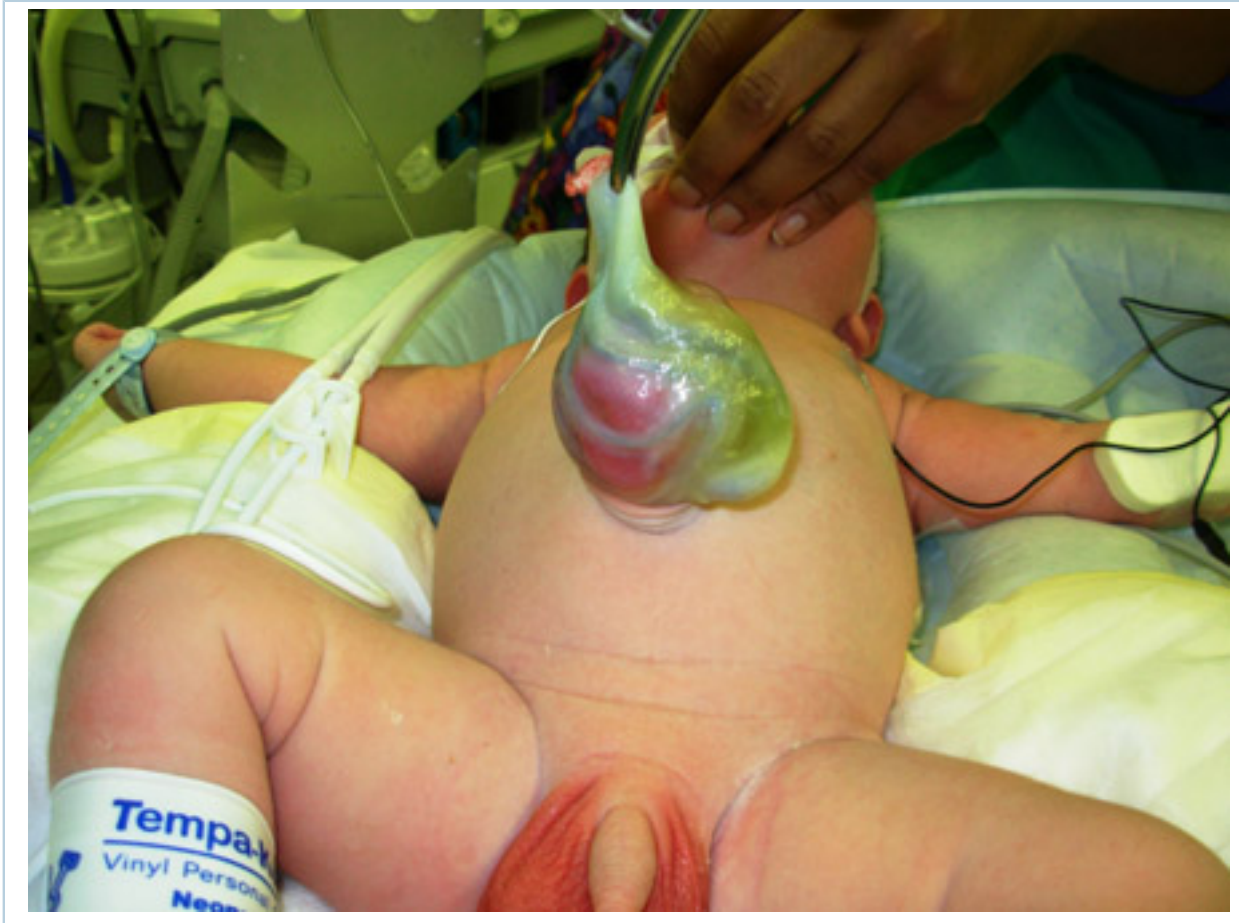The optimal mode of delivery of infants with a prenatally diagnosed abdominal wall defect is intensely controversial.^[17] Anecdotal evidence suggests that vaginal delivery may be contraindicated for infants with abdominal wall defects, particularly gastroschisis. However, other reports have found that avoiding vaginal delivery for these infants confers no benefit.^{[23] [27] [28] [29] [30]}

Postnatal exam

A careful physical exam at birth revealing abdominal contents external to the abdominal wall is diagnostic of omphalocele and gastroschisis.

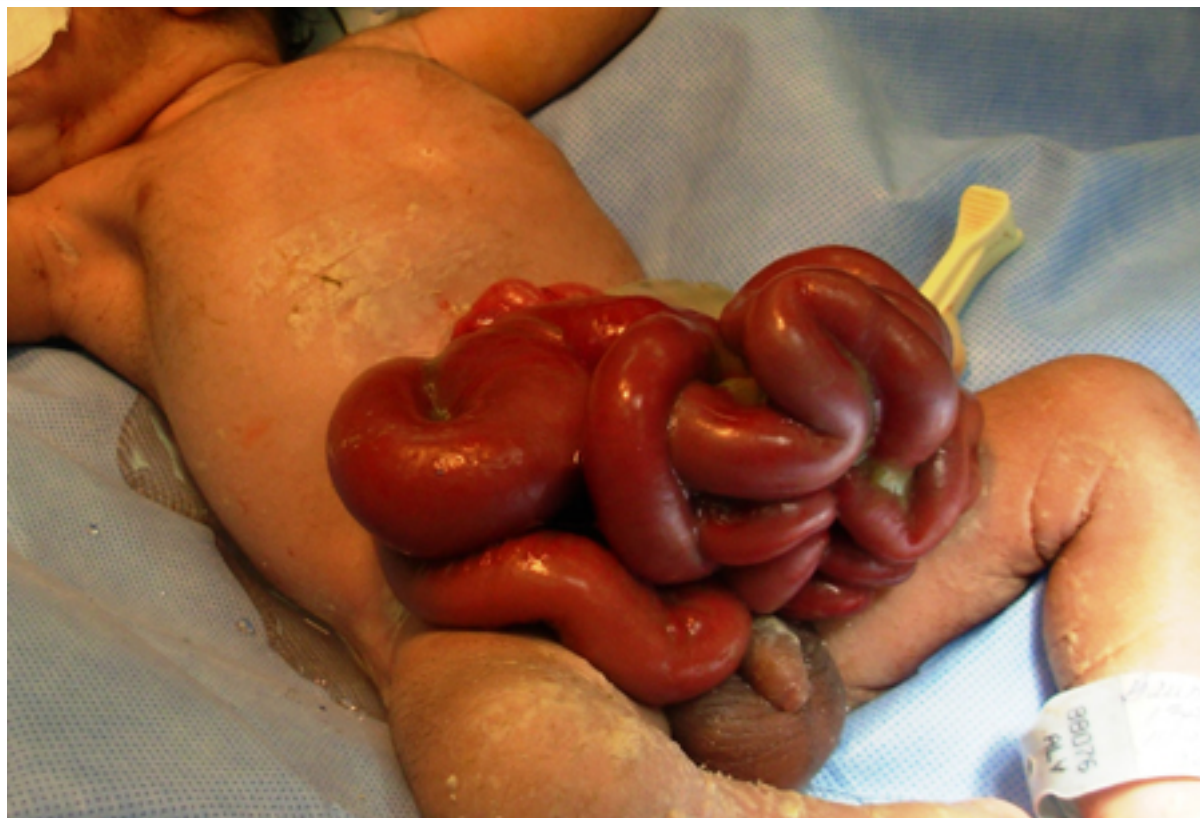Omphaloceles are abdominal wall defects ranging from 4 to 12 cm in size and can be located centrally, or in the epigastric or hypogastric regions. In omphalocele, as the abdominal contents have a protective membranous covering in utero, the intestines are usually healthy at birth. This condition may be associated with Beckwith-Wiedemann syndrome and, rarely, with pentalogy of Cantrell. The likelihood of additional developmental abnormalities, most often affecting cardiac anatomy, is high, leading to the descriptive phrase "bad baby, good bowel." Prenatal ultrasonography and postnatal physical exam will detect most of the developmental abnormalities associated with omphalocele.

In gastroschisis the lack of a protective membranous covering causes the abdominal contents to be free-floating in utero. This leads to a chemical reaction that creates a thick inflammatory film or peel overlying the intestine. Gastroschisis is commonly associated with intestinal atresia, which occurs in 10% to 15% of infants, and is related to ischemia of the exposed gut caused by constriction of its mesenteric blood supply at the level of the abdominal wall defect.^[31] There are few additional structural abnormalities, although the intestine may require a lengthy period to recover, leading to the descriptive phrase "good baby, bad bowel."



Note the membrane covering the abdominal contents in this omphalocele

From collection of J.J. Tepas III, MD, FACS, FAAP



Extruded gut in abdominal wall defect

From collection of J.J. Tepas III, MD, FACS, FAAP

Investigations

During the neonatal period, infants with omphalocele and gastroschisis do not routinely receive any further investigations unless there are signs of dysmorphism. However, genetic counseling is routinely offered because many families request assistance in determining future child-bearing plans.

History and exam

Key diagnostic factors

maternal age <20 years (gastroschisis) (common)

- Gastroschisis occurs more commonly in infants of young mothers, with a 10- to 16-fold higher incidence in children born to women <20 years old compared with children born to women of 25 to 29 years.[3] [4] The mechanism behind the relationship is unknown.[13] [14] [15]

maternal age >35 years (omphalocele) (common)

- Omphalocele occurs more often in mothers age >35 years of age.[9] [10]

elevated maternal serum alpha-fetoprotein (gastroschisis) (common)

- Elevated alpha-fetoprotein levels are a reliable but nonspecific marker for the presence of gastroschisis due to proteins lost from the intestine floating in the amniotic fluid. This finding warrants further evaluation with a prenatal ultrasound.[21] [22]

positive prenatal ultrasound (common)

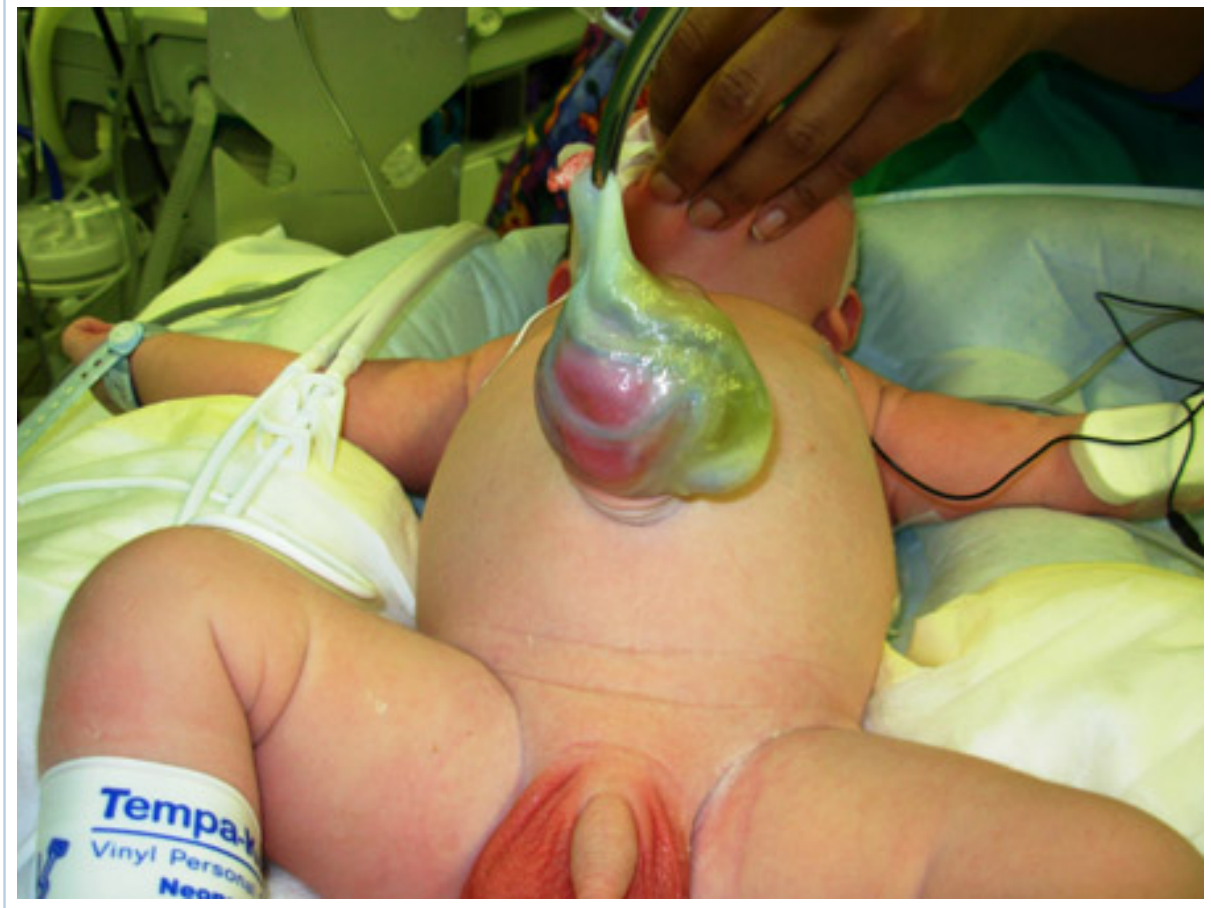- Abdominal wall defects of the fetus are usually detected on routine prenatal ultrasound in the second trimester, when an abdominal mass may be visualized outside of the abdominal wall.
- During second-trimester ultrasonography, these defects are characterized by abdominal wall masses and echogenic bowel outside of the abdominal wall. In gastroschisis, dilated, fluid-filled loops of bowel floating freely in the amniotic fluid, and, in some cases, intestinal atresia, may be detected.

fetal chromosomal abnormalities (omphalocele) (common)

- If evidence of omphalocele is confirmed on ultrasonography, invasive procedures, such as amniocentesis performed at 15 to 20 weeks' gestation or chorionic villus sampling performed at 10 to 12 weeks' gestation, may be undertaken to evaluate the possibility of associated chromosomal abnormalities such as trisomy 13, trisomy 18, trisomy 21, Turner syndrome, Klinefelter syndrome, or triploidy.^{[9] [17] [20]}

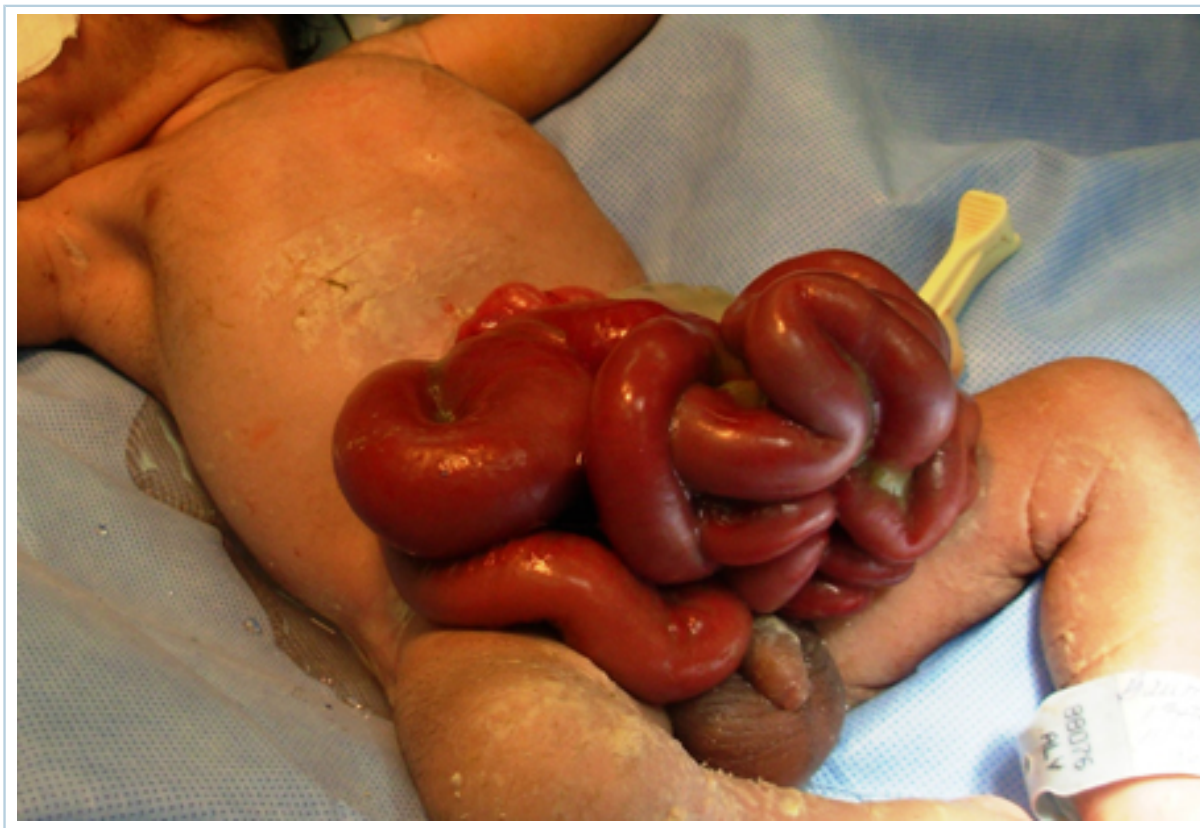abdominal contents external to the abdominal wall (common)

- Omphaloceles are abdominal wall defects ranging from 4 to 12 cm in size and can be located centrally, or in the epigastric or hypogastric regions. In omphalocele, as the abdominal contents have a protective membranous covering in utero, the intestines are usually healthy at birth.
- In gastroschisis, the lack of a protective membranous covering causes the abdominal contents to be free-floating in utero, leading to a chemical reaction that creates a thick inflammatory film or peel overlying the intestine. Gastroschisis is commonly associated with intestinal atresia, which occurs in 10% to 15% of cases, and is related to ischemia of the exposed gut caused by constriction of its mesenteric blood supply at the level of the abdominal wall defect.^[31]



Note the membrane covering the abdominal contents in this omphalocele

From collection of J.J. Tepas III, MD, FACS, FAAP



Extruded gut in abdominal wall defect

From collection of J.J. Tepas III, MD, FACS, FAAP

Risk factors

Strong

maternal age <20 years (gastroschisis)

- Gastroschisis occurs more commonly in infants of young mothers, with a 10- to 16-fold higher incidence in children born to women age <20 years old compared with children born to women of 25 to 29 years.[3] [4] The mechanism behind the relationship is unknown.[13] [14] [15]

male sex of neonate (gastroschisis)

- Gastroschisis is slightly more frequent in male infants than in female infants.[3] [4]

maternal age >35 years (omphalocele)

- Omphalocele occurs more often in infants of mothers age >35 years of age.[9] [10]

smoking

- Evidence supporting an association between smoking during pregnancy and the development of abdominal wall defects in the fetus is well described for both gastroschisis and omphalocele. It is suggested that cigarette smoke causes vasoconstriction that contributes to placental insufficiency and

failed development of the vascular system.[11] [13] [14] [15] The incidence of gastroschisis in babies of teenage mothers who are smokers is increasing.[3] [4] [9] [10]

Weak

maternal infection during pregnancy

- Maternal infections and illness during pregnancy are seen in mothers who deliver infants with omphalocele and gastroschisis. It is proposed that maternal illness can contribute to placental insufficiency that may, in turn, contribute to the development of abdominal wall defects.[4] Genitourinary infection during pregnancy has also been shown to be associated with abdominal wall defects.[16]

Investigations

1st test to order

Test	Result
clinical diagnosis <ul style="list-style-type: none"> During the neonatal period, infants with omphalocele and gastroschisis do not routinely receive any further investigations unless there are signs of dysmorphism. 	omphalocele or gastroschisis

Differentials

Condition	Differentiating signs / symptoms	Differentiating tests
Cloacal exstrophy	<ul style="list-style-type: none"> Rare midline defect of the lower abdominal wall in which the intestines lie outside of the abdomen, often surrounded by two halves of the bladder. Genitalia are often bifurcated, the rectum may communicate with the bladder and an imperforate anus may be present. 	<ul style="list-style-type: none"> Prenatal ultrasonography: visualization of defect with the presence of gut or other abdominal viscera outside of the abdominal cavity. Postnatal physical exam: confirmatory of diagnosis.

Screening

Prenatal screening

Prenatal screening is routine, but extra vigilance may be required if there is a family history of birth defects, the mother is aged >35 years, harmful medications have been used during pregnancy, or there has been exposure to radiation. First-trimester ultrasonography is performed to estimate gestational age, to confirm the pregnancy or determine the presence of a multiple pregnancy, and to rule out the presence of abnormal gestation or molar pregnancy. Second-trimester ultrasonography is employed to assess fetal developmental abnormalities, evaluate fetal wellbeing, and identify potential causes of oligo- or polyhydramnios.

Routine maternal serum testing, known as the triple screen, is performed at 16 to 18 weeks' gestation to screen for the presence of alpha-fetoprotein, human chorionic gonadotropin, and estriol.^[21] Screening for abdominal wall defects routinely occurs when maternal serum alpha-fetoprotein levels are elevated due to proteins lost from the intestine floating in the amniotic fluid in gastroschisis. Ultrasonography performed in the second trimester can detect abdominal wall defects by visualization of a mass outside of the abdominal wall and confirm the presence of other associated structural abnormalities.

Approach

No intrauterine interventions are available for the treatment of omphalocele or gastroschisis. Therapy is therefore undertaken after delivery of the infant, with the goals of temperature maintenance, fluid resuscitation, and preventing additional fluid loss from the abdominal contents with appropriate care of the herniated viscera, paying particular attention to the preservation of its blood supply. Prevention of intestinal ischemia and infarction in gastroschisis is achieved with surgical closure of the defect. Some centers may use prophylactic antibiotics, but antibiotic treatment is not routine and local protocols should be followed.

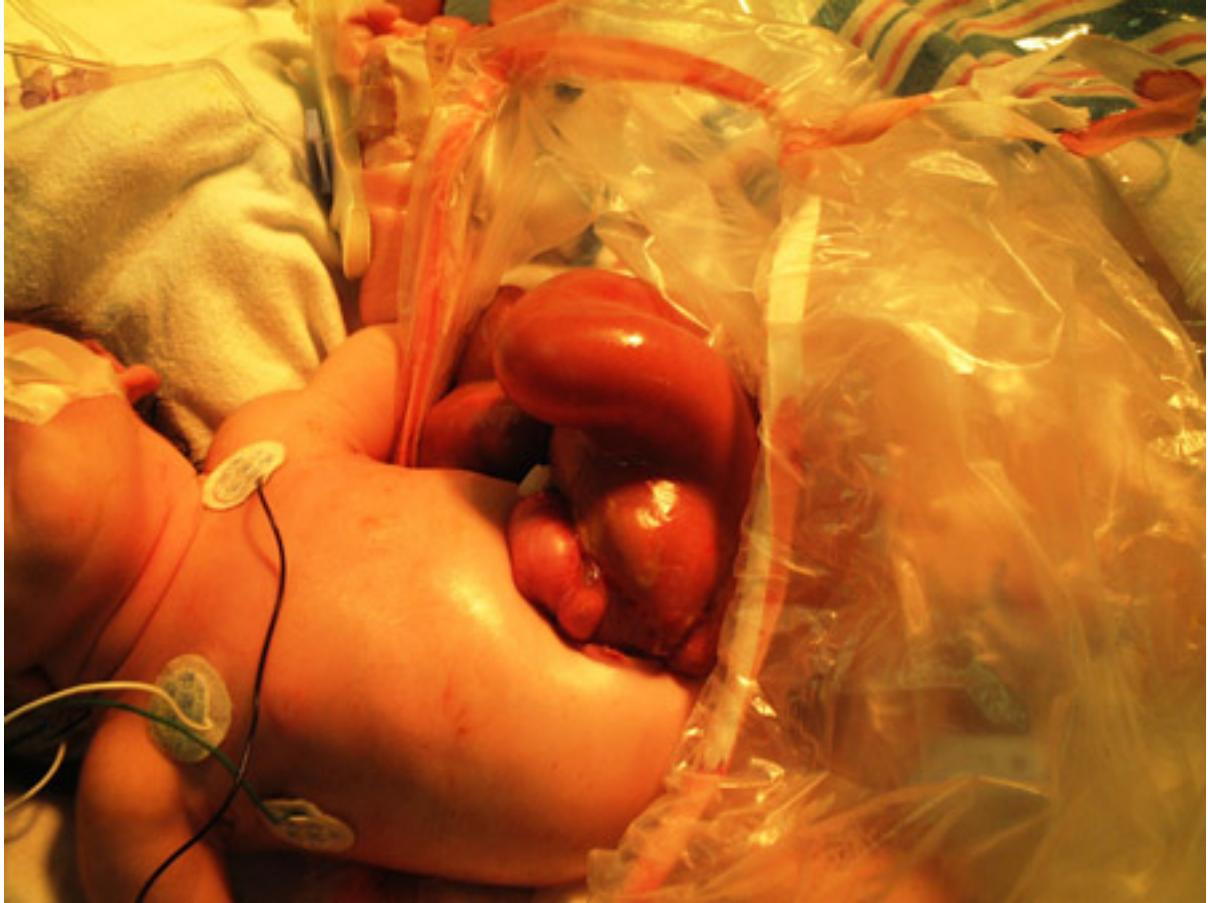Gastroschisis

Gastroschisis is a surgical emergency requiring immediate closure or coverage. In gastroschisis, significant fluid balance changes require neonatal fluid resuscitation and emergent surgical intervention to prevent fluid loss and restore the viscera to the abdominal cavity.

Immediate postnatal management of gastroschisis involves fluid resuscitation and the placing of a sterile covering or a clear bowel bag over the herniated abdominal contents to prevent evaporation, heat loss, and infection. The infant should then be urgently transferred to a neonatal intensive unit (NICU) with specialized pediatric surgical capacity.^[32]

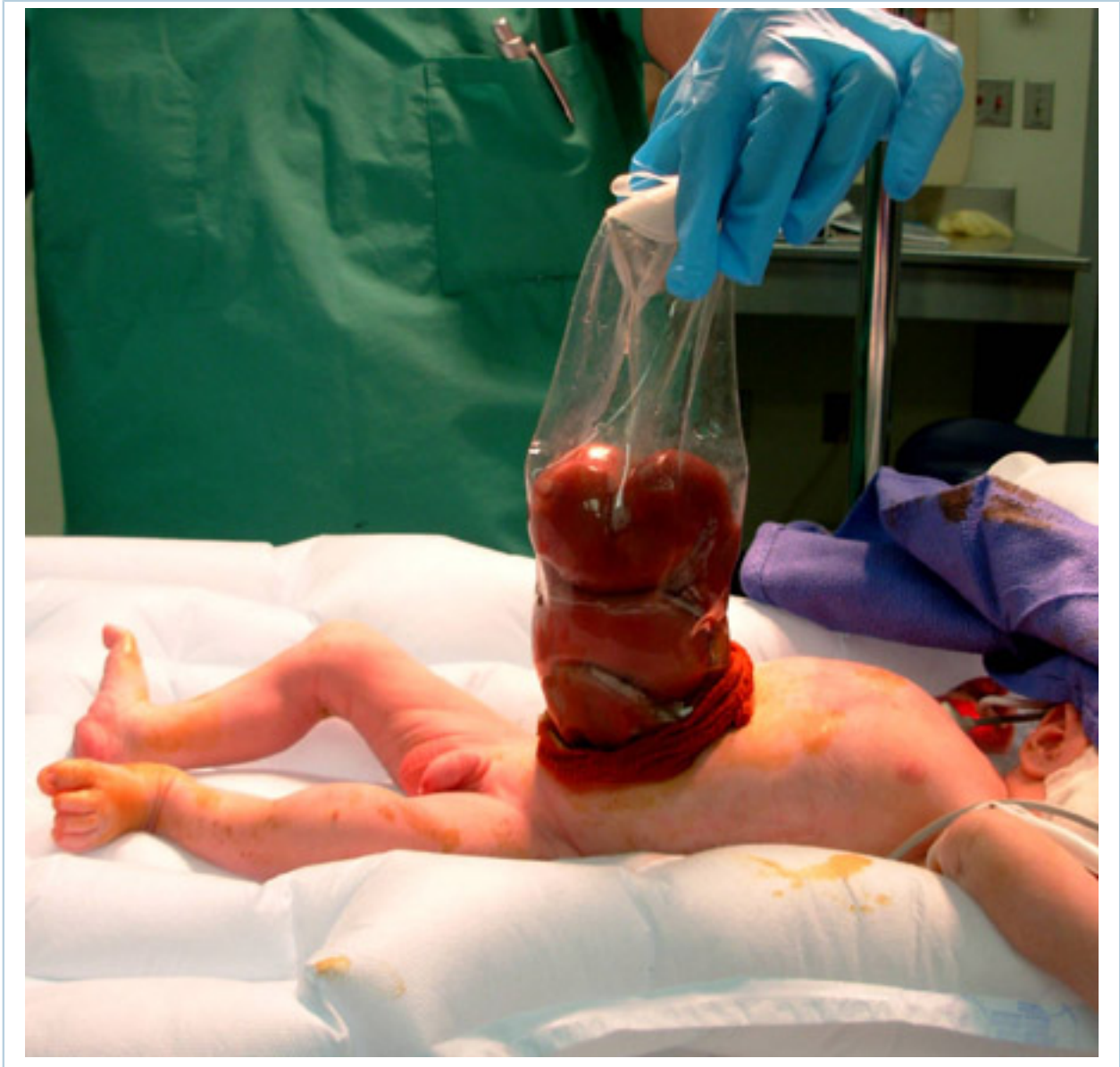Small defects may be treated with primary surgical repair, while larger defects or those with extensive herniation of abdominal contents require a staged approach with placement of the abdominal contents into a suspended silo and gradual reduction into the abdominal cavity. Ventilatory support is often required during this process. Once the abdominal contents have been fully reduced into the abdominal cavity, surgery is performed to close the fascia and skin. Occasionally, reduction of pliable bowel is possible in the neonatal unit without the need for operative repair. Such bedside repair in the neonatal unit depends on the size of the defect and presence of healthy abdominal contents.

Surgery is followed by a trial of a nasogastric tube for decompression of the bowel and total parenteral nutrition while the inflammatory peel resolves.^[33] If an atretic (ischemic) segment is present, a small bowel obstruction may develop after enteral feeds, necessitating additional surgical intervention. Infants with gastroschisis are often slow to feed due to the intestinal irritation.



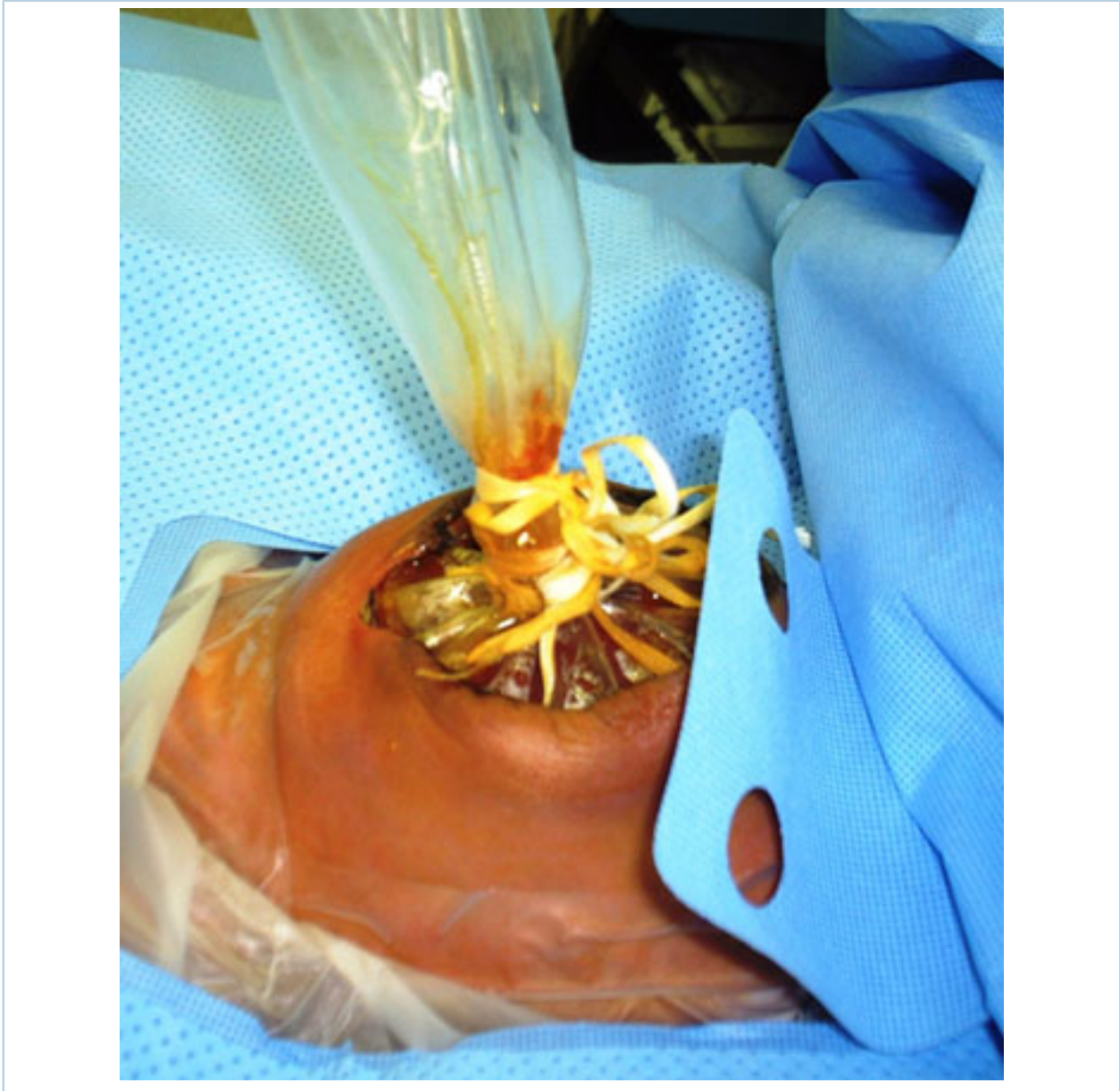Immediately after delivery, an infant with gastroschisis is placed in a protective bowel bag

From collection of J.J. Tepas III, MD, FACS, FAAP



A staged repair of gastroschisis involves the placement of a silo to reduce contents into the abdomen

From collection of J.J. Tepas III, MD, FACS, FAAP



Once intestinal contents are fully reduced into the abdomen, closure of the abdominal wall follows

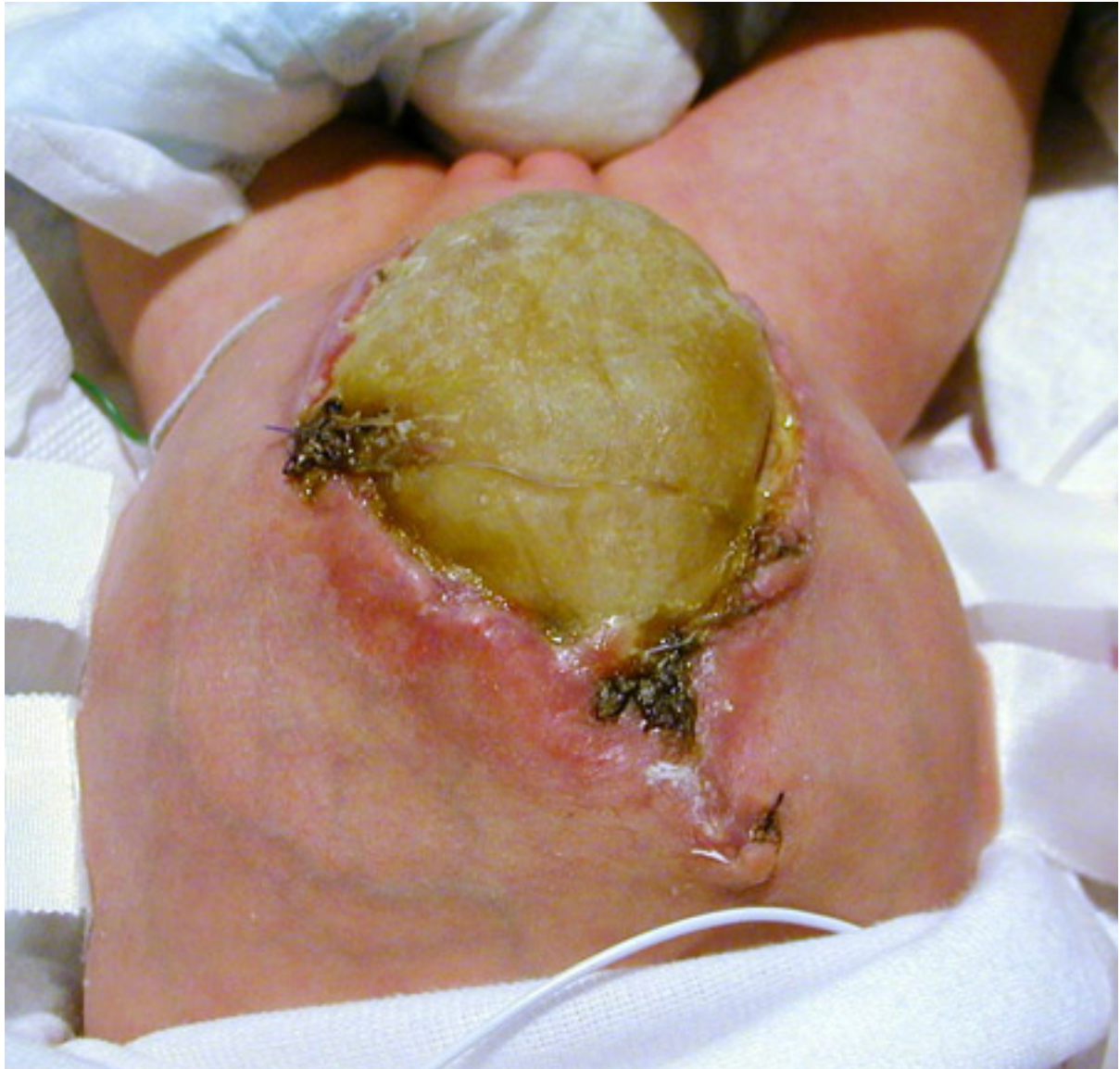From collection of J.J. Tepas III, MD, FACS, FAAP

Omphalocele

After delivery, infants with omphalocele should receive appropriate fluid resuscitation. If the membranous sac is not intact, a sterile covering or a clear bowel bag must be placed over the herniated abdominal contents to prevent evaporation, heat loss, and infection.^[34] The infant should then be urgently transferred to a NICU with specialized pediatric surgical capacity. A nasogastric tube should be inserted to decompress the bowel.

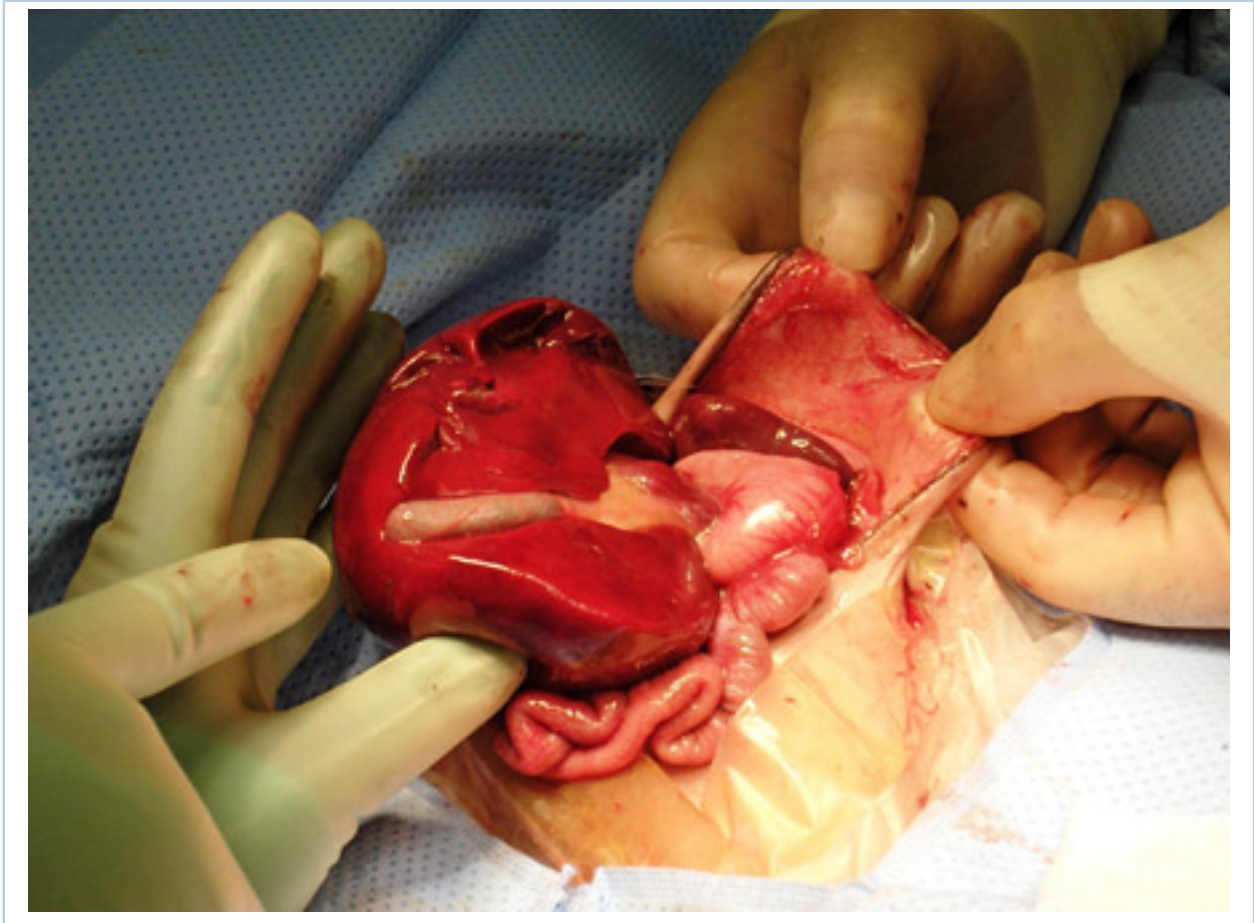
Surgical repair of omphalocele is elective, unless the membranous sac is ruptured. Defects without rupture of the membranous sac may be allowed to epithelialize, especially if associated anomalies render immediate surgical intervention inappropriately risky. The resultant ventral hernia can be electively repaired at a later date.

If the membranous sac is ruptured, treatment is the same as for gastroschisis. Small defects may be treated with primary surgical repair, while larger defects or those with extensive herniation of abdominal contents require a staged approach with placement of the abdominal contents into a suspended silo and gradual reduction into the abdominal cavity.[35] Ventilatory support is often required during this process. Once the abdominal contents have been fully reduced into the abdominal cavity, the fascia and skin are surgically closed. Surgery is followed by a trial of a nasogastric tube for decompression of the bowel and total parenteral nutrition while the inflammatory peel resolves.



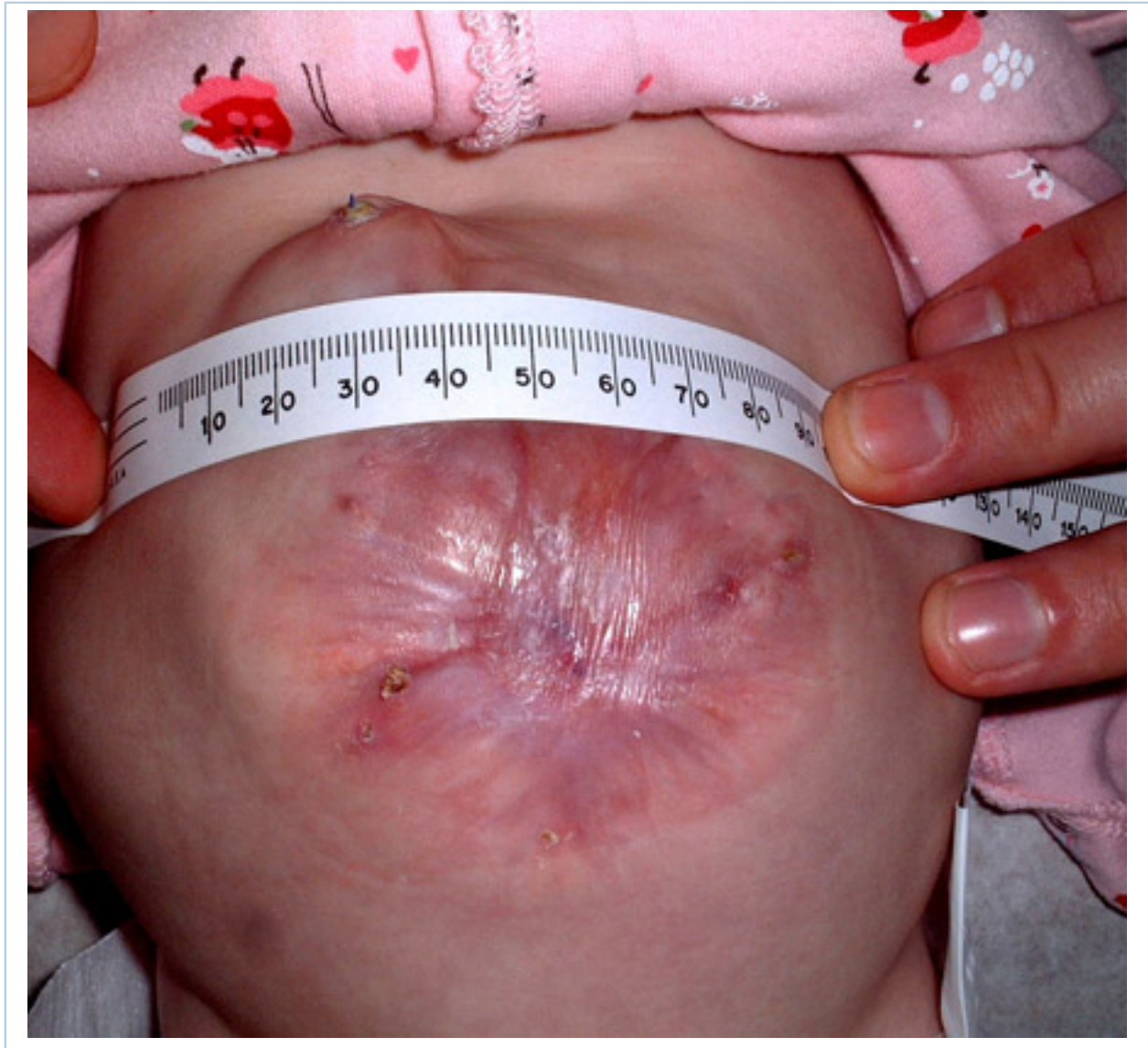
The abdominal wall defect in omphalocele is covered with a synthetic membrane

From collection of J.J. Tepas III, MD, FACS, FAAP



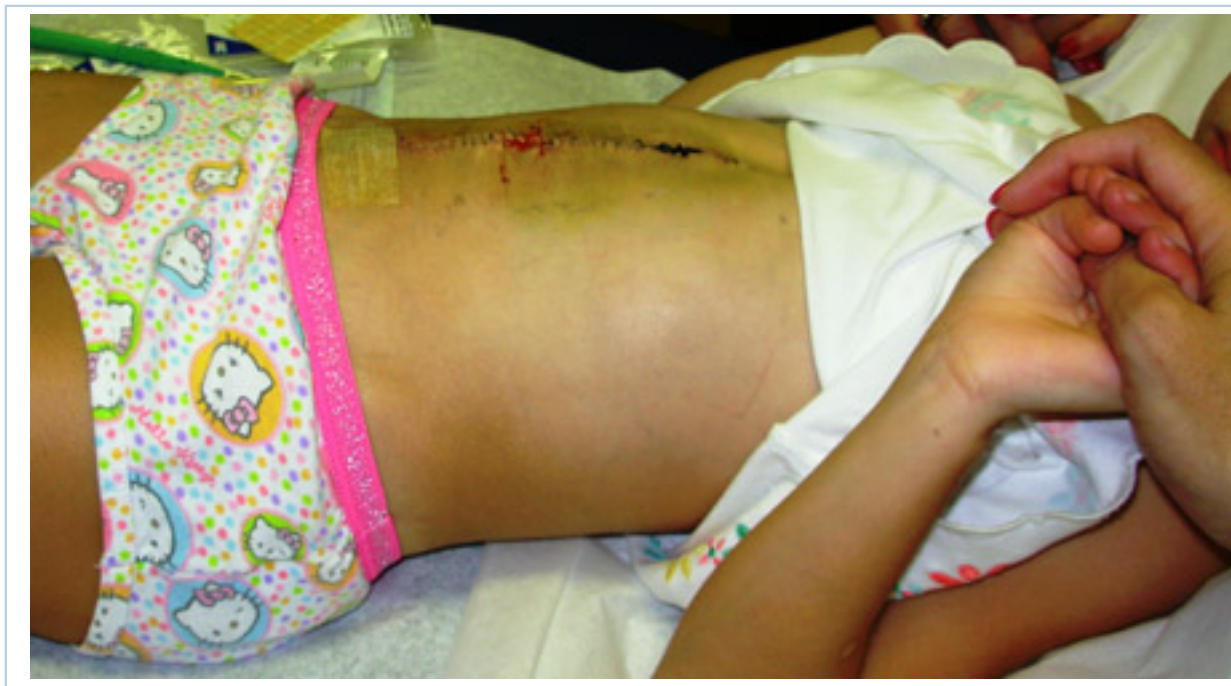This ruptured omphalocele is similar in appearance to gastroschisis

From collection of J.J. Tepas III, MD, FACS, FAAP



A ventral hernia results from synthetic wall closure of the omphalocele

From collection of J.J. Tepas III, MD, FACS, FAAP



The ventral hernia is repaired in a 6-year-old girl born with omphalocele

From collection of J.J. Tepas III, MD, FACS, FAAP

Treatment algorithm overview

Please note that formulations/routes and doses may differ between drug names and brands, drug formularies, or locations. Treatment recommendations are specific to patient groups: [see disclaimer](#)

Acute (summary)		
gastroschisis		
<ul style="list-style-type: none"> small defect large defect and/or extensive herniation 	1st	fluid resuscitation and temperature maintenance
	plus	bowel protection
	plus	primary surgical repair
	plus	postsurgical nasogastric tube and parenteral nutrition
	plus	staged reduction and surgical repair
	plus	postsurgical nasogastric tube and parenteral nutrition
	adjunct	secondary surgery
omphalocele		
<ul style="list-style-type: none"> intact membranous sac ruptured membranous sac: small defect ruptured membranous sac: large defect and/or extensive herniation 	1st	fluid resuscitation and temperature maintenance
	plus	nasogastric tube
	adjunct	surgical repair
	plus	bowel protection
	plus	primary surgical repair
	plus	postsurgical nasogastric tube and parenteral nutrition
	plus	staged reduction and surgical repair
	plus	postsurgical nasogastric tube and parenteral nutrition

Treatment algorithm

Please note that formulations/routes and doses may differ between drug names and brands, drug formularies, or locations. Treatment recommendations are specific to patient groups: [see disclaimer](#)

Acute

gastroschisis

1st fluid resuscitation and temperature maintenance

» Immediate postnatal management of gastroschisis involves fluid resuscitation and temperature maintenance.

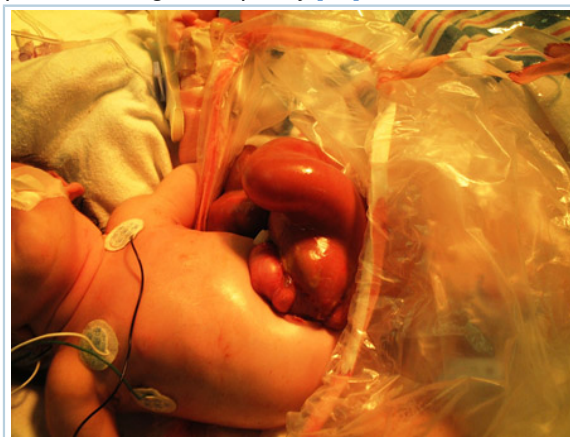» The infant should then be urgently transferred to a neonatal intensive unit with specialized pediatric surgical capacity.[32]

plus bowel protection

Treatment recommended for ALL patients in selected patient group

» A sterile covering or a clear bowel bag should be placed immediately over the herniated abdominal contents to prevent evaporation, heat loss, and infection.

» The infant should then be urgently transferred to a neonatal intensive unit with specialized pediatric surgical capacity.[32]



*Immediately after delivery, an infant with gastroschisis is placed in a protective bowel bag
From collection of J.J.
Tepas III, MD, FACS, FAAP*

■ small defect

plus primary surgical repair

Treatment recommended for ALL patients in selected patient group

» Small defects may be treated with primary surgical repair.[35]

Acute

■ large defect and/or extensive herniation

plus postsurgical nasogastric tube and parenteral nutrition

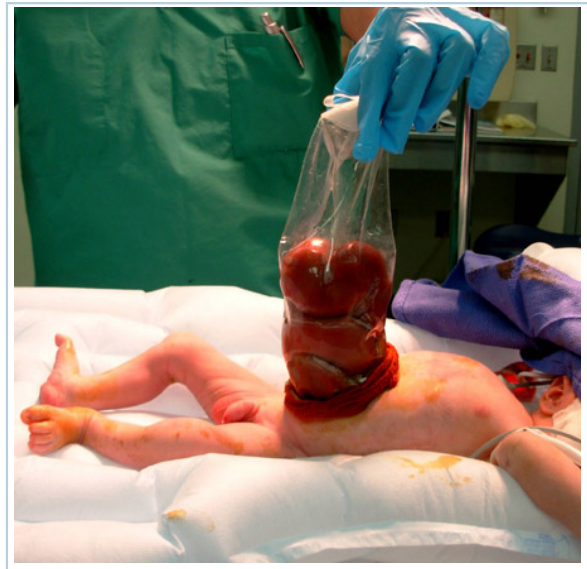Treatment recommended for ALL patients in selected patient group

» Surgery is followed by a trial of a nasogastric tube for decompression of the bowel and total parenteral nutrition while the inflammatory peel resolves.

plus staged reduction and surgical repair

Treatment recommended for ALL patients in selected patient group

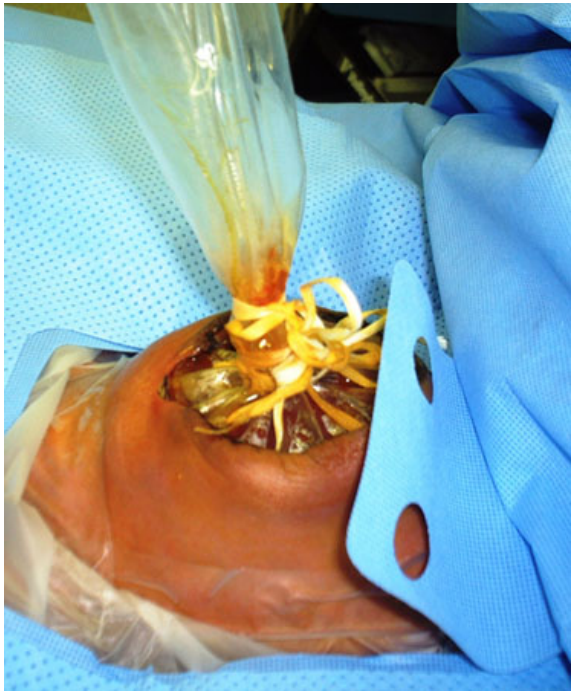» Larger defects or those with extensive herniation of abdominal contents require a staged approach with placement of the abdominal contents into a suspended silo and gradual reduction into the abdominal cavity.^[35] Ventilatory support is often required during this process. Once the abdominal contents have been fully reduced into the abdominal cavity, surgery is performed to close the fascia and skin.



A staged repair of gastroschisis involves the placement of a silo to reduce contents into the abdomen

*From collection of J.J.
Tepas III, MD, FACS, FAAP*

Acute



Once intestinal contents are fully reduced into the abdomen, closure of the abdominal wall follows
From collection of J.J. Tepas III, MD, FACS, FAAP

plus postsurgical nasogastric tube and parenteral nutrition

Treatment recommended for ALL patients in selected patient group

» Surgery is followed by a trial of a nasogastric tube for decompression of the bowel and total parenteral nutrition while the inflammatory peel resolves.[33]

adjunct secondary surgery

Treatment recommended for SOME patients in selected patient group

» If an atretic (ischemic) segment is present, a small bowel obstruction may develop after enteral feeds, necessitating further surgery.

omphalocele

omphalocele

1st fluid resuscitation and temperature maintenance

» After delivery, infants with omphalocele should receive appropriate fluid resuscitation with temperature maintenance.[34]

» The infant should then be urgently transferred to a neonatal intensive unit with specialized pediatric surgical capacity.

■ **intact membranous sac plus nasogastric tube**

Acute

adjunct

Treatment recommended for ALL patients in selected patient group

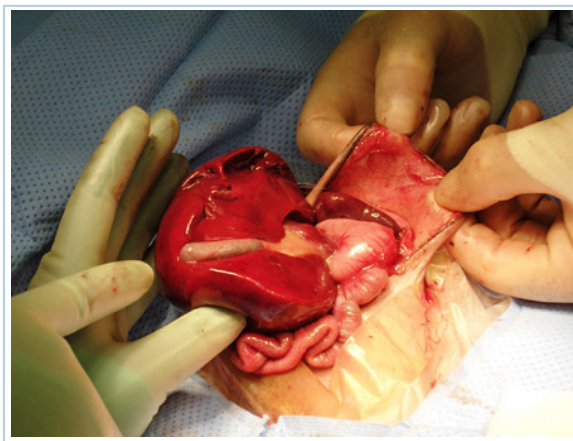
» A nasogastric tube should be inserted to decompress the bowel.

surgical repair

Treatment recommended for SOME patients in selected patient group

» Surgical repair of omphalocele is elective, unless the membranous sac is ruptured.

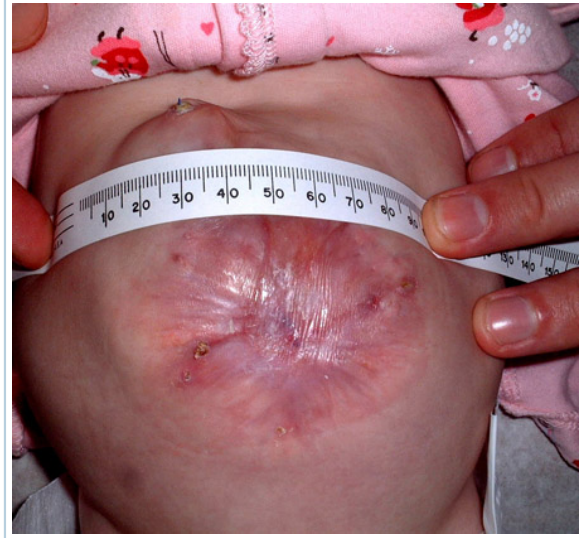» Defects without rupture of the membranous sac may be allowed to epithelialize, especially if associated anomalies render immediate surgical intervention inappropriately risky. The resultant ventral hernia can be electively repaired at a later date.



This ruptured omphalocele is similar in appearance to gastroschisis

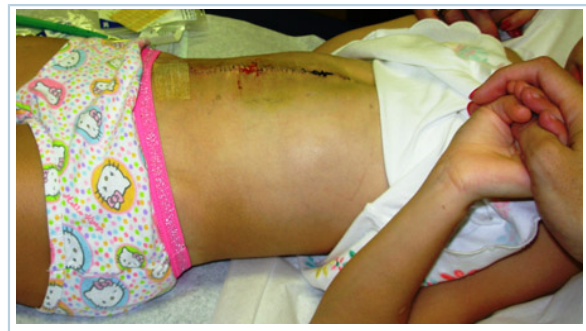*From collection of J.J.
Tepas III, MD, FACS, FAAP*

Acute



A ventral hernia results from synthetic wall closure of the omphalocele

From collection of J.J. Tepas III, MD, FACS, FAAP



The ventral hernia is repaired in a 6-year-old girl born with omphalocele

From collection of J.J. Tepas III, MD, FACS, FAAP

■ **ruptured membranous sac: small defect**

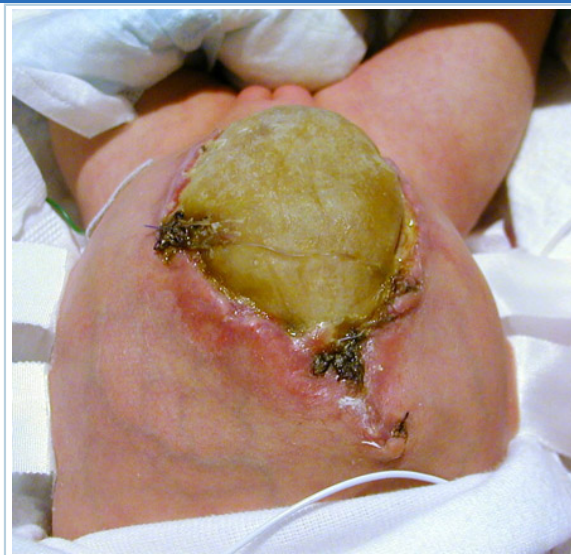plus

bowel protection

Treatment recommended for ALL patients in selected patient group

» If the membranous sac is not intact, a sterile covering or a clear bowel bag must be placed over the herniated abdominal contents to prevent evaporation, heat loss, and infection.^[34]

Acute



The abdominal wall defect in omphalocele is covered with a synthetic membrane

From collection of J.J.

Tepas III, MD, FACS, FAAP

■ ruptured membranous sac: large defect and/or extensive herniation

plus **primary surgical repair**

Treatment recommended for ALL patients in selected patient group

» Small defects may be treated with primary surgical repair.[35]

plus **postsurgical nasogastric tube and parenteral nutrition**

Treatment recommended for ALL patients in selected patient group

» Surgery is followed by a trial of a nasogastric tube for decompression of the bowel and total parenteral nutrition while the inflammatory peel resolves.

plus **staged reduction and surgical repair**

Treatment recommended for ALL patients in selected patient group

» Larger defects or those with extensive herniation of abdominal contents require a staged approach with placement of the abdominal contents into a suspended silo and gradual reduction into the abdominal cavity.[35] Ventilatory support is often required during this process. Once the abdominal contents have been fully reduced into the abdominal cavity, the fascia and skin are surgically closed.

plus **postsurgical nasogastric tube and parenteral nutrition**

Treatment recommended for ALL patients in selected patient group

Acute

» Surgery is followed by a trial of a nasogastric tube for decompression of the bowel and total parenteral nutrition while the inflammatory peel resolves.

Primary prevention

As the etiology of gastroschisis and omphalocele is unclear, it is difficult to develop preventive strategies. Some evidence suggests multivitamins during pregnancy may prevent omphalocele, but this is not strongly supported.^[12] Other data suggest that avoiding recreational drugs during pregnancy may prevent the development of these abdominal wall defects.^{[11] [13] [14] [15]} Smoking during pregnancy has also been associated with the development of gastroschisis and omphalocele, and should be strongly discouraged.

Patient discussions

It is important that parents monitor the weight gain and nutritional status of the infant. Lifestyle modification of the infant is usually not indicated. Many support groups exist for parents of children with abdominal wall defects. [American Pediatric Surgical Association] (<http://www.eapsa.org>)

Monitoring

Monitoring

Monitoring of infants following the repair of abdominal wall defects involves close follow-up to monitor weight gain, nutrition, and feeding patterns. Some infants are slow to feed after repair of gastroschisis and it is important to closely monitor their postoperative nutritional status. Additional imaging studies and functional tests are not required for these conditions, although such investigations may be necessary for the evaluation of anomalies associated with omphalocele, particularly cardiac anomalies.

Complications

Complications	Timeframe	Likelihood
wound infection	short term	medium
<p>As treatment of gastroschisis and omphalocele often involves staged or repeated surgical procedures with manipulation of incisions at the umbilicus or surrounding skin, localized infection or necrosis of the skin edge may occur.</p> <p>These complications respond quickly to routine wound care, usually healing completely within weeks or even days.</p>		
persistent bowel dysfunction	short term	medium
<p>The exposure of the extruded gut to amniotic fluid in gastroschisis causes inflammation that often produces a persistent dysmotility. In the vast majority of cases this temporary phenomenon resolves over time.</p>		
bowel obstruction	variable	low
<p>Approximately 15% of infants with gastroschisis will develop signs of bowel obstruction at some point later in life, especially in the first year after treatment, partly due to the very common occurrence of intestinal malrotation associated with abdominal wall defects.[40] [41]</p> <p>Initial management should involve simple nasogastric decompression; however, occasionally surgical re-exploration is required.</p>		
necrotizing enterocolitis	variable	low
<p>Infants with gastroschisis may have impaired intestinal perfusion and, as such, may be at risk of gut ischemia that can progress to neonatal necrotizing enterocolitis. This occurs in 2% to 18% of infants and is often associated with other risk factors such as very low birth weight, pulmonary insufficiency, and hypotension.[42]</p>		
complications of total parenteral nutrition (TPN)	variable	low
<p>While the gut recovers, the infant requires intravenous alimentation, which is delivered via a peripherally inserted central catheter or central venous catheter. Both of these routes of administration are at risk of becoming infected if not handled with careful and strict sterile technique.</p> <p>If intestinal function is slow to recover and the infant is dependent on intravenous alimentation, hepatitis, and liver failure may develop as a result of prolonged TPN dependence. Infants who are TPN dependent may have short gut syndrome.</p>		
cholestatic jaundice	variable	low
<p>In gastroschisis, as the dyskinetic gut requires parenteral alimentation, the possibility of cholestatic jaundice persists.</p>		

Complications	Timeframe	Likelihood
short bowel syndrome	variable	low
In gastroschisis, if the acute injury is associated with ischemic damage that destroys enough of the extruded gut, short bowel syndrome (also known as short gut syndrome) may develop. Infants who are TPN dependent may have short bowel syndrome.		

Prognosis

The course and prognosis for gastroschisis and omphalocele depend on the severity of the defect and accompanying anomalies. Major malformations and chromosomal anomalies are common with omphalocele but rare in gastroschisis, with the exception of intestinal atresia. Advances in intensive care practices and postnatal resuscitation have decreased the mortality and morbidity associated with abdominal wall defects.

Gastroschisis

Reported survival rates in gastroschisis range from 91% to 100%, although the condition is associated with lengthy hospital stays.[36] [5] Prenatal intestinal insult may contribute to small bowel atresia, bowel infarction, and intestinal motility dysfunction. If the insult to the intestine is severe, short gut syndrome may lead to the need for prolonged hyperalimentation and associated complications of total parenteral nutrition, including hepatitis. After closure, infants may develop intestinal obstruction from atresia, bowel perforations, or peritonitis. Additional operative intervention may prolong the hospital stay and delay opportunities to feed orally prior to discharge. The most important prognostic factor for morbidity is the presence of intestinal atresia; preterm delivery and very low birthweight are also associated with worse clinical outcomes.[37]

Omphalocele

If omphalocele is not accompanied by additional structural abnormalities or chromosomal defects, the prognosis is good, with a low mortality.[38] However, associated congenital heart disease, genetic syndromes, and intestinal problems are common with omphalocele, and the condition is associated with anomalies in other organ systems in 30% to 80% of cases, with the severity of the anomalies dictating prognosis.[39] Most omphaloceles are associated with cardiac and chromosomal anomalies, and more than one half of the fetuses will die. Infections, surgical complications, and low birth weight are responsible for many deaths. Infections, immaturity, hernia rupture, and intestinal obstruction rates are high.

Treatment guidelines

International

Gastroschisis: management prior to transfer to surgical centre (<https://www.hse.ie/eng/about/who/cspd/ncps/paediatrics-neonatology/resources>) [33]

Published by: Health Service Executive Ireland

Last published: 2020

Gastroschisis (<https://www.caahs.health.wa.gov.au/For-health-professionals/Resources/Neonatology-guidelines>) [32]

Published by: Government of Western Australia

Last published: 2021

Online resources

1. [American Pediatric Surgical Association \(http://www.eapsa.org\)](http://www.eapsa.org) (*external link*)

Key articles

- Torfs CP, Velie EM, Oechsli FW, et al. A population-based study of gastroschisis: demographic, pregnancy, and lifestyle risk factors. *Teratology*. 1994 Jul;50(1):44-53. [Abstract \(http://www.ncbi.nlm.nih.gov/pubmed/7974254?tool=bestpractice.bmj.com\)](http://www.ncbi.nlm.nih.gov/pubmed/7974254?tool=bestpractice.bmj.com)
- Langer JC, Harrison MR, Adzick NS, et al. Perinatal management of the fetus with an abdominal wall defect. *Fetal Ther*. 1987;2(4):216-21. [Abstract \(http://www.ncbi.nlm.nih.gov/pubmed/2978282?tool=bestpractice.bmj.com\)](http://www.ncbi.nlm.nih.gov/pubmed/2978282?tool=bestpractice.bmj.com)
- Glick PL, Harrison MR, Adzick NS, et al. The missing link in the pathogenesis of gastroschisis. *J Pediatr Surg*. 1985;20:406-9. [Abstract \(http://www.ncbi.nlm.nih.gov/pubmed/2931510?tool=bestpractice.bmj.com\)](http://www.ncbi.nlm.nih.gov/pubmed/2931510?tool=bestpractice.bmj.com)
- Snyder CL. Current management of umbilical abnormalities and related anomalies. *Semin Pediatr Surg*. 2007 Feb;16(1):41-9. [Abstract \(http://www.ncbi.nlm.nih.gov/pubmed/17210482?tool=bestpractice.bmj.com\)](http://www.ncbi.nlm.nih.gov/pubmed/17210482?tool=bestpractice.bmj.com)
- Sipes SL, Weiner CP, Sipes DR 2nd, et al. Gastroschisis and omphalocele: does either antenatal diagnosis or route of delivery make a difference in perinatal outcome? *Obstet Gynecol*. 1990 Aug;76(2):195-9. [Abstract \(http://www.ncbi.nlm.nih.gov/pubmed/2142521?tool=bestpractice.bmj.com\)](http://www.ncbi.nlm.nih.gov/pubmed/2142521?tool=bestpractice.bmj.com)

References

1. deVries PA. The pathogenesis of gastroschisis and omphalocele. *J Pediatr Surg*. 1980 Jun;15(3):245-51. [Abstract \(http://www.ncbi.nlm.nih.gov/pubmed/6445962?tool=bestpractice.bmj.com\)](http://www.ncbi.nlm.nih.gov/pubmed/6445962?tool=bestpractice.bmj.com)
2. Torfs C, Curry C, Roeper P. Gastroschisis. *J Pediatr*. 1990 Jan;116(1):1-6. [Abstract \(http://www.ncbi.nlm.nih.gov/pubmed/2136909?tool=bestpractice.bmj.com\)](http://www.ncbi.nlm.nih.gov/pubmed/2136909?tool=bestpractice.bmj.com)
3. Nichols CR, Dickinson JE, Pemberton PJ. Rising incidence of gastroschisis in teenage pregnancies. *J Matern Fetal Med*. 1997 Jul-Aug;6(4):225-9. [Abstract \(http://www.ncbi.nlm.nih.gov/pubmed/9260121?tool=bestpractice.bmj.com\)](http://www.ncbi.nlm.nih.gov/pubmed/9260121?tool=bestpractice.bmj.com)
4. Werler MM, Mitchell AA, Shapiro S. Demographic, reproductive, medical and environmental factors in relation to gastroschisis. *Teratology*. 1992 Apr;45(4):353-60. [Abstract \(http://www.ncbi.nlm.nih.gov/pubmed/1533957?tool=bestpractice.bmj.com\)](http://www.ncbi.nlm.nih.gov/pubmed/1533957?tool=bestpractice.bmj.com)
5. Molik KA, Gingalewski CA, West KW, et al. Gastroschisis: a plea for risk categorization. *J Pediatr Surg*. 2001 Jan;36(1):51-5. [Abstract \(http://www.ncbi.nlm.nih.gov/pubmed/11150437?tool=bestpractice.bmj.com\)](http://www.ncbi.nlm.nih.gov/pubmed/11150437?tool=bestpractice.bmj.com)
6. Davis RP, Treadwell MC, Drongowski RA, et al. Risk stratification in gastroschisis: can prenatal evaluation or early postnatal factors predict outcome? *Pediatr Surg Int*. 2009 Apr;25(4):319-25. [Abstract \(http://www.ncbi.nlm.nih.gov/pubmed/19277683?tool=bestpractice.bmj.com\)](http://www.ncbi.nlm.nih.gov/pubmed/19277683?tool=bestpractice.bmj.com)

7. Al-Salem AH. Omphalocele. In: An illustrated guide to pediatric surgery. 1st ed. Cham, Switzerland: Springer International; 2014:253-9. [Full text \(https://link.springer.com/chapter/10.1007/978-3-319-06665-3_37\)](https://link.springer.com/chapter/10.1007/978-3-319-06665-3_37)
8. Moore TC. Omphalomesenteric duct malformations. *Semin Pediatr Surg.* 1996 May;5(2):116-23. [Abstract \(http://www.ncbi.nlm.nih.gov/pubmed/9138710?tool=bestpractice.bmj.com\)](http://www.ncbi.nlm.nih.gov/pubmed/9138710?tool=bestpractice.bmj.com)
9. Salihu HM, Boos R, Schmidt W. Omphalocele and gastroschisis. *J Obstet Gynaecol.* 2002 Sep;22(5):489-92. [Abstract \(http://www.ncbi.nlm.nih.gov/pubmed/12521414?tool=bestpractice.bmj.com\)](http://www.ncbi.nlm.nih.gov/pubmed/12521414?tool=bestpractice.bmj.com)
10. Salihu HM, Emusu D, Aliyu ZY, et al. Omphalocele, advanced maternal age, and fetal morbidity outcomes. *Am J Med Genet A.* 2005 Jun 1;135(2):161-5. [Abstract \(http://www.ncbi.nlm.nih.gov/pubmed/15887299?tool=bestpractice.bmj.com\)](http://www.ncbi.nlm.nih.gov/pubmed/15887299?tool=bestpractice.bmj.com)
11. Draper ES, Rankin J, Tonks AM, et al. Recreational drug use: a major risk factor for gastroschisis? *Am J Epidemiol.* 2008 Feb 15;167(4):485-91. [Full text \(http://aje.oxfordjournals.org/content/167/4/485.full\)](http://aje.oxfordjournals.org/content/167/4/485.full) [Abstract \(http://www.ncbi.nlm.nih.gov/pubmed/18063593?tool=bestpractice.bmj.com\)](http://www.ncbi.nlm.nih.gov/pubmed/18063593?tool=bestpractice.bmj.com)
12. Botto LD, Mulinare J, Erickson JD. Occurrence of omphalocele in relation to maternal multivitamin use: a population-based study. *Pediatrics.* 2002 May;109(5):904-8. [Abstract \(http://www.ncbi.nlm.nih.gov/pubmed/11986454?tool=bestpractice.bmj.com\)](http://www.ncbi.nlm.nih.gov/pubmed/11986454?tool=bestpractice.bmj.com)
13. Torfs CP, Velie EM, Oechsli FW, et al. A population-based study of gastroschisis: demographic, pregnancy, and lifestyle risk factors. *Teratology.* 1994 Jul;50(1):44-53. [Abstract \(http://www.ncbi.nlm.nih.gov/pubmed/7974254?tool=bestpractice.bmj.com\)](http://www.ncbi.nlm.nih.gov/pubmed/7974254?tool=bestpractice.bmj.com)
14. Goldbaum G, Daling J, Milham S. Risk factors for gastroschisis. *Teratology.* 1990 Oct;42(4):397-403. [Abstract \(http://www.ncbi.nlm.nih.gov/pubmed/2147789?tool=bestpractice.bmj.com\)](http://www.ncbi.nlm.nih.gov/pubmed/2147789?tool=bestpractice.bmj.com)
15. Laughon M, Meyer R, Bose C, et al. Rising birth prevalence of gastroschisis. *J Perinatol.* 2003 Jun;23(4):291-3. [Full text \(http://www.nature.com/jp/journal/v23/n4/full/7210896a.html\)](http://www.nature.com/jp/journal/v23/n4/full/7210896a.html) [Abstract \(http://www.ncbi.nlm.nih.gov/pubmed/12774135?tool=bestpractice.bmj.com\)](http://www.ncbi.nlm.nih.gov/pubmed/12774135?tool=bestpractice.bmj.com)
16. Feldkamp ML, Reefhuis J, Kucik J, et al. Case-control study of self reported genitourinary infections and risk of gastroschisis: findings from the national birth defects prevention study, 1997-2003. *BMJ.* 2008 Jun 21;336(7658):1420-3. [Full text \(http://www.bmj.com/content/336/7658/1420.full\)](http://www.bmj.com/content/336/7658/1420.full) [Abstract \(http://www.ncbi.nlm.nih.gov/pubmed/18558640?tool=bestpractice.bmj.com\)](http://www.ncbi.nlm.nih.gov/pubmed/18558640?tool=bestpractice.bmj.com)
17. Langer JC, Harrison MR, Adzick NS, et al. Perinatal management of the fetus with an abdominal wall defect. *Fetal Ther.* 1987;2(4):216-21. [Abstract \(http://www.ncbi.nlm.nih.gov/pubmed/2978282?tool=bestpractice.bmj.com\)](http://www.ncbi.nlm.nih.gov/pubmed/2978282?tool=bestpractice.bmj.com)
18. Hoyme HE, Jones MC, Jones KL. Gastroschisis: abdominal wall disruption secondary to early gestational interruption of the omphalomesenteric artery. *Semin Perinatol.* 1983;7:294-8. [Abstract \(http://www.ncbi.nlm.nih.gov/pubmed/6229032?tool=bestpractice.bmj.com\)](http://www.ncbi.nlm.nih.gov/pubmed/6229032?tool=bestpractice.bmj.com)

19. Glick PL, Harrison MR, Adzick NS, et al. The missing link in the pathogenesis of gastroschisis. *J Pediatr Surg*. 1985;20:406-9. [Abstract \(http://www.ncbi.nlm.nih.gov/pubmed/2931510?tool=bestpractice.bmj.com\)](http://www.ncbi.nlm.nih.gov/pubmed/2931510?tool=bestpractice.bmj.com)
20. Snyder CL. Current management of umbilical abnormalities and related anomalies. *Semin Pediatr Surg*. 2007 Feb;16(1):41-9. [Abstract \(http://www.ncbi.nlm.nih.gov/pubmed/17210482?tool=bestpractice.bmj.com\)](http://www.ncbi.nlm.nih.gov/pubmed/17210482?tool=bestpractice.bmj.com)
21. Palomaki GE, Hill LE, Knight GJ, et al. Second-trimester maternal serum alpha-fetoprotein levels in pregnancies associated with gastroschisis and omphalocele. *Obstet Gynecol*. 1988 Jun;71(6 Pt 1):906-9. [Abstract \(http://www.ncbi.nlm.nih.gov/pubmed/2453005?tool=bestpractice.bmj.com\)](http://www.ncbi.nlm.nih.gov/pubmed/2453005?tool=bestpractice.bmj.com)
22. Martin RW. Screening for fetal abdominal wall defects. *Obstet Gynecol Clin North Am*. 1998 Sep;25(3):517-26. [Abstract \(http://www.ncbi.nlm.nih.gov/pubmed/9710909?tool=bestpractice.bmj.com\)](http://www.ncbi.nlm.nih.gov/pubmed/9710909?tool=bestpractice.bmj.com)
23. Kirk EP, Wah RM. Obstetric management of the fetus with omphalocele or gastroschisis; a review and report of one hundred twelve cases. *Am J Obstet Gynecol*. 1983 Jul 1;146(5):512-8. [Abstract \(http://www.ncbi.nlm.nih.gov/pubmed/6222654?tool=bestpractice.bmj.com\)](http://www.ncbi.nlm.nih.gov/pubmed/6222654?tool=bestpractice.bmj.com)
24. Wilson RD, Johnson MP. Congenital abdominal wall defects: an update. *Fetal Diagn Ther*. 2004 Sep-Oct;19(5):385-98. [Full text \(https://www.doi.org/10.1159/000078990\)](https://www.doi.org/10.1159/000078990) [Abstract \(http://www.ncbi.nlm.nih.gov/pubmed/15305094?tool=bestpractice.bmj.com\)](http://www.ncbi.nlm.nih.gov/pubmed/15305094?tool=bestpractice.bmj.com)
25. St-Vil D, Shaw KS, Lallier M, et al. Chromosomal anomalies in newborns with omphalocele. *J Pediatr Surg*. 1996 Jun;31(6):831-4. [Full text \(https://www.doi.org/10.1016/s0022-3468\(96\)90146-3\)](https://www.doi.org/10.1016/s0022-3468(96)90146-3) [Abstract \(http://www.ncbi.nlm.nih.gov/pubmed/8783116?tool=bestpractice.bmj.com\)](http://www.ncbi.nlm.nih.gov/pubmed/8783116?tool=bestpractice.bmj.com)
26. Feldkamp ML, Botto LD, Amar E, et al. Cloacal exstrophy: an epidemiologic study from the International Clearinghouse for Birth Defects Surveillance and Research. *Am J Med Genet C Semin Med Genet*. 2011 Nov 15;157C(4):333-43. [Full text \(https://www.doi.org/10.1002/ajmg.c.30317\)](https://www.doi.org/10.1002/ajmg.c.30317) [Abstract \(http://www.ncbi.nlm.nih.gov/pubmed/22002951?tool=bestpractice.bmj.com\)](http://www.ncbi.nlm.nih.gov/pubmed/22002951?tool=bestpractice.bmj.com)
27. Calisti A, Manzoni C, Perrelli L. The fetus with an abdominal wall defect: management and outcome. *J Perinat Med*. 1987;15(1):105-11. [Abstract \(http://www.ncbi.nlm.nih.gov/pubmed/2953877?tool=bestpractice.bmj.com\)](http://www.ncbi.nlm.nih.gov/pubmed/2953877?tool=bestpractice.bmj.com)
28. Lewis DF, Towers CV, Garite TJ, et al. Fetal gastroschisis and omphalocele: is cesarean section the best mode of delivery? *Am J Obstet Gynecol*. 1990 Sep;163(3):773-5. [Abstract \(http://www.ncbi.nlm.nih.gov/pubmed/2144949?tool=bestpractice.bmj.com\)](http://www.ncbi.nlm.nih.gov/pubmed/2144949?tool=bestpractice.bmj.com)
29. Moretti M, Khoury A, Rodriguez J, et al. The effect of mode of delivery on the perinatal outcome in fetuses with abdominal wall defects. *Am J Obstet Gynecol*. 1990 Sep;163(3):833-8. [Abstract \(http://www.ncbi.nlm.nih.gov/pubmed/2144950?tool=bestpractice.bmj.com\)](http://www.ncbi.nlm.nih.gov/pubmed/2144950?tool=bestpractice.bmj.com)
30. Sipes SL, Weiner CP, Sipes DR 2nd, et al. Gastroschisis and omphalocele: does either antenatal diagnosis or route of delivery make a difference in perinatal outcome? *Obstet Gynecol*. 1990 Aug;76(2):195-9. [Abstract \(http://www.ncbi.nlm.nih.gov/pubmed/2142521?tool=bestpractice.bmj.com\)](http://www.ncbi.nlm.nih.gov/pubmed/2142521?tool=bestpractice.bmj.com)

31. Waldhausen JHT. Surgical management of gastroschisis. *Pediatrics*. 2005 Nov 01;6(11):e500–7. [Full text \(https://publications.aap.org/neoreviews/article-abstract/6/11/e500/87160/Surgical-Management-of-Gastroschisis?redirectedFrom=fulltext\)](https://publications.aap.org/neoreviews/article-abstract/6/11/e500/87160/Surgical-Management-of-Gastroschisis?redirectedFrom=fulltext)
32. Government of Western Australia Child and Adolescent Health Service. Gastroschisis. Aug 2008 [internet publication]. [Full text \(https://www.caahs.health.wa.gov.au/-/media/HSPs/CAHS/Documents/Health-Professionals/Neonatology-guidelines/Gastroschisis.pdf\)](https://www.caahs.health.wa.gov.au/-/media/HSPs/CAHS/Documents/Health-Professionals/Neonatology-guidelines/Gastroschisis.pdf)
33. Moran M, Mortell A. Gastroschisis: management prior to transfer to surgical centre. Sep 2020 [internet publication]. [Full text \(https://www.hse.ie/eng/about/who/cspd/ncps/paediatrics-neonatology/resources/national-clinical-guideline-gastroschisis.pdf\)](https://www.hse.ie/eng/about/who/cspd/ncps/paediatrics-neonatology/resources/national-clinical-guideline-gastroschisis.pdf)
34. Bielicki IN, Somme S, Frongia G, et al. Abdominal wall defects-current treatments. *Children (Basel)*. 2021 Feb 23;8(2):170. [Full text \(https://www.doi.org/10.3390/children8020170\)](https://www.doi.org/10.3390/children8020170) [Abstract \(http://www.ncbi.nlm.nih.gov/pubmed/33672248?tool=bestpractice.bmj.com\)](http://www.ncbi.nlm.nih.gov/pubmed/33672248?tool=bestpractice.bmj.com)
35. Skarsgard ED. Immediate versus staged repair of omphaloceles. *Semin Pediatr Surg*. 2019 Apr;28(2):89-94. [Full text \(https://www.doi.org/10.1053/j.sempedsurg.2019.04.010\)](https://www.doi.org/10.1053/j.sempedsurg.2019.04.010) [Abstract \(http://www.ncbi.nlm.nih.gov/pubmed/31072464?tool=bestpractice.bmj.com\)](http://www.ncbi.nlm.nih.gov/pubmed/31072464?tool=bestpractice.bmj.com)
36. Snyder CL. Outcome analysis for gastroschisis. *J Pediatr Surg*. 1999 Aug;34(8):1253-6. [Full text \(https://www.jpedsurg.org/article/S0022-3468\(99\)90162-8/pdf\)](https://www.jpedsurg.org/article/S0022-3468(99)90162-8/pdf) [Abstract \(http://www.ncbi.nlm.nih.gov/pubmed/10466606?tool=bestpractice.bmj.com\)](http://www.ncbi.nlm.nih.gov/pubmed/10466606?tool=bestpractice.bmj.com)
37. Raymond SL, Hawkins RB, St Peter SD, et al. Predicting morbidity and mortality in neonates born with gastroschisis. *J Surg Res*. 2020 Jan;245:217-24. [Full text \(https://www.doi.org/10.1016/j.jss.2019.07.065\)](https://www.doi.org/10.1016/j.jss.2019.07.065) [Abstract \(http://www.ncbi.nlm.nih.gov/pubmed/31421366?tool=bestpractice.bmj.com\)](http://www.ncbi.nlm.nih.gov/pubmed/31421366?tool=bestpractice.bmj.com)
38. Fogelström A, Caldeman C, Oddsberg J, et al. Omphalocele: national current birth prevalence and survival. *Pediatr Surg Int*. 2021 Nov;37(11):1515-20. [Full text \(https://www.doi.org/10.1007/s00383-021-04978-z\)](https://www.doi.org/10.1007/s00383-021-04978-z) [Abstract \(http://www.ncbi.nlm.nih.gov/pubmed/34392395?tool=bestpractice.bmj.com\)](http://www.ncbi.nlm.nih.gov/pubmed/34392395?tool=bestpractice.bmj.com)
39. Poaty H, Pelluard F, Lucienne IP, et al. Omphalocele: a review of common genetic etiologies. *Egypt J Med Hum Genet*. 2019 Dec 27;20(37). [Full text \(https://jmhg.springeropen.com/articles/10.1186/s43042-019-0040-3\)](https://jmhg.springeropen.com/articles/10.1186/s43042-019-0040-3)
40. South AP, Wessel JJ, Sberna A, et al. Hospital readmission among infants with gastroschisis. *J Perinatol*. 2011 Aug;31(8):546-50. [Full text \(https://www.doi.org/10.1038/jp.2010.206\)](https://www.doi.org/10.1038/jp.2010.206) [Abstract \(http://www.ncbi.nlm.nih.gov/pubmed/21311496?tool=bestpractice.bmj.com\)](http://www.ncbi.nlm.nih.gov/pubmed/21311496?tool=bestpractice.bmj.com)
41. van Eijck FC, Wijnen RM, van Goor H. The incidence and morbidity of adhesions after treatment of neonates with gastroschisis and omphalocele: a 30-year review. *J Pediatr Surg*. 2008 Mar;43(3):479-83. [Full text \(https://www.doi.org/10.1016/j.jpedsurg.2007.10.027\)](https://www.doi.org/10.1016/j.jpedsurg.2007.10.027) [Abstract \(http://www.ncbi.nlm.nih.gov/pubmed/18358285?tool=bestpractice.bmj.com\)](http://www.ncbi.nlm.nih.gov/pubmed/18358285?tool=bestpractice.bmj.com)

42. Riggle KM, Davis JL, Drugas GT, et al. Fatal clostridial necrotizing enterocolitis in a term infant with gastroschisis. J Pediatr surg. 2016 Nov;14:29-31. [Full text \(https://www.sciencedirect.com/science/article/pii/S2213576616301154#bib3\)](https://www.sciencedirect.com/science/article/pii/S2213576616301154#bib3)

Images

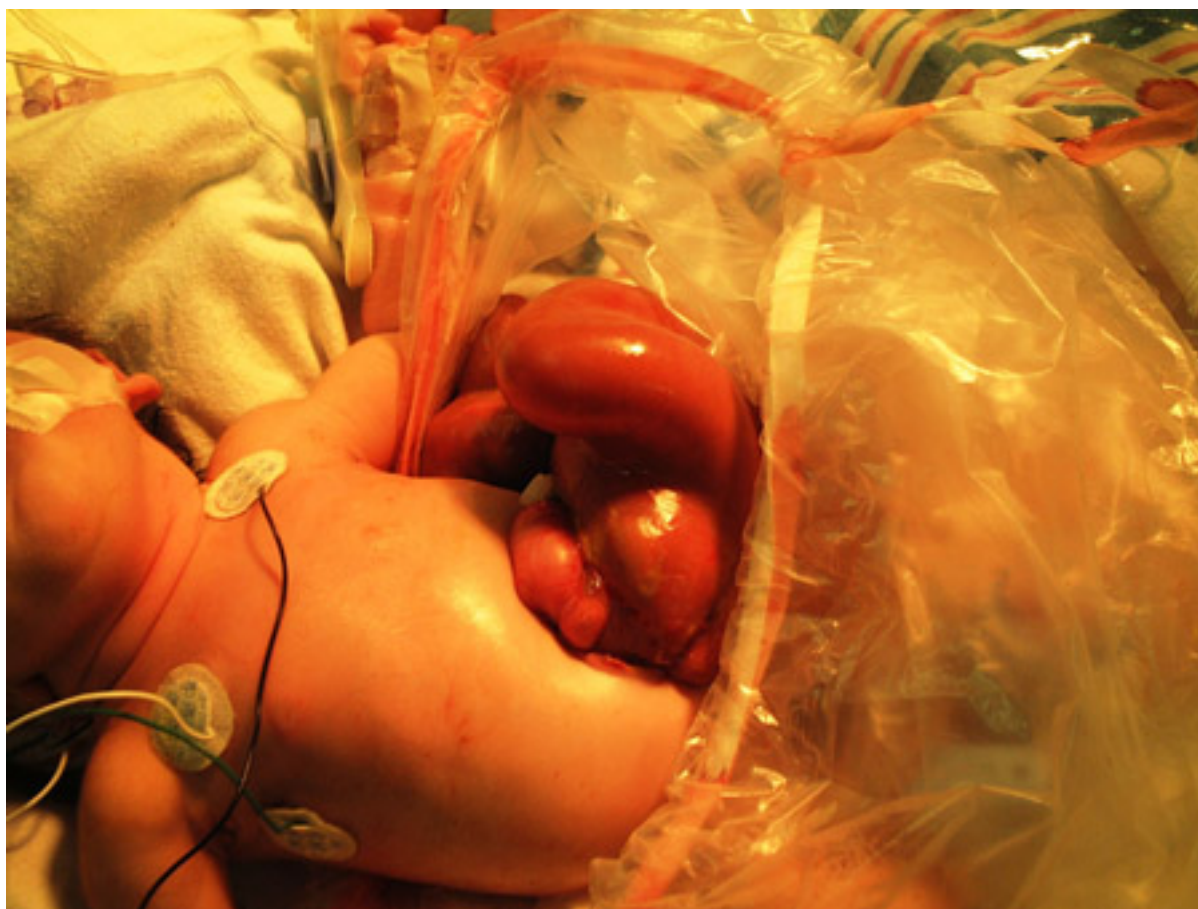

Figure 1: Immediately after delivery, an infant with gastroschisis is placed in a protective bowel bag

From collection of J.J. Tepas III, MD, FACS, FAAP

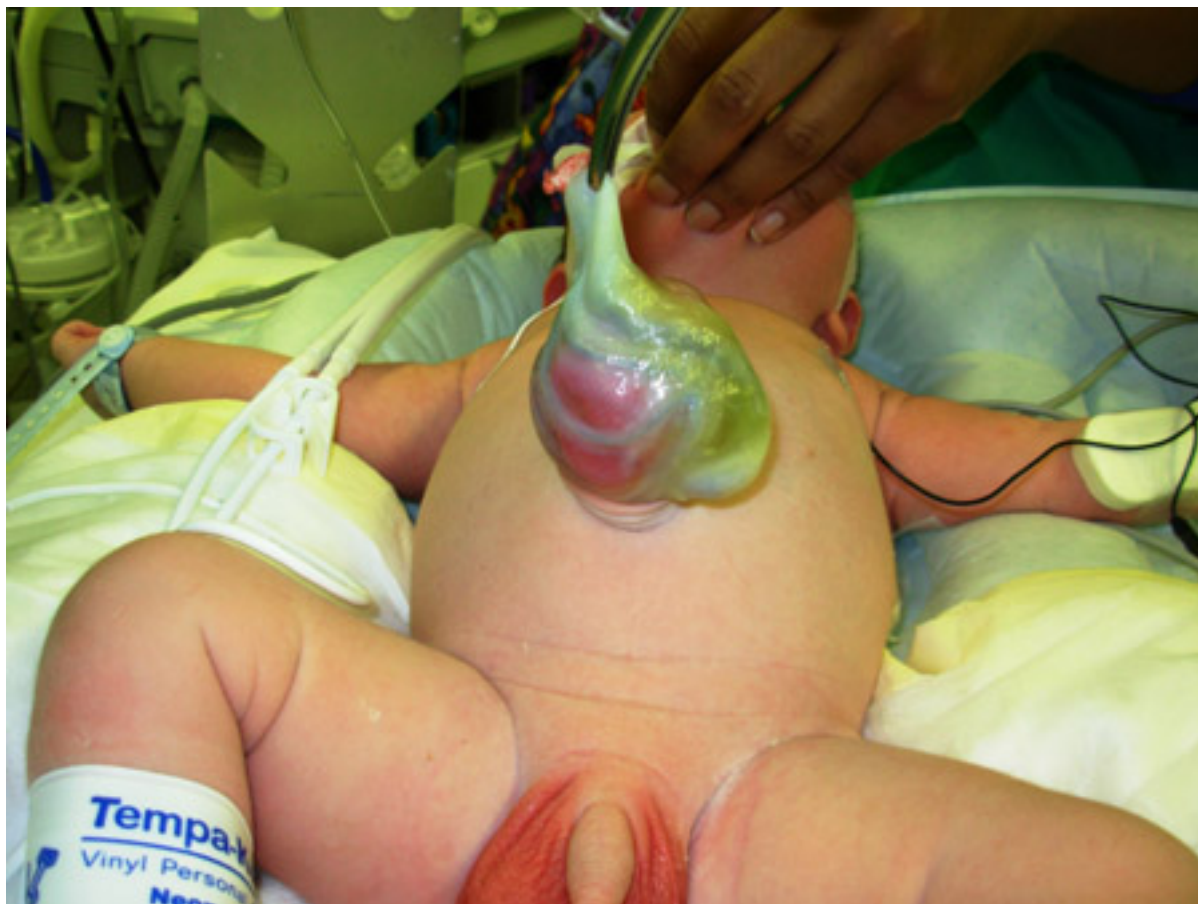

Figure 2: Note the membrane covering the abdominal contents in this omphalocele

From collection of J.J. Tepas III, MD, FACS, FAAP

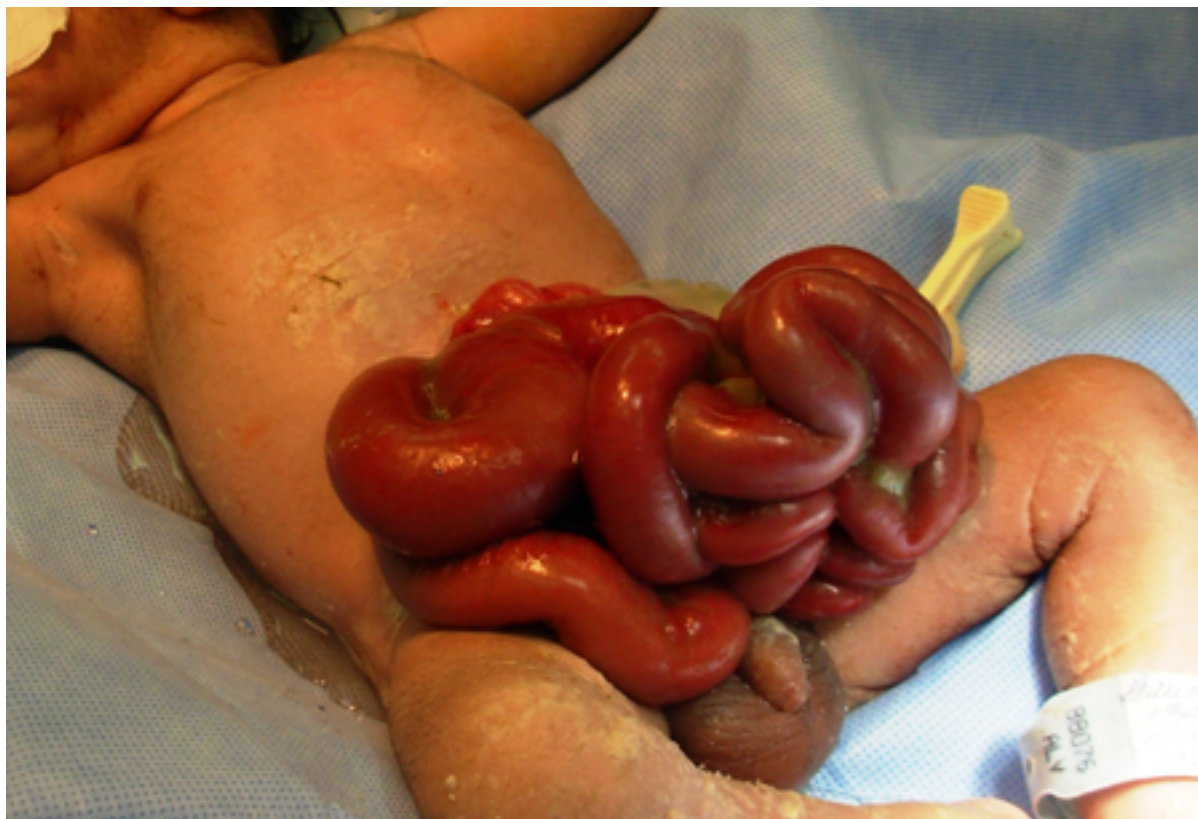

Figure 3: Extruded gut in abdominal wall defect

From collection of J.J. Tepas III, MD, FACS, FAAP

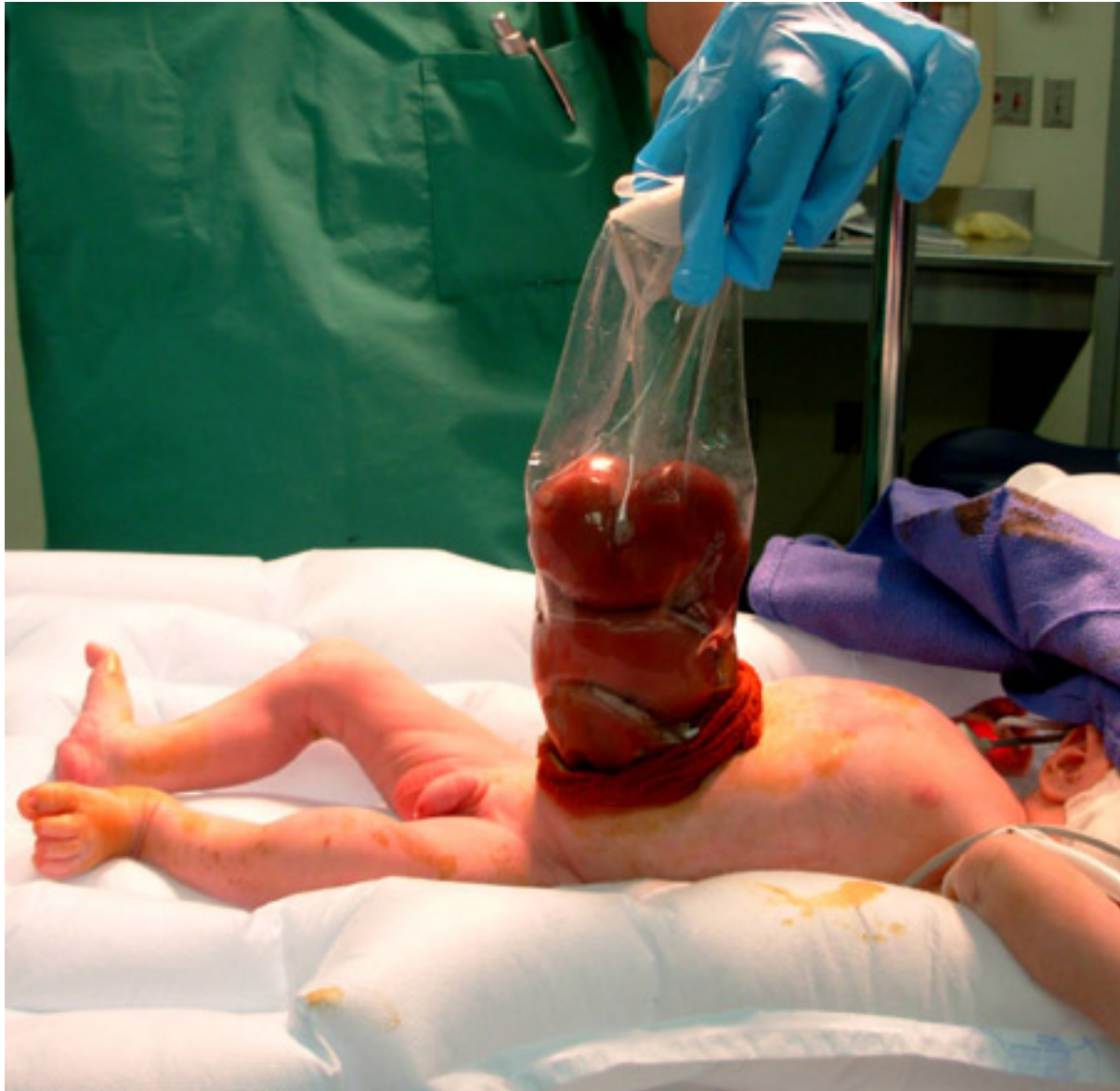

Figure 4: A staged repair of gastroschisis involves the placement of a silo to reduce contents into the abdomen

From collection of J.J. Tepas III, MD, FACS, FAAP

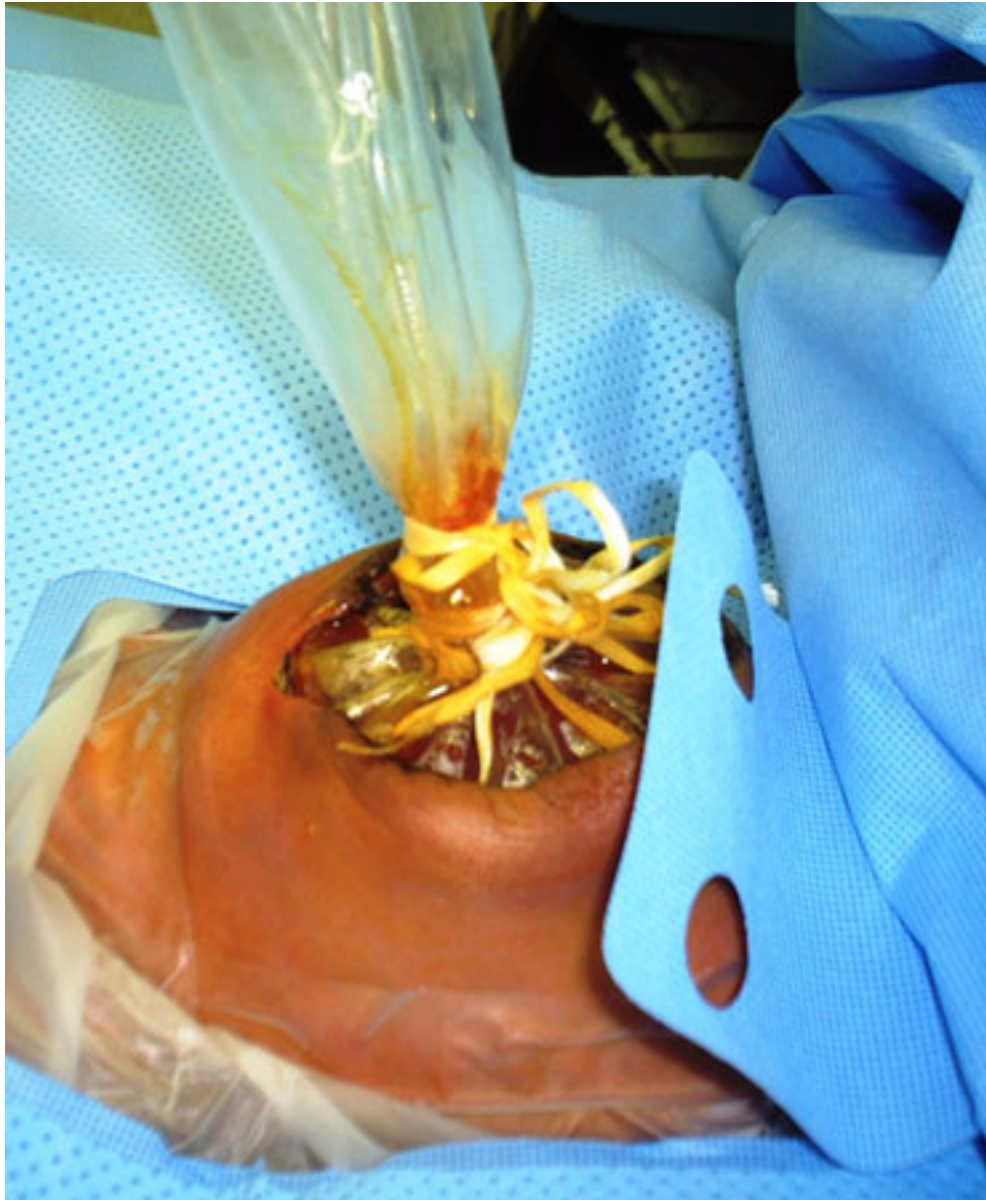

Figure 5: Once intestinal contents are fully reduced into the abdomen, closure of the abdominal wall follows

From collection of J.J. Tepas III, MD, FACS, FAAP

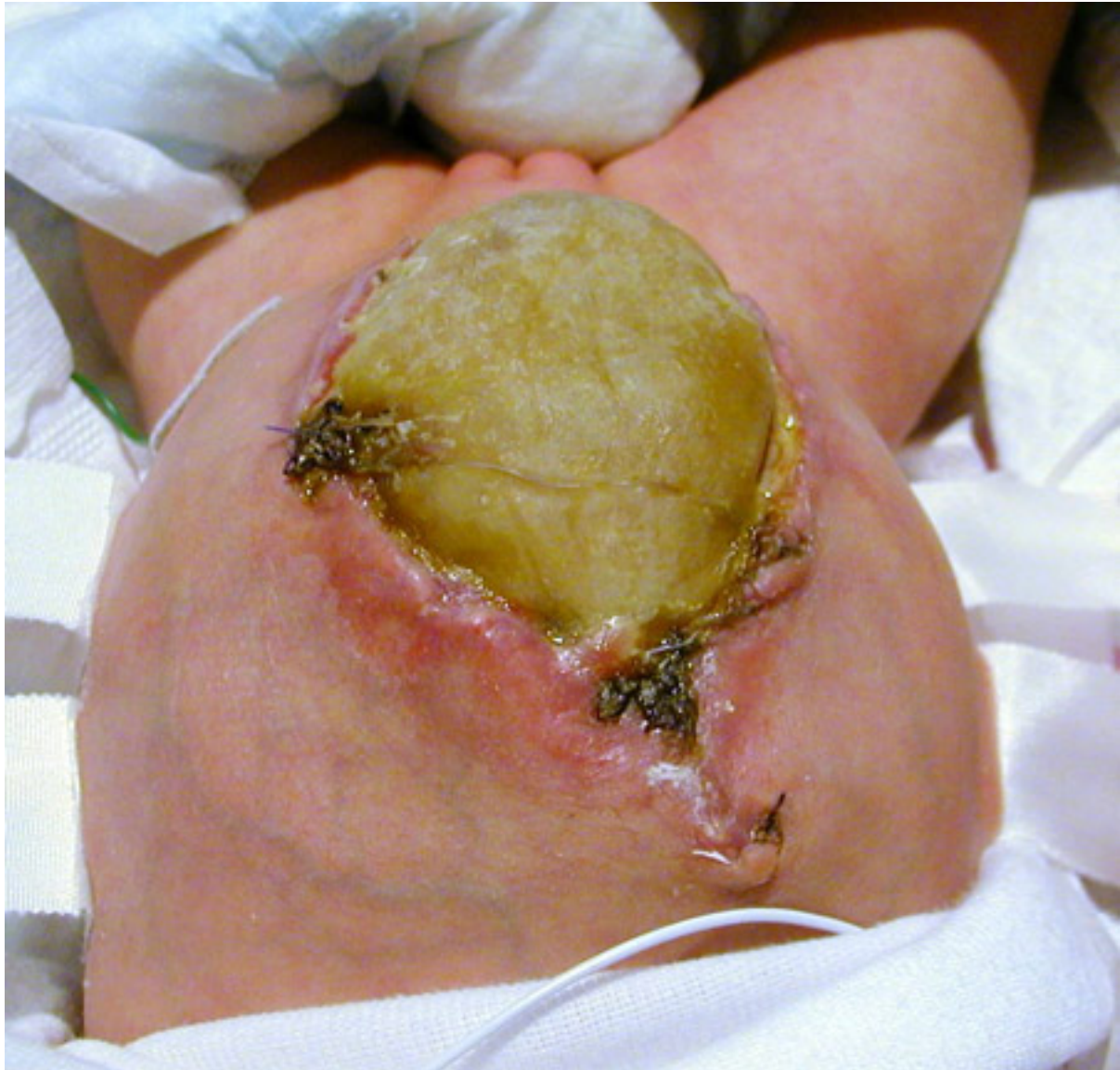

Figure 6: The abdominal wall defect in omphalocele is covered with a synthetic membrane

From collection of J.J. Tepas III, MD, FACS, FAAP

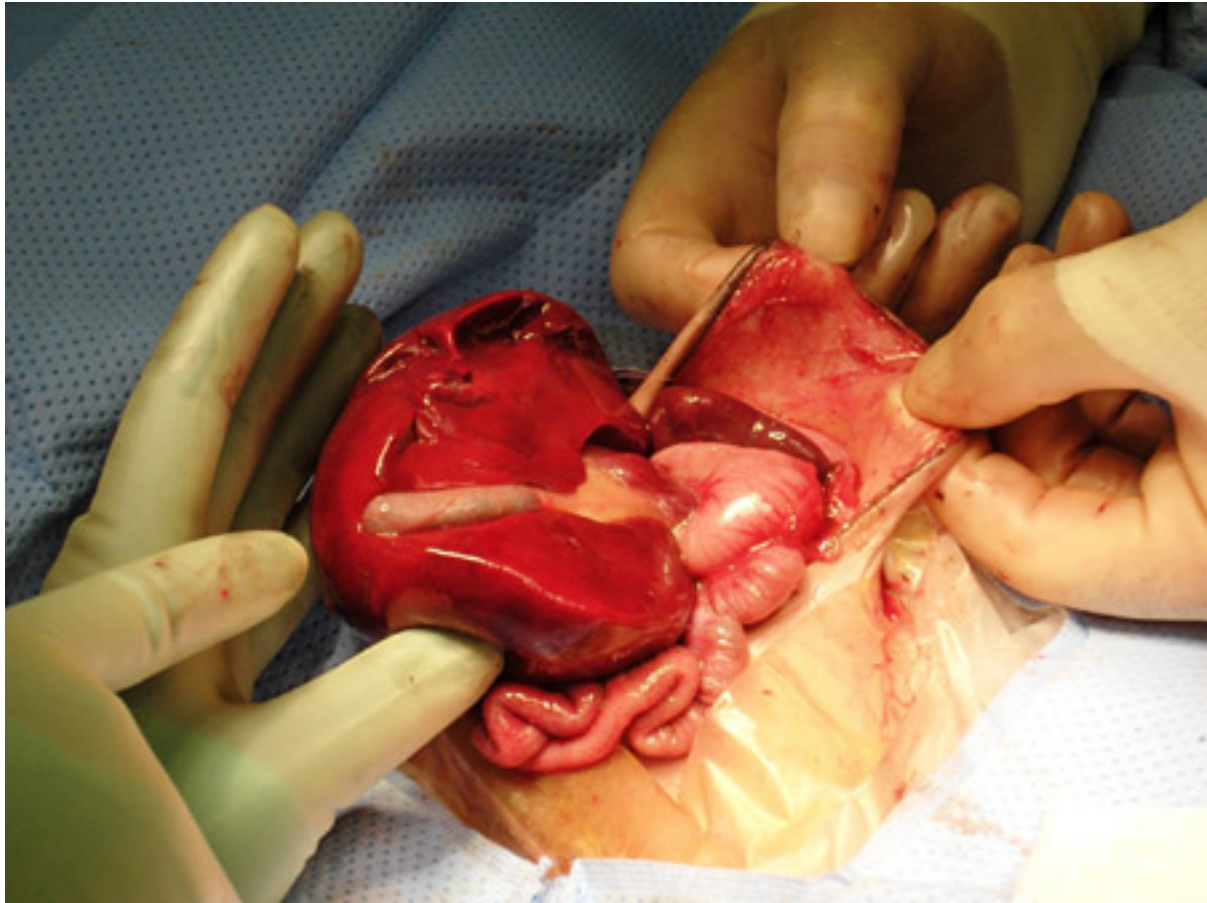


Figure 7: This ruptured omphalocele is similar in appearance to gastroschisis

From collection of J.J. Tepas III, MD, FACS, FAAP

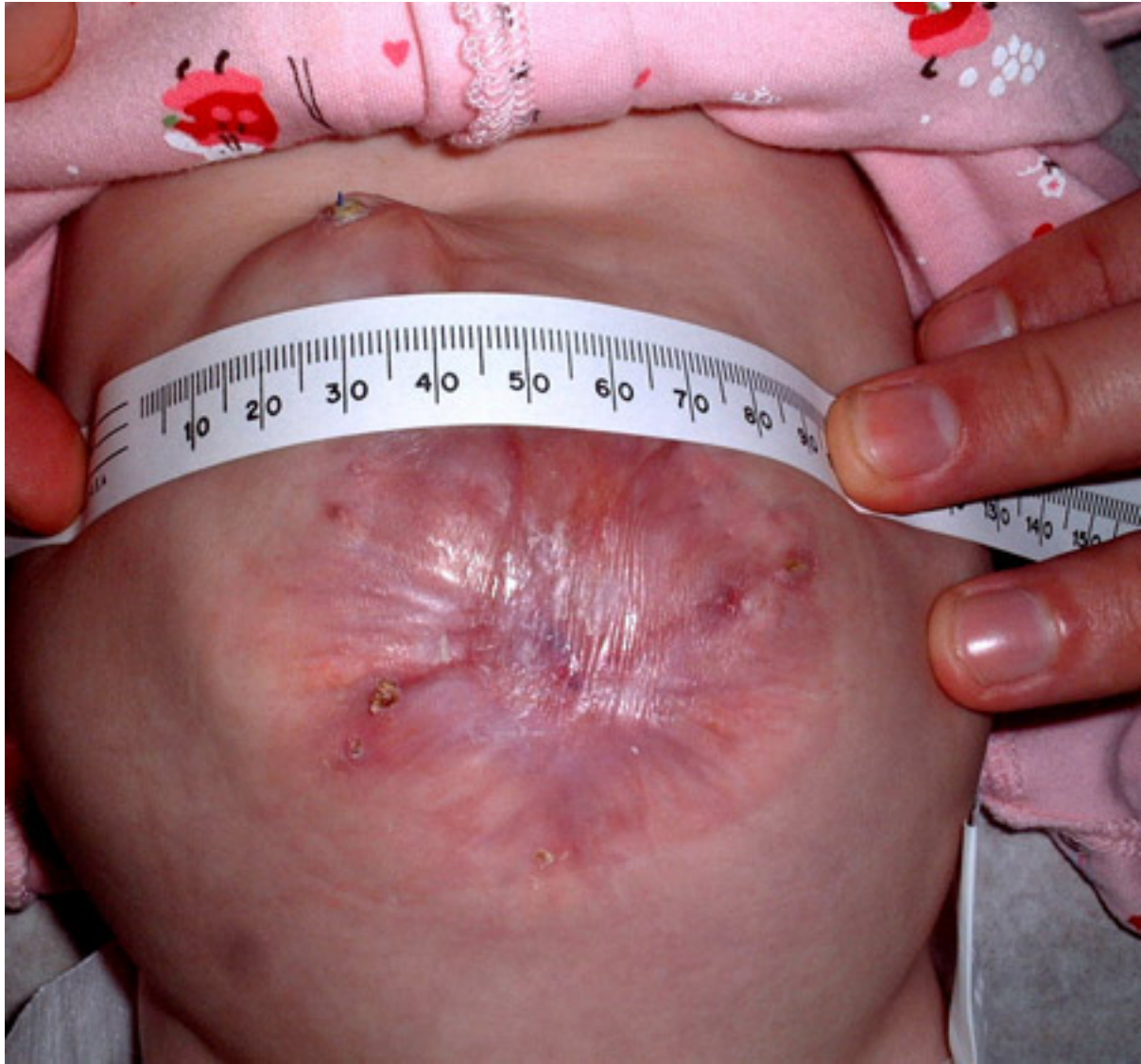

Figure 8: A ventral hernia results from synthetic wall closure of the omphalocele

From collection of J.J. Tepas III, MD, FACS, FAAP

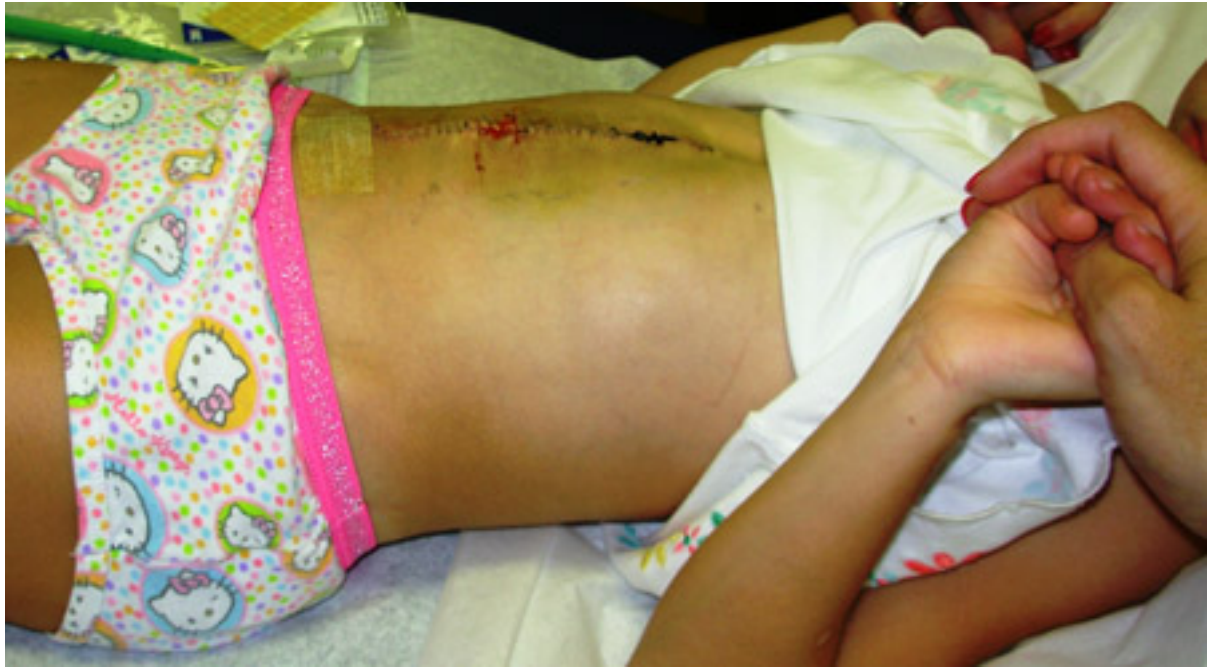

Figure 9: The ventral hernia is repaired in a 6-year-old girl born with omphalocele

From collection of J.J. Tepas III, MD, FACS, FAAP

Disclaimer

BMJ Best Practice is intended for licensed medical professionals. BMJ Publishing Group Ltd (BMJ) does not advocate or endorse the use of any drug or therapy contained within this publication nor does it diagnose patients. As a medical professional you retain full responsibility for the care and treatment of your patients and you should use your own clinical judgement and expertise when using this product.

This content is not intended to cover all possible diagnosis methods, treatments, follow up, drugs and any contraindications or side effects. In addition, since such standards and practices in medicine change as new data become available, you should consult a variety of sources. We strongly recommend that you independently verify specified diagnosis, treatments and follow-up and ensure it is appropriate for your patient within your region. In addition, with respect to prescription medication, you are advised to check the product information sheet accompanying each drug to verify conditions of use and identify any changes in dosage schedule or contraindications, particularly if the drug to be administered is new, infrequently used, or has a narrow therapeutic range. You must always check that drugs referenced are licensed for the specified use and at the specified doses in your region.

Information included in BMJ Best Practice is provided on an “as is” basis without any representations, conditions or warranties that it is accurate and up to date. BMJ and its licensors and licensees assume no responsibility for any aspect of treatment administered to any patients with the aid of this information. To the fullest extent permitted by law, BMJ and its licensors and licensees shall not incur any liability, including without limitation, liability for damages, arising from the content. All conditions, warranties and other terms which might otherwise be implied by the law including, without limitation, the warranties of satisfactory quality, fitness for a particular purpose, use of reasonable care and skill and non-infringement of proprietary rights are excluded.

Where BMJ Best Practice has been translated into a language other than English, BMJ does not warrant the accuracy and reliability of the translations or the content provided by third parties (including but not limited to local regulations, clinical guidelines, terminology, drug names and drug dosages). BMJ is not responsible for any errors and omissions arising from translation and adaptation or otherwise. Where BMJ Best Practice lists drug names, it does so by recommended International Nonproprietary Names (rINNs) only. It is possible that certain drug formularies might refer to the same drugs using different names.

Please note that recommended formulations and doses may differ between drug databases drug names and brands, drug formularies, or locations. A local drug formulary should always be consulted for full prescribing information.

Treatment recommendations in BMJ Best Practice are specific to patient groups. Care is advised when selecting the integrated drug formulary as some treatment recommendations are for adults only, and external links to a paediatric formulary do not necessarily advocate use in children (and vice-versa). Always check that you have selected the correct drug formulary for your patient.

Where your version of BMJ Best Practice does not integrate with a local drug formulary, you should consult a local pharmaceutical database for comprehensive drug information including contraindications, drug interactions, and alternative dosing before prescribing.

Interpretation of numbers

Regardless of the language in which the content is displayed, numerals are displayed according to the original English-language numerical separator standard. For example 4 digit numbers shall not include a comma nor a decimal point; numbers of 5 or more digits shall include commas; and numbers stated to be less than 1 shall be depicted using decimal points. See Figure 1 below for an explanatory table.

BMJ accepts no responsibility for misinterpretation of numbers which comply with this stated numerical separator standard.

This approach is in line with the guidance of the [International Bureau of Weights and Measures Service](#).

Figure 1 – BMJ Best Practice Numeral Style

5-digit numerals: 10,000

4-digit numerals: 1000

numerals < 1: 0.25

Our full website and application terms and conditions can be found here: [Website Terms and Conditions](#).

Contact us

+ 44 (0) 207 111 1105

support@bmj.com

BMJ

BMA House

Tavistock Square

London

WC1H 9JR

UK

Contributors:

// Authors:

Cynthia L. Leaphart, BA, BS, MD

Patient Safety

University of Florida College of Medicine, Jacksonville, FL

DISCLOSURES: CLL declares that she has no competing interests.

// Acknowledgements:

Dr Cynthia L. Leaphart would like to gratefully acknowledge Dr Joseph T. Tepas, a previous contributor to this topic.

DISCLOSURES: JTT declared that he had no competing interests.

// Peer Reviewers:

Lewis Spitz, MBChB, PhD, FRCS, MD, FRCPCH, FAAP, FCS

Emeritus Nuffield Professor of Paediatric Surgery

Institute of Child Health, University College, London, UK

DISCLOSURES: LS declares that he has no competing interests.

Fizan Abdullah, MD, PhD

Assistant Professor of Surgery

Division of Pediatric Surgery, Johns Hopkins University School of Medicine, Baltimore, MD

DISCLOSURES: FA declares that he has no competing interests.

Ruth Hallows, BSc, MB BS, FRCS, FRCS III (Pediatric Surgery)

Consultant in Paediatric and Neonatal Surgery

Royal Alexandra Children's Hospital, Brighton, UK

DISCLOSURES: RH declares that she has no competing interests.

Shilpi Chabra, MD

Assistant Professor

Department of Pediatrics, University of Washington Medical Center, Seattle, WA

DISCLOSURES: SC declares that he has no competing interests.