

# BMJ Best Practice

## Joint dislocation

Straight to the point of care



Last updated: Mar 28, 2024

# Table of Contents

<b>Overview</b>	<b>3</b>
Summary	3
Definition	3
<b>Theory</b>	<b>4</b>
Epidemiology	4
Aetiology	5
Pathophysiology	6
Classification	7
Case history	8
<b>Diagnosis</b>	<b>9</b>
Approach	9
History and exam	24
Risk factors	26
Investigations	28
Differentials	37
<b>Management</b>	<b>42</b>
Approach	42
Treatment algorithm overview	57
Treatment algorithm	58
Primary prevention	66
Patient discussions	67
<b>Follow up</b>	<b>68</b>
Monitoring	68
Complications	69
Prognosis	71
<b>Guidelines</b>	<b>74</b>
Diagnostic guidelines	74
Treatment guidelines	74
<b>Online resources</b>	<b>75</b>
<b>References</b>	<b>76</b>
<b>Images</b>	<b>87</b>
<b>Disclaimer</b>	<b>111</b>

## Summary

Joint dislocation is a complete separation of 2 articulating bony surfaces, often caused by a sudden impact to the joint.

Although any joint may become dislocated, common sites include the shoulder, finger, patella, elbow, and hip.

X-rays are usually taken to confirm a diagnosis and detect any fractures that may have occurred concomitantly at the time of dislocation.

Treatment is usually closed reduction as soon as possible to decrease potential complications, which may include soft tissue injury, articular surface injury, and neurovascular compromise.

## Definition

A joint dislocation is a complete separation of 2 articulating bony surfaces, often caused by a sudden impact to the joint. A partial or incomplete dislocation is called a subluxation. Although any joint may become dislocated, common sites include the shoulder, finger, patella, elbow, and hip.

## Epidemiology

The glenohumeral joint is the most mobile joint in the body, making it particularly vulnerable to dislocation.<sup>[5]</sup> Anterior shoulder dislocations account for more than 95% of shoulder dislocations and are the most common major joint dislocation.<sup>[6]</sup> Posterior shoulder dislocations occur in 2% to 4% of cases, and inferior (i.e., luxatio erecta) dislocations in approximately 5% of cases. The incidence of shoulder dislocations has bi-modal peaks, the first in men between adolescence and 30 years, and the second in women aged 61-80 years.<sup>[7]</sup><sup>[8]</sup>

Studies have estimated the incidence of shoulder dislocation to be 23.9 per 100,000 person-years in the general population, with rates as high as 169 per 100,000 person-years among young, active, and military populations.<sup>[5]</sup>

Between 2012 and 2021, males aged 15-20 years represented the highest proportion of shoulder dislocations presenting to US emergency departments, predominantly resulting from participation in sports. Women experienced a relatively consistent incidence of dislocation throughout their lifespan. Women accounted for less than one third of shoulder dislocations presenting to emergency departments, but after age 63, the incidence rate of dislocations in women surpassed that observed in men. This discrepancy is poorly understood, but may be due to biological differences between men and women as they age, such as muscle bulk and tendon strength, as well as differences in the rate of falls between the sexes.<sup>[5]</sup>

There is a low incidence of shoulder dislocation in the paediatric population, with one study in Italy reporting an incidence of 0.3 per 100,000 inhabitants younger than 14 years; this may be explained by skeletal immaturity, because the mechanisms of injury generally associated with dislocation are more likely to cause proximal humerus fractures or physeal injury in patients whose physis has not yet closed.<sup>[5]</sup><sup>[9]</sup>

Dislocations of the finger joints are common hand injuries with the proximal interphalangeal joint being the most frequently affected site. The incidence rate of finger dislocations presenting to US emergency departments was 11.1 per 100,000 person-years between 2004 and 2008.<sup>[10]</sup> Males were predominantly affected (78.7%) at an incidence rate of 17.8 per 100,000 person-years. Most dislocations occurred in the 15- to 19-year age group (38.6 dislocations per 100,000 person-years) and 35.9% of cases took place at a sporting or recreational facility. Black males were found to be particularly at risk, as were basketball and football players. The rate in females was 4.65 per 100,000 person-years.

Acute patellar dislocation accounts for 2% to 3% of all knee injuries and is the second most common cause of traumatic knee haemarthrosis.<sup>[11]</sup> First-time lateral patellar dislocation has an incidence of approximately 23 per 100,000 person-years.<sup>[12]</sup> Two-thirds of patellar dislocations involve sports-related mechanisms and incidence rates are higher in young, physically active cohorts; in a study of young military personnel in Germany, the incidence of acute traumatic primary dislocation of the patella was estimated to be 77 per 100,000 people per year.<sup>[13]</sup><sup>[14]</sup> In the non-athletic population, women aged 10-17 years are more likely to have patellar dislocations. Women are also more likely to have a prior history of patellar instability and recurrent dislocation.<sup>[15]</sup> In addition, patients with a history of patellar instability and recurrent dislocation are more likely to have contralateral injuries.<sup>[16]</sup>

The elbow joint is the second most commonly dislocated large joint after the shoulder.<sup>[17]</sup> The estimated incidence of elbow dislocations in the US population is 5.21 per 100,000 person-years with 44.5% of dislocations being sustained during sports.<sup>[18]</sup> Adolescent boys are at the highest risk for elbow dislocation (8.91 per 100,000 person-years in boys aged 10-19 years).<sup>[17]</sup> Males tend to sustain this injury while participating in football, wrestling, and basketball, whereas gymnastics and skating activities are more likely

in females.[18] With the rise in popularity of snowboarding, there has been an increase in elbow injuries. Elbow dislocations are significantly more common in snowboarders than skiers; 26% of elbow injuries in snowboarders are dislocations, compared with 5.3% in skiers.[17] Most elbow dislocations (80% to 90%) are posterior or posterolateral.[19]

Hip dislocations are high-energy injuries that are relatively uncommon.[4] They overwhelmingly occur in high-energy motor vehicle accidents. It is estimated that sports-related hip dislocations may account for 2% to 5% of all traumatic hip dislocations.[20] It should be noted that dislocation of a total hip arthroplasty, compared with dislocation of an otherwise normal hip, is usually a low-energy event with the patient flexing and internally rotating the hip.

## Aetiology

Anterior shoulder dislocations in those over 40 years of age are usually the result of a fall or a direct blow to the shoulder, whereas in younger patients they often occur as a result of high-impact activities (e.g., sports and motor vehicle collisions).[6] [7] The injury results from abduction, external rotation, and extension, followed by a posterior-directed force. Posterior dislocations are usually caused by a blow to the anterior shoulder and axial loading of the adducted internally rotated arm. They may also be a result of violent muscle contractions (e.g., seizures, electrocution).[21] Inferior dislocation (luxatio erecta) is caused by hyperabduction or axial loading on an abducted arm.[22]

Distal interphalangeal and proximal interphalangeal finger dislocations are usually dorsal in direction and associated with axial loading, hyperextension, and ball-catching sports.[15] [23] Metacarpophalangeal finger dislocations are relatively rare and are often associated with accompanying fractures.[15] [24]

Primary acute patellar dislocations usually occur in young patients engaged in athletic activities. The patella is typically dislocated laterally and subsequently causes rupture of the medial patellofemoral ligament in about 90% of patients.[25] Patients will often state that when the injury occurred the affected leg was planted while they attempted to pivot. Several anatomical risk factors for first-time and recurrent lateral patellar dislocation have been described, including trochlear dysplasia, patella alta (an abnormally high patella in relation to the femur), increased tibial tuberosity to trochlear groove (TT-TG) distance, patellar tilt, external tibial torsion (i.e., tibia rotates outwards), and a high Q angle (a measurement of the angle between the quadriceps and the patellar tendon).[26] [27] [28] [29] [30] Trochlear dysplasia appears to be the most significant contributor to instability of the patellofemoral joint.[16] [31] [32]

Elbow dislocations usually occur in young patients, and nearly 50% are sports-related.[18] They are most commonly the result of a fall on an outstretched arm, resulting in an externally rotated, valgus, and axially directed load to the elbow.[33] [34] Direct high-energy impact can also be a cause.[35]

Acquired hip dislocations are either native dislocations or dislocations after total hip replacement. Axial loading of the femur towards the acetabulum is the classically described mechanism for native hip dislocation. It is commonly observed with impact of the bent knee with a dashboard in a motor vehicle crash.[36] The direction of the dislocation is dependent on the position of the femur and the acetabulum at impact, and the direction of the force vector applied.[37] An adducted femur that is flexed at the hip will sustain a posterior hip dislocation. A hip that is abducted and externally rotated is more likely to sustain an anterior dislocation.

Dislocation after total hip replacement usually occurs within the first 3 months following surgery. It occurs when the patient reaches the extremes of the prosthetic range of motion and the femoral neck levers on the



acetabular cup, allowing the femoral head to leave the acetabulum. Other common conditions that can lead to postoperative dislocations include laxity or soft tissue incompetence surrounding the hip joint, incorrect positioning of prosthetic components, and neuromuscular disorders (e.g., Parkinson's disease).<sup>[38]</sup>

Those with loose ligaments may experience sprains or dislocations more frequently. Loose ligaments may be generalised or confined to a few joints; the trait is usually hereditary. Affected patients have joints with a wide range of movement (e.g., 'double-jointed' people). Ehlers-Danlos syndrome is a rare inherited condition characterised by unusually flexible joints, very elastic skin, and fragile tissues. It may be the cause of widespread laxity of connective tissue.

## Pathophysiology

### Shoulder dislocations

- Often caused by trauma; 25% are associated with concurrent humeral fractures.<sup>[39]</sup>
- Hill-Sachs and Bankart's lesions are possible sequelae of the dislocation if the humerus dislocates anteriorly.<sup>[40]</sup>
- Rotator cuff tears are often found after dislocations, particularly in older adults.<sup>[41]</sup> The overall frequency of rotator cuff tears after an anterior dislocation ranges between 7% and 32% and rises with advancing age.<sup>[42]</sup> Some studies have shown up to 100% incidence of cuff tears in patients over 70 years of age.<sup>[43]</sup>

### Finger dislocations

- Dorsal distal interphalangeal (DIP) dislocations occur following failure of the volar plate (i.e., the restraint to dorsal displacement of the digit) with dislocation of the distal phalanx. Occasionally, the volar plate can become entrapped in the joint, making the DIP irreducible. Volar dislocations may become irreducible as the extensor tendon or sesamoid bones become wrapped around the head of the middle phalanx.<sup>[15] [44] [45]</sup>
- Dorsal proximal interphalangeal (PIP) dislocations involve axial stress and hyperextension and result in disruption of the volar plate. Occasionally, the volar plate can become entrapped in the joint, making the PIP irreducible. On rare occasions these dislocations can be in a volar direction. This dislocation is often irreducible because of interposition of the dorsal plate, the central slip, or the lateral bands of the finger.<sup>[15] [41] [46]</sup>
- Dorsal metacarpophalangeal dislocations are uncommon because of the ligamentous stability afforded at the base of the fingers. Dislocations at this level imply disruption of the volar plate, collateral ligaments, and the joint capsule.<sup>[15] [24]</sup>

### Patellar dislocations

- The primary restraint to lateral translation of the patella is the medial patellofemoral ligament (MPFL). The incidence of tears to the MPFL during an acute patellar dislocation varies from 75% to 98%. As this structure fails, the main stabiliser is disrupted, which allows the patella to translate laterally.<sup>[13] [31] [32]</sup>

### Elbow dislocations

- The most common direction of elbow dislocation is posterior or posterolateral; however, the exact mechanism has been the subject of debate.<sup>[47]</sup>
- O'Driscoll et al proposed a sequential 3-stage disruption of soft tissue structures from lateral to medial, termed the 'Horii circle':<sup>[48]</sup>

- the lateral collateral ligament is injured (stage 1)
- the remaining lateral structures and the anterior/posterior capsular attachments become involved (stage 2)
- the anterior band of the medial collateral ligament is disrupted (stage 3).
- Other studies have proposed that the soft tissue injury sustained during elbow injury begins, and is more severe, on the medial side.[\[34\]](#) [\[47\]](#) [\[49\]](#) [\[50\]](#) [\[51\]](#)
- Common to all proposed mechanisms is an extended elbow with the forearm in supination, subjected to an axial load and a posterolateral, or valgus, force, and resulting in a spectrum of soft tissue injuries.[\[47\]](#) Throughout this continuum of injury, there is a potential for associated fractures to the intracapsular structures including the radial head and coronoid process.[\[44\]](#)

#### Hip dislocations

- Dislocation of the hip is an uncommon event, as the hip is a confined ball and socket joint that is considered to be extremely stable.[\[52\]](#)
- Significant force applied through the femoral head can lead to a dislocation of the joint combined with a fracture to the posterior acetabular wall, the acetabulum in general, the femoral head, and rarely the femoral neck.[\[52\]](#) [\[53\]](#)
- Cartilage damage is also commonly documented as a result of a shearing injury across the cartilage of the acetabulum and the femoral head. Resulting loose bodies from fragmented bone and cartilage can be left behind, in and around the hip joint.[\[4\]](#)

## Classification

### Clinical definitions

#### Shoulder dislocations:

- Types are based on direction of dislocation: anterior, posterior, or inferior (i.e., luxatio erecta)
- Can also be characterised as primary (i.e., first dislocation) or recurrent.[\[1\]](#)

#### Finger dislocations:

- Characterised by the joint involved: metacarpophalangeal (MCP), proximal interphalangeal (PIP), or distal interphalangeal (DIP)
- Also described by the direction of displacement (i.e., dorsal or volar in respect of position of distal part).

#### Patellar dislocations:

- Characterised by direction of dislocation, the majority being lateral
- Can also be described as primary (i.e., first dislocation) or recurrent.

#### Elbow dislocations:

- Characterised as simple or complex
- Simple elbow dislocation is defined as acute dislocation that occurs without fracture[\[2\]](#)
- Complex dislocations involve concomitant fractures of the proximal radius, ulna, or distal humerus. They can also be classified based on the direction of displacement of the radius and ulna with respect to the humerus (i.e., anterior or posterior). A posterior dislocation of the elbow associated with a fracture of the coronoid process and fracture of the radial head is described as the 'terrible triad'.[\[3\]](#)

#### Hip dislocations:

- Characterised by direction of dislocation (i.e., anterior or posterior) and severity as per the Stewart-Milford classification system:[4]
  - Type I: simple dislocation without fracture
  - Type II: dislocation with one or more rim fragments, but with sufficient socket to ensure stability after reduction
  - Type III: dislocation with fracture of the rim producing gross instability
  - Type IV: dislocation with fracture of the head or neck of the femur.

## Case history

### Case history #1

A 24-year-old man presents to the emergency department after a fall onto his shoulder while playing football. He is an otherwise healthy man who has had no prior shoulder problems. The patient is unable to actively abduct or flex his arm secondary to pain. He is maintaining his arm in a position of slight external rotation and abduction. There is a palpable prominence inferior to his coracoid process. Sensation in his axillary nerve distribution is intact with a normal neurovascular examination.

### Case history #2

A 35-year-old man presents to the emergency department having jammed his index finger at work 6 hours prior to presentation. There is significant swelling at his proximal interphalangeal joint with apparent dorsal displacement of his middle phalanx in relation to the proximal phalanx. He is unable to flex or extend his finger secondary to pain. Sensation on the radial and ulnar border of the digit is intact with capillary refill normal at less than 2 seconds.



## Approach

Symptoms and signs of joint dislocation include pain, swelling, characteristic posturing, and the inability to move.

Diagnosis is usually confirmed with plain x-rays.

### History

Any patient presenting after a traumatic injury complaining of shoulder, finger, knee, elbow, or hip pain, accompanied by painful or incomplete range of motion or characteristic posturing, needs prompt work-up with appropriate imaging.

### Physical examination

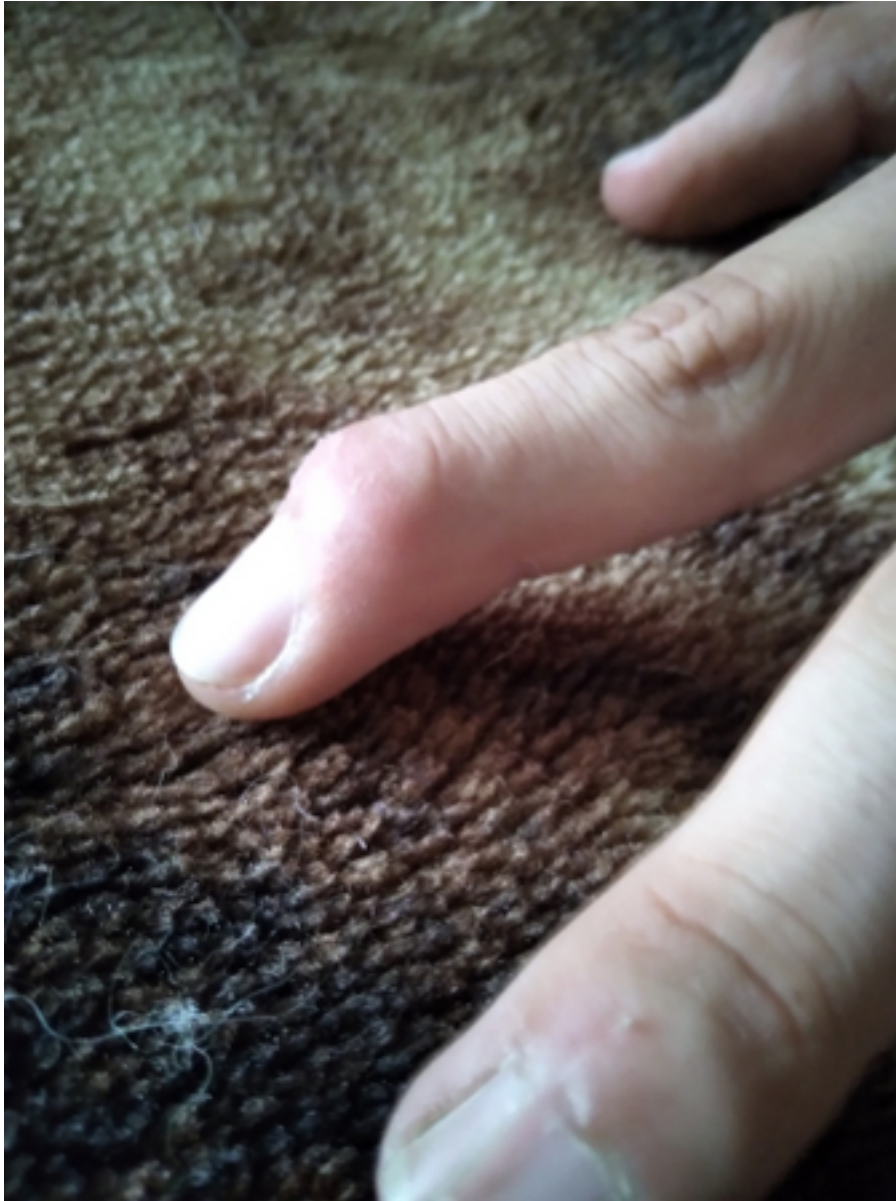#### Shoulder dislocation

- Patients commonly present with an arm in a characteristic position of external rotation and slight abduction. They usually have significant pain when attempting motion and are apprehensive about moving the affected joint.
- Fullness anteroinferior to the coracoid process is palpable.[54]
- A thorough neurological examination is essential to document function of the radial, ulnar, axillary, and median nerves prior to any reduction, and the patency of the axillary artery must be confirmed by the presence of symmetrical radial pulses.[54]
- Radial nerve function is assessed by having the patient demonstrate thumb, finger, and wrist extension, along with intact sensation over the dorsum of the hand.
- Ulnar nerve function is assessed by having the patient demonstrate active finger abduction and intact sensation over the medial border of the hand including the small finger and ulnar border of the ring finger.
- Median nerve function is assessed by having the patient demonstrate finger flexion, the OK sign, and intact sensation over the palm and thenar eminence.
- Axillary nerve motor function is difficult to assess secondary to pain and swelling, but intact sensation over the deltoid indicates some function of the nerve.
- While most common shoulder dislocations are anterior (>95%), posterior dislocations do occur (2% to 4%), often following electrocution or seizure, and present with the arm held in adduction and internal rotation; they will also be unable to externally rotate the affected extremity actively or passively.[21] [54]
- Inferior dislocations (i.e., luxatio erectae) occur in 0.5% of cases, and present with a palpable mass in the axilla and the arm fully abducted over the head, with the inability to adduct the arm.[22] They often occur following accidents involving a high-energy impact such as a motorcycle collision. Inferior dislocations are associated with a high rate of complications such as tendon and ligament injuries, vascular compromise, and neurological damage.

#### Finger dislocation

- Patients often present with varying degrees of oedema and ecchymosis (bruising), and are apprehensive about moving the affected joint.
- Care must be taken to document the neurovascular status of the affected finger by confirming the presence of sensation on the radial and ulnar borders of the digit.

- Any abrasions or lacerations to the joint should alert the physician to the possibility of an open wound, necessitating consideration of antibiotic coverage and orthopaedic consultation.
- Distal finger dislocations are often considered to be sprains and are often missed.[15]
- Most dislocations of the proximal interphalangeal, distal interphalangeal, and metacarpophalangeal joints are dorsal; some may be volar (i.e., towards the palm). Volar injuries are often unstable and can be easily missed.[15] [55]

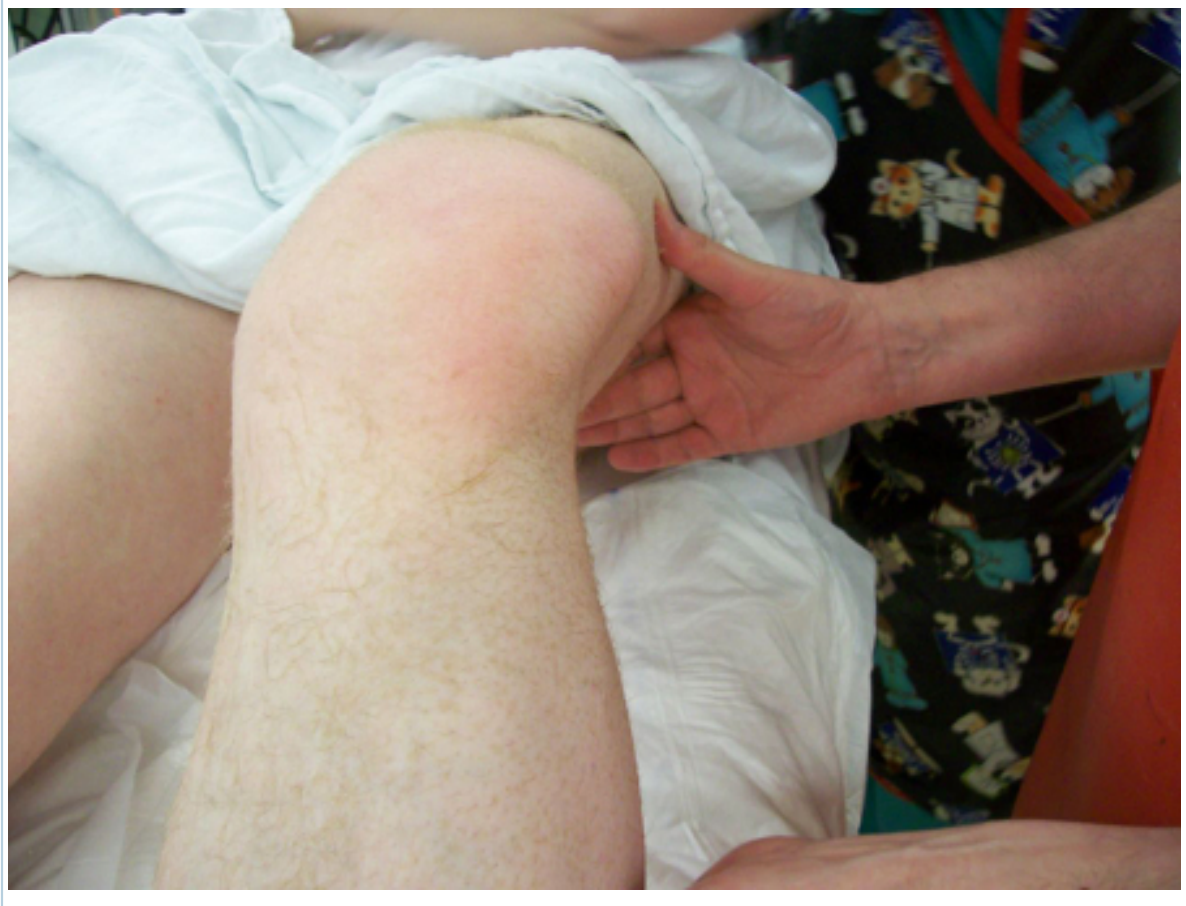

*Dislocated distal phalanx, index finger, left hand*

*Bobjgalindo, CC BY-SA 4.0, via Wikimedia Commons*

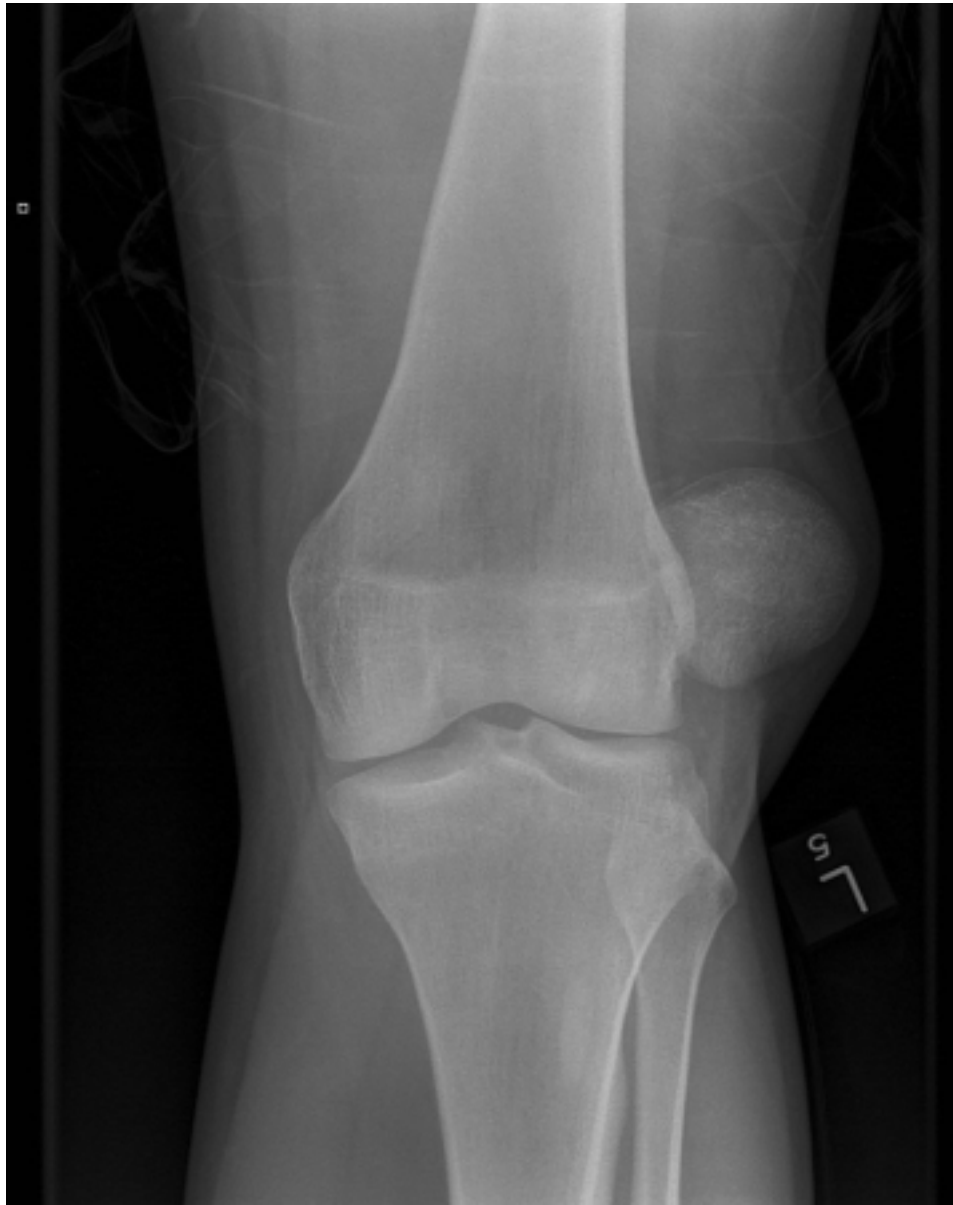#### Patellar dislocation

- Patients often present with a swollen knee held in flexion and an obvious lateral prominence. However, it is not uncommon for patellar dislocations to reduce spontaneously during transport, leg extension, or examination.



*Patellar dislocation: knee held in partial flexion with a visible mass lateral to the lateral femoral condyle*

*Yerimah G et al. BMJ Case Rep. 2013 May 2;2013:bcr2013009832; used with permission*



*Left knee radiograph demonstrating lateral patella dislocation*

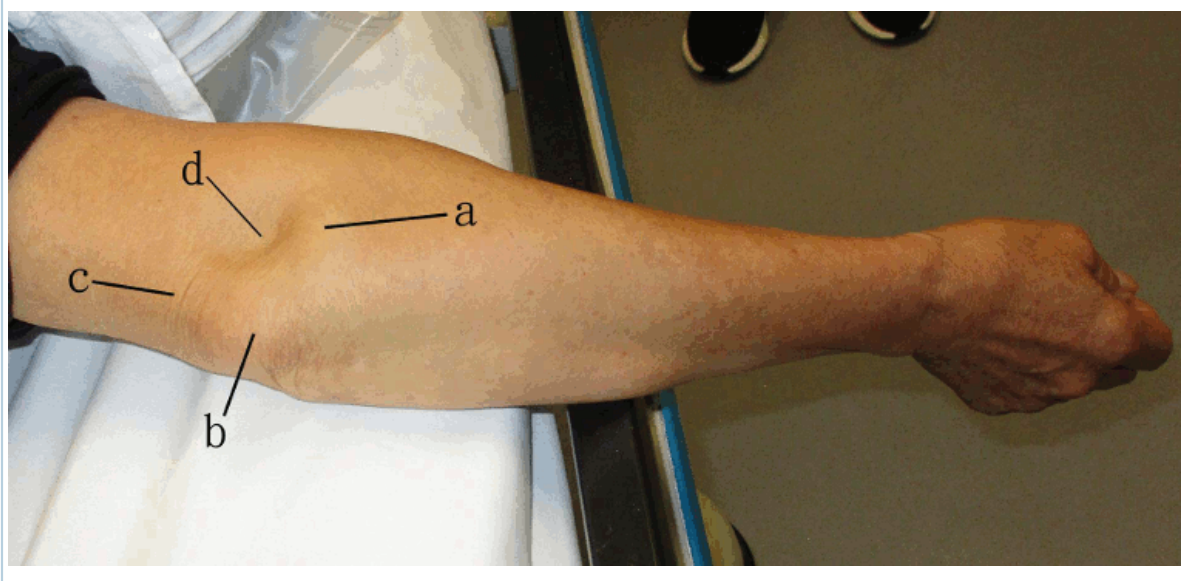
*Yerimah G, et al. BMJ Case Rep. 2013 May 2;2013:bcr2013009832; used with permission*

- Patellar dislocation is often associated with haemarthrosis (bleeding into joint spaces) and a positive apprehension test. In this test, the patient lies supine on a table with the knee flexed to between 20° and 30° and the quadriceps relaxed. The examiner carefully glides the patella laterally, observing for the apprehension sign (i.e., anxiety and resistance), which denotes a positive test.
- Tenderness to palpation over the medial patellar retinaculum indicates a tear of the medial patellofemoral ligament. If pain permits, the physician should also perform a full knee examination to determine concomitant injury to the other ligamentous structures. This may include the anterior/posterior drawer and Lachman's tests to examine the cruciate ligaments, the McMurray's test to evaluate for meniscal tears, and varus and valgus stress testing to evaluate the function of various knee ligaments.
- The patient should demonstrate the ability to perform a supine straight leg raise to exclude patellar or quadriceps tendon rupture.[16] [32] [56] [57]



## Elbow dislocation

- Patients typically present with the elbow held in flexion and have significant pain following any attempt at active or passive movement.
- The olecranon is prominent, and there is often a significant amount of soft tissue swelling around the elbow.



*Right elbow dislocation: dislocated radial head (a), olecranon (b), and tensed triceps tendon (c) resulting in a skin depression (d) just proximal to the radial head*

*Lui TH, et al. BMJ. 2020 Oct 8;371:m3494; used with permission*

- A thorough neurological examination is imperative to document function of the radial, ulnar, and median nerves prior to any reduction. The patency of the brachial artery must be confirmed by the presence of symmetrical radial pulses.
- Radial nerve function is assessed by having the patient demonstrate thumb, finger, and wrist extension, along with intact sensation over the dorsum of the hand.
- Ulnar nerve function is assessed by having the patient demonstrate active finger abduction and intact sensation over the medial border of the hand including the small finger and ulnar border of the ring finger.
- Median nerve function is assessed by having the patient demonstrate finger flexion, the OK sign, and intact sensation over the palm and thenar eminence.
- Axillary nerve motor function is difficult to assess secondary to pain and swelling, but intact sensation over the deltoid indicates some function of the nerve.
- Most elbow dislocations are posterior or posterolateral (80% to 90%), but some can be anterior. In these circumstances the arm is held in extension and will appear shortened relative to the contralateral extremity. A posterior dislocation of the elbow associated with a fracture of the ulnar coronoid process and fracture of the radial head is described as the 'terrible triad'.
- Intra-articular dislocations are rare, but when they occur usually require general anaesthesia for closed or open reduction.<sup>[58]</sup>

## Hip dislocation

- Hip dislocation is an uncommon event.
- The classic appearance of posterior hip dislocation is with the hip in a position of flexion, internal rotation, and adduction.

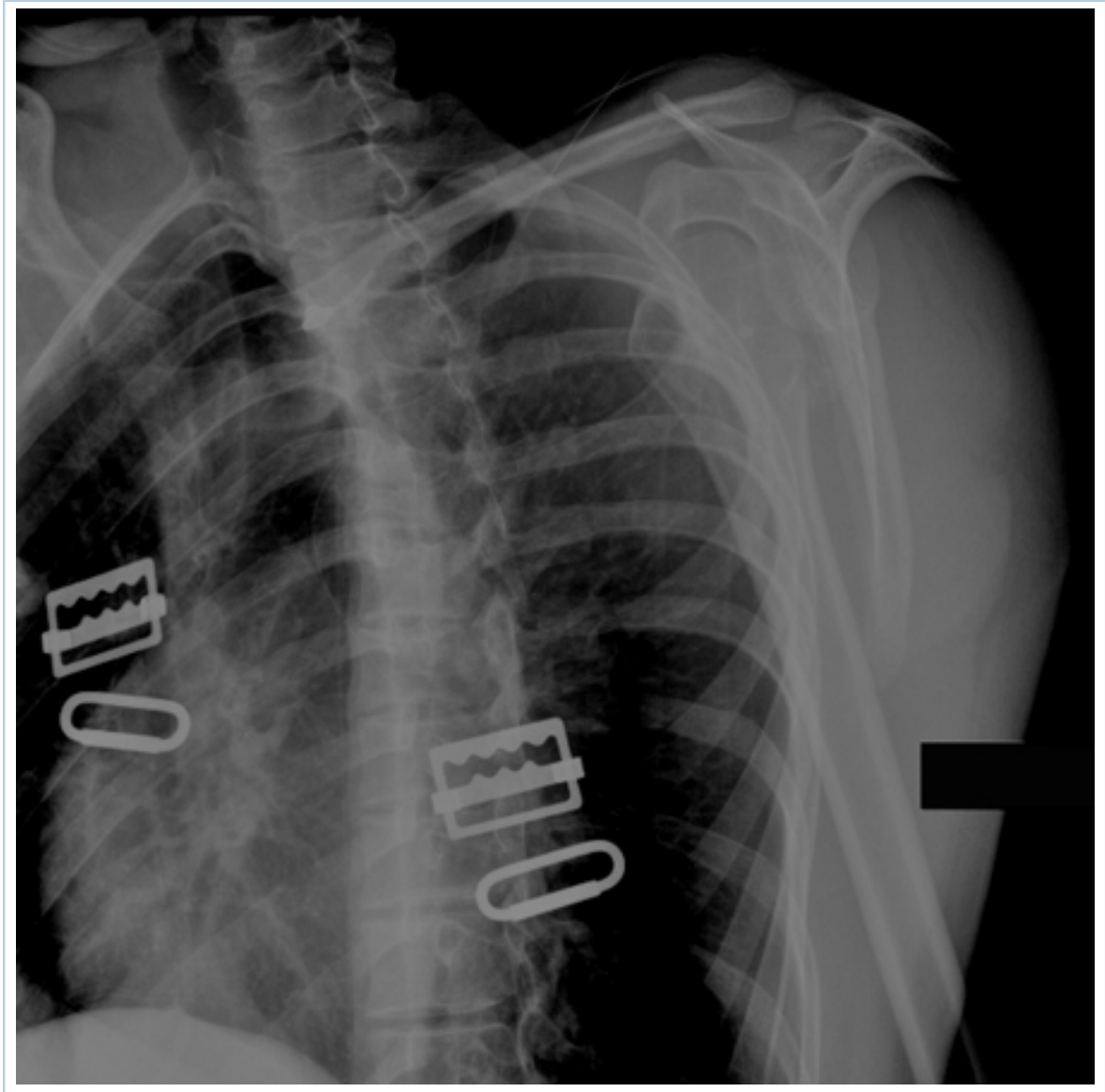
- Sciatic nerve injury may occur with stretching of the nerve over the posteriorly dislocated femoral head. Fragments of bone from a posterior wall fracture can also cause injury to the nerve.
- Anterior hip dislocation classically presents with the hip held in external rotation, with mild flexion and abduction.
- Anterior hip dislocation can cause injury to the femoral artery, vein, or nerve.
- Concomitant injuries are quite common with hip dislocations, and they therefore require thorough evaluation. Ipsilateral knee, patella, and femur fractures are common. Pelvic fractures and spine injuries may also be seen.[4]

## Imaging

### Shoulder dislocation

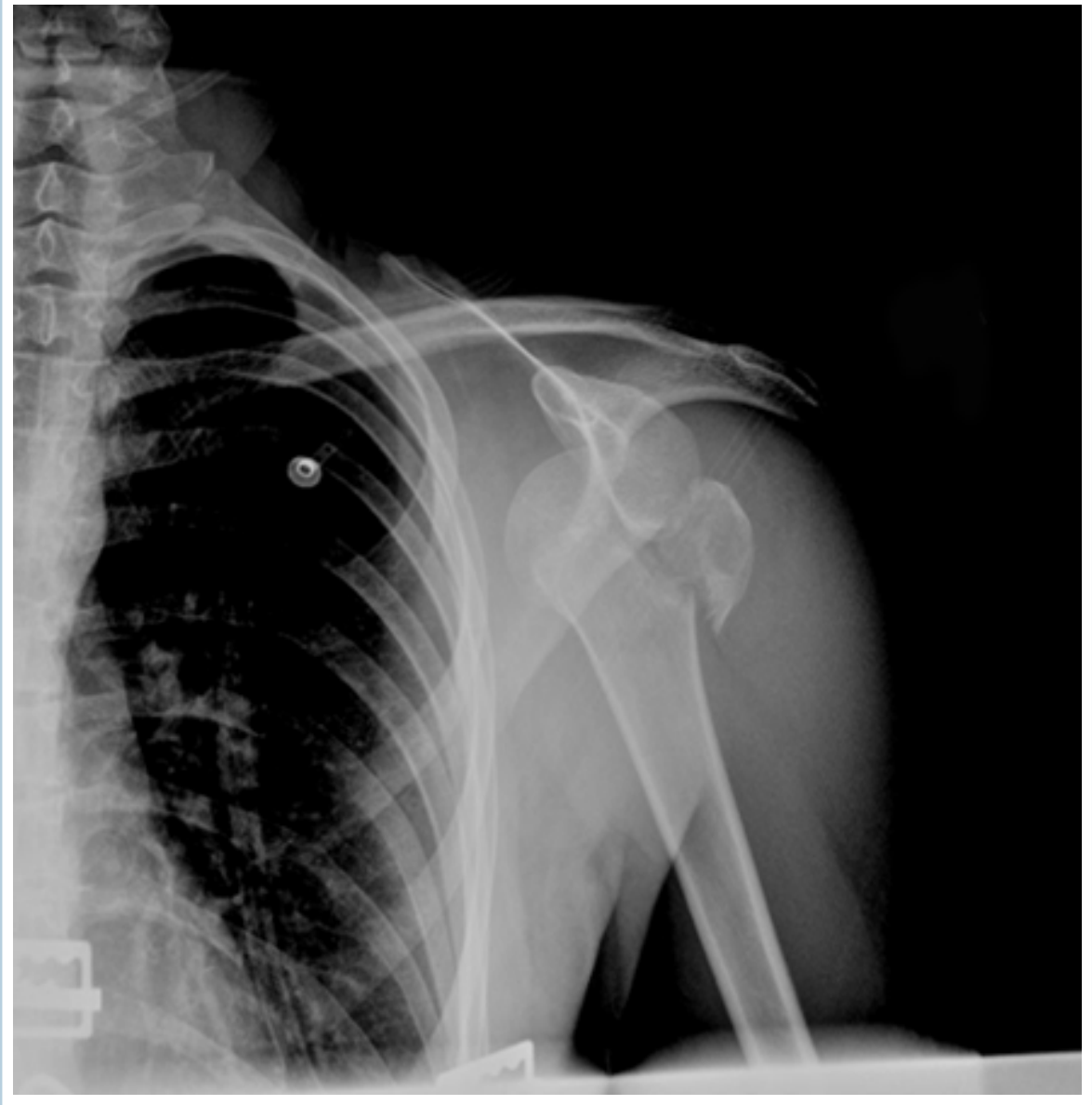- The diagnosis can be made on x-rays alone.
- An anteroposterior (AP) x-ray view of the shoulder should be taken with internal and external humeral rotation.[59] These should be accompanied by axillary lateral and/or scapular Y views to confirm diagnosis. Each of these x-ray views is 92% sensitive for acute shoulder dislocation.[60] On a scapular Y view, the humeral head lies anteriorly to the Y in anterior dislocations, and posteriorly to the Y in posterior dislocations. In standard AP views, the humeral head rests anteroinferiorly to the coracoid in anterior dislocations. However, in posterior dislocations, the humerus can appear to be reduced. Therefore, axillary or scapular Y views are essential for accurate diagnosis, as up to 79% of posterior shoulder dislocations are initially misdiagnosed. Axillary views can correctly identify posterior dislocations in 100% of patients when combined with AP views of the shoulder.[61] [62] An axillary lateral or a modified axillary view known as the Velpeau view may also be used to confirm diagnosis.
- A possible fracture of the proximal humerus should be excluded, as attempts at reduction could further displace this fracture.
- If a vascular injury is of concern based on the physical examination, an arteriogram may be required.
- MRI scans provide excellent visualisation of soft tissue anatomy and may be ordered if any associated injuries (e.g., rotator cuff tears) are suspected.
- Point-of-care ultrasound (POCUS) has been suggested as an additional diagnostic tool for shoulder dislocation. It has the potential to reduce time to diagnosis and reduction, as well as radiation exposure and healthcare costs. One systematic review found that POCUS had 100% sensitivity and specificity for the identification of shoulder dislocations and reductions, and 96.8% sensitivity and 99.7% specificity for the detection of associated fractures.[63] However, it is not yet clear exactly when ultrasound is optimal - pre- or post-reduction - and which x-rays it should replace.





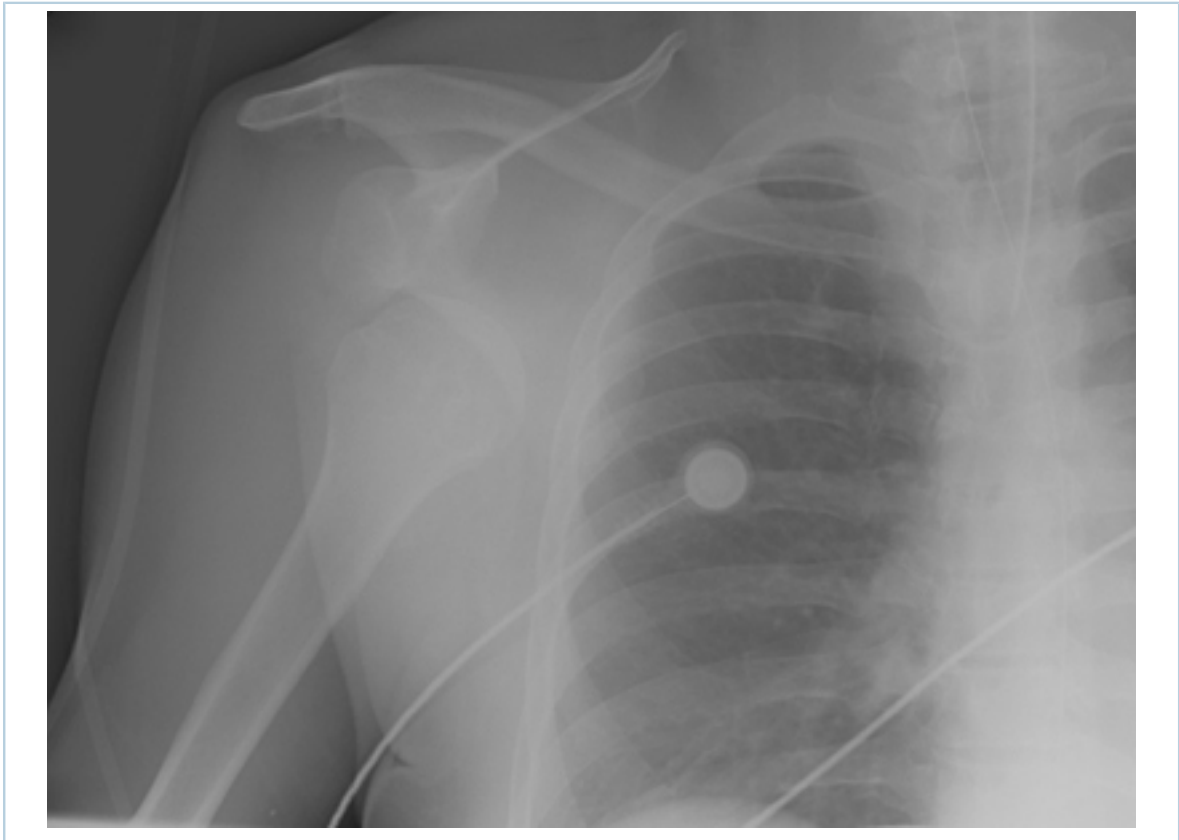
*Scapular Y x-ray view showing an anterior dislocation of the shoulder*

*Personal collection of Dr Paul Novakovich*



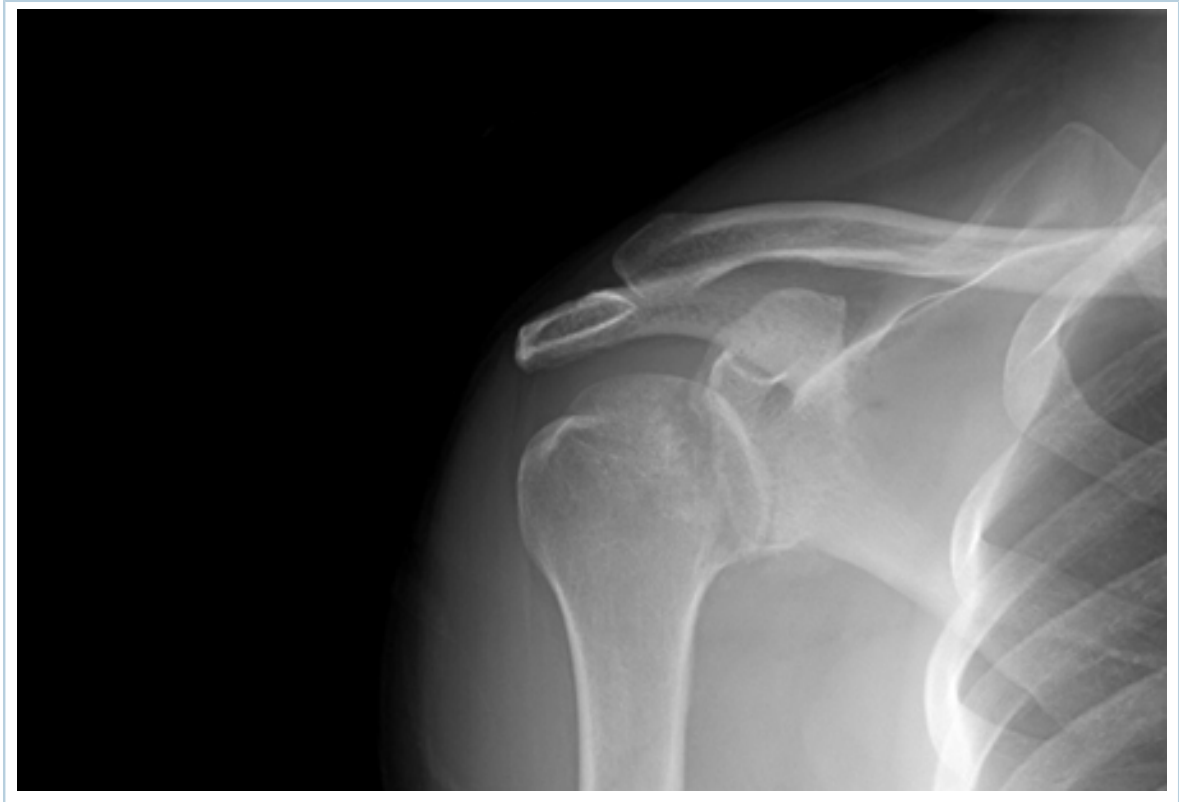*Scapular Y x-ray view showing an anterior fracture dislocation  
of the shoulder and fracture of the greater tuberosity*

*Personal collection of Dr Paul Novakovich*



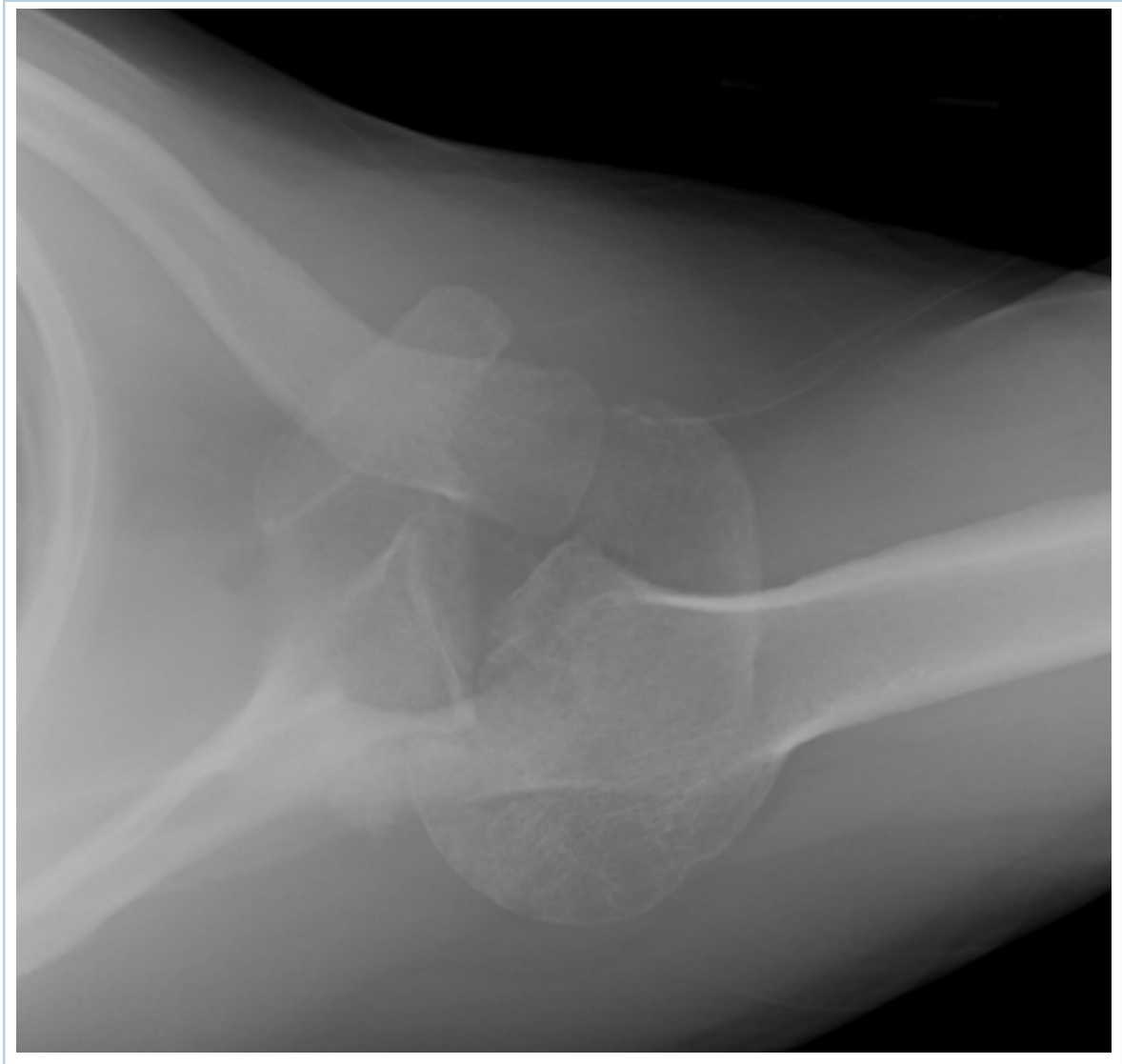
*Anteroposterior x-ray view of a shoulder showing an anteroinferior dislocation*

*Personal collection of Dr Paul Novakovich*



*Anteroposterior x-ray view of a shoulder showing a missed posterior dislocation: the glenohumeral joint appears reduced*

*Personal collection of Dr Paul Novakovich*

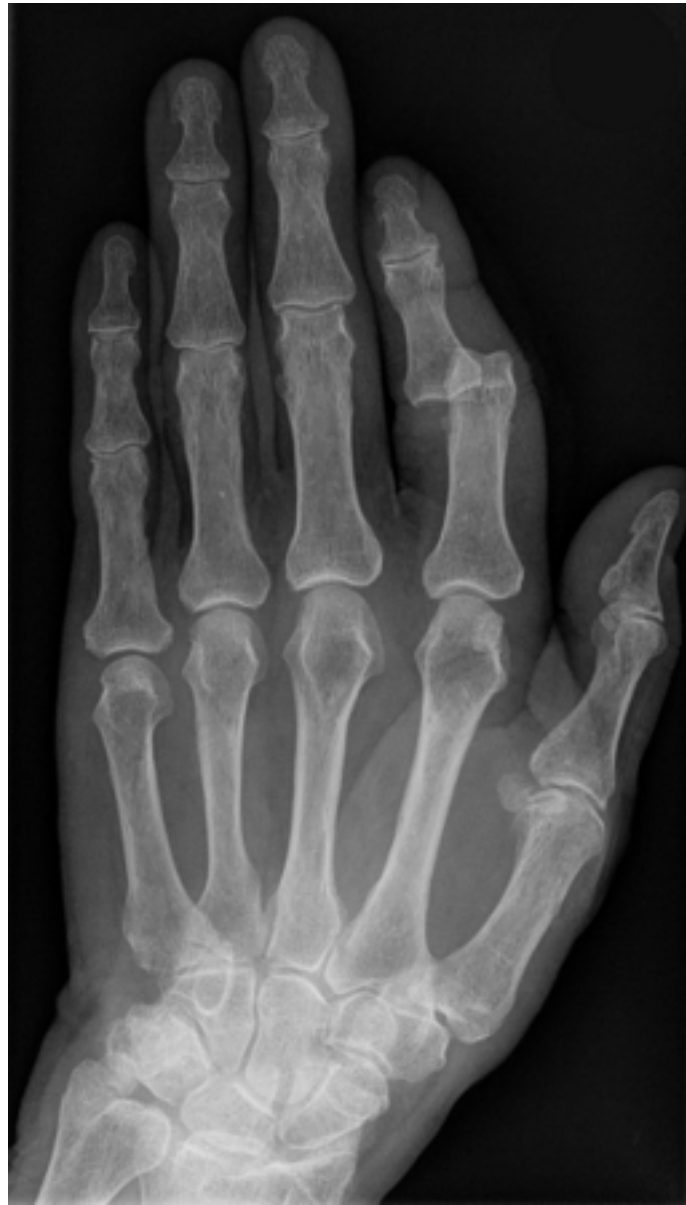

*Axillary lateral of a shoulder with a missed posterior dislocation: humeral head clearly is not reduced and is locked on the posterior rim of the glenoid*

*Personal collection of Dr Paul Novakovich*

#### Finger dislocation

- Clinical suspicion is based on the history and physical examination and may warrant plain film imaging of the hand or individual finger.
- AP, oblique, and lateral views of the affected joint are mandatory in evaluating a patient with a hand injury to exclude fracture and/or dislocation.
- These x-rays should be closely inspected for associated fractures and avulsions, which may indicate ligament or tendon damage.
- Further imaging is usually not necessary in the acute management of simple dislocations.



*X-ray showing dislocation of the proximal interphalangeal joint, left index finger*

*Hellerhoff, CC BY-SA 3.0 via Wikimedia Commons*

#### Patellar dislocation

- Clinical suspicion is based on the history, and physical examination warrants AP and lateral x-ray views of the knee. However, it is not uncommon for patellar dislocations to reduce spontaneously during examination or following leg extension.
- Dislocation can be confirmed on a Merchant or sunrise (infra-patellar) view, which should demonstrate the medial facet of the patella resting on the lateral trochlea of the femur.
- Images should be inspected closely for evidence of osteochondral lesions.
- CT scans are not necessary unless adequate x-rays cannot be obtained or are inconclusive.
- MRI scans of the knee joint can be useful in determining associated ligament injuries or osteochondral lesions but are not necessary to confirm an acute patellar dislocation.<sup>[57]</sup>





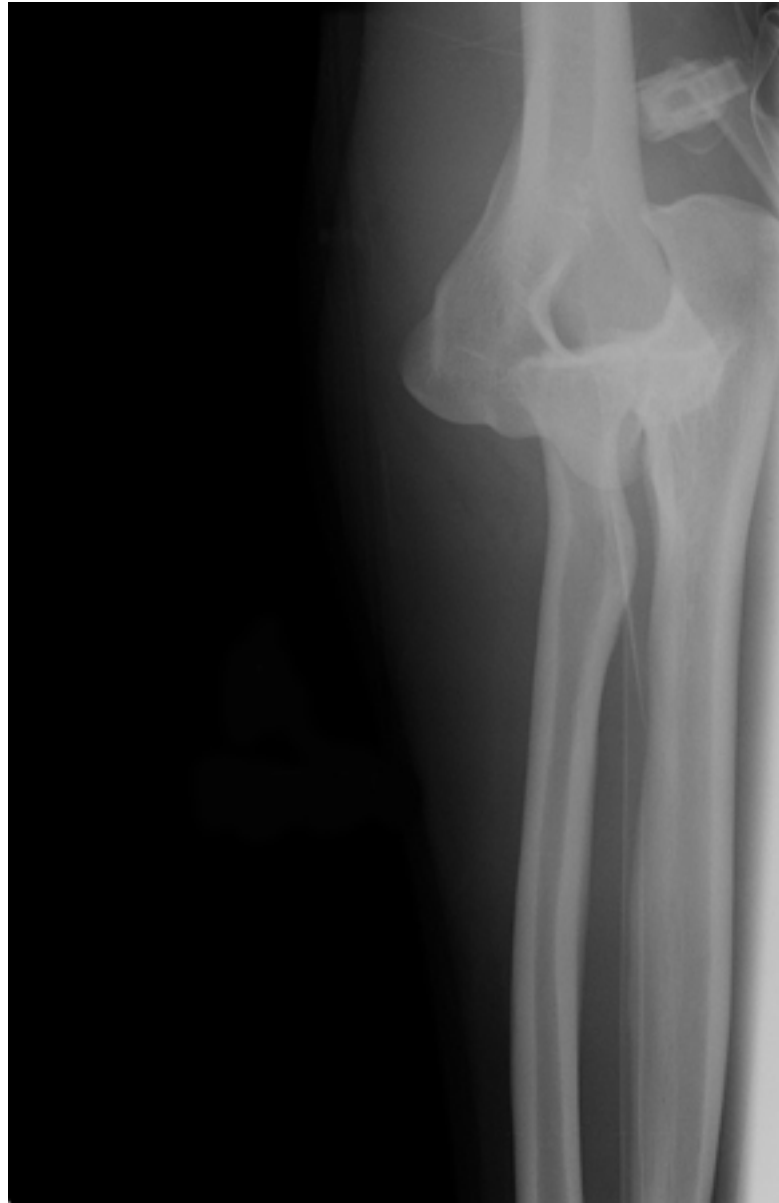*Left knee radiograph demonstrating lateral patella dislocation*

*Yerimah G, et al. BMJ Case Rep. 2013 May 2;2013:bcr2013009832; used with permission*

#### Elbow dislocation

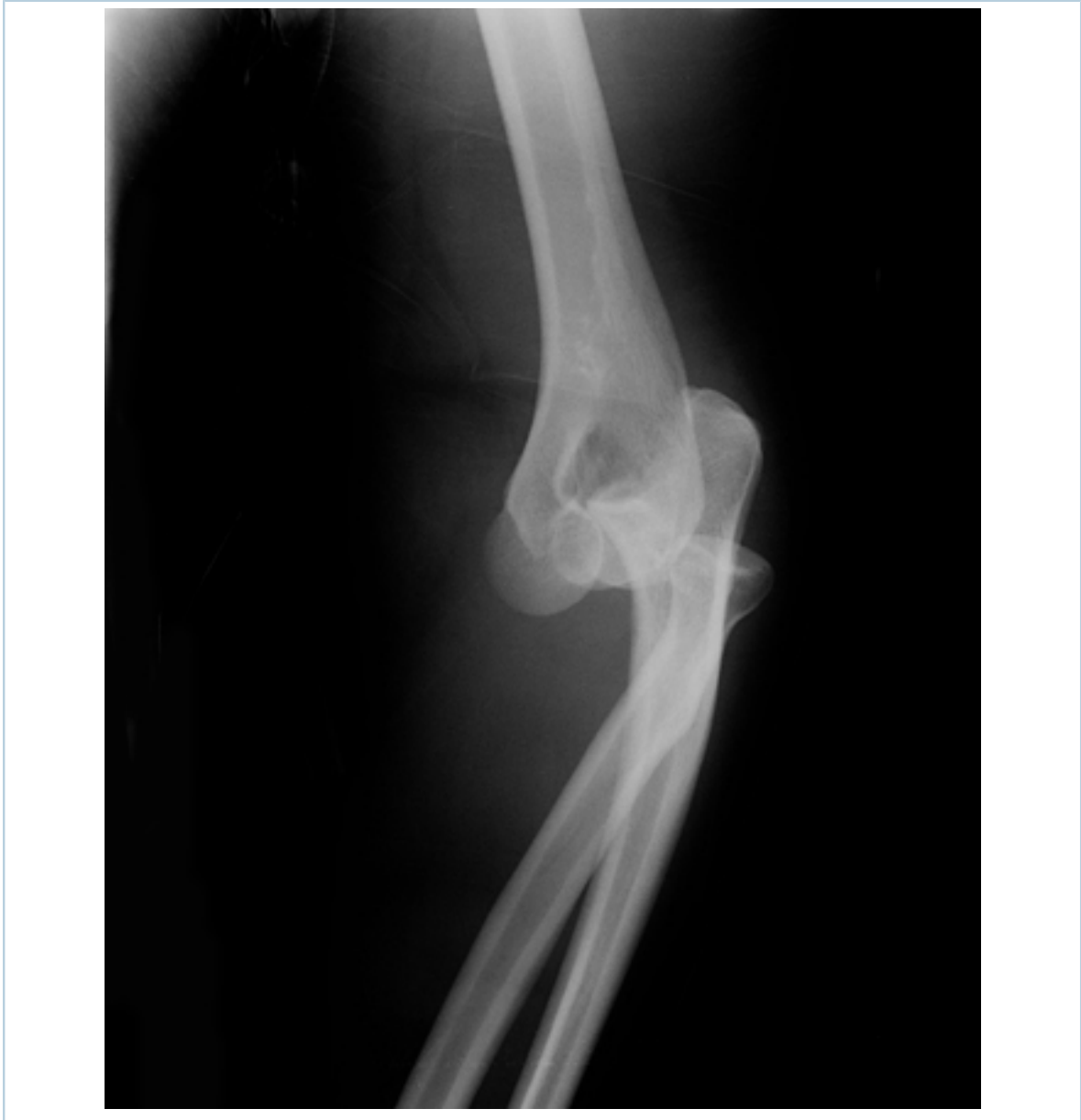- Clinical suspicion is based on the history; physical examination should prompt radiographic imaging of the elbow.
- Most elbow dislocations are posterior or posterolateral (80% to 90%). Standard AP and lateral x-ray views of the elbow joint are the initial radiographic study of choice. In a posterior dislocation, these show the radius and ulna lying posterior to the distal humerus.
- The radial head should always be in line with the capitellum, and the olecranon should rest in the trochlea on a standard lateral view.
- In addition, AP and lateral x-ray views of the forearm are necessary to exclude associated forearm fractures (e.g., Monteggia fracture).
- A radial head/capitellum view may be used to discern radial head and coronoid fractures. Radial head fractures and coronoid fractures can be difficult to discern on plain x-rays but are readily apparent on a non-contrast CT scan of the elbow.[44]

- Further imaging to exclude other extremity injuries may be required and should be based on a thorough physical examination.



*Anteroposterior x-ray view of an elbow dislocation*

*Personal collection of Dr Paul Novakovich*

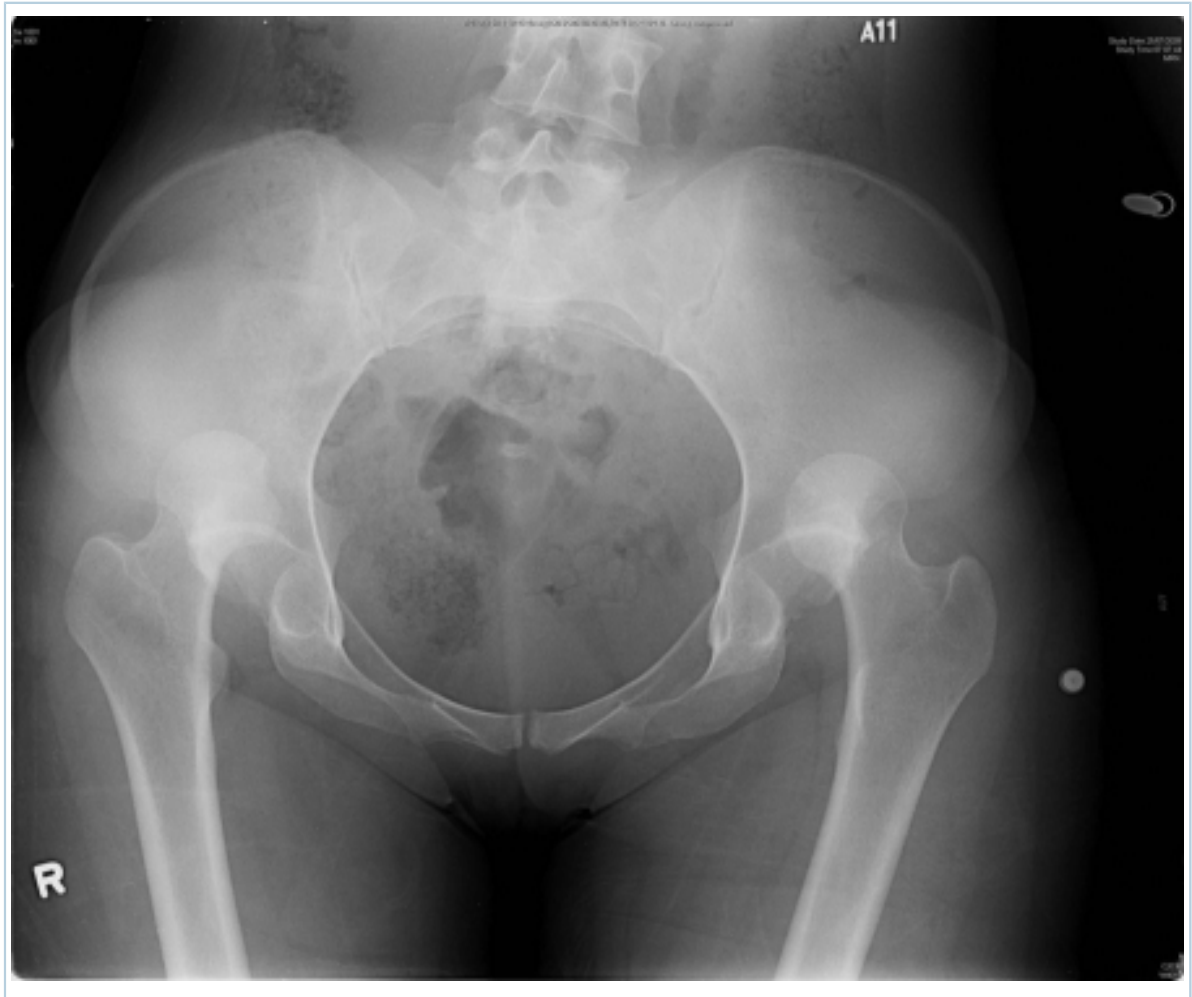


*Lateral x-ray view of a posterolateral elbow dislocation*

*Personal collection of Dr Paul Novakovich*

#### Hip dislocation

- Pelvic x-rays (Judet views, and inlet and outlet views) are routinely obtained to assess for possible concomitant fractures to the pelvis.
- A CT scan of the pelvis can identify specific fracture patterns, as well as smaller bony lesions (loose bodies) that may prevent a closed reduction and mandate an open reduction in the operating room.[4]



*X-ray showing bilateral hip posterior dislocation*

*Fan KY, et al. BMJ Case Rep. 2015 Mar 25;2015:bcr2014204031; used with permission*

## History and exam

### Key diagnostic factors

#### presence of risk factors (common)

- Key risk factors for joint dislocation are sports-related activities, loose ligaments, Ehlers-Danlos syndrome, males between adolescence and 40 years of age (shoulder and finger), women 61-80 years of age (shoulder), prior history of joint instability, skeletal or muscular dysplasia (patella), high Q angle (patella), external tibial torsion (patella), and patella alta.

#### characteristic posturing of joint (common)

- Anterior shoulder dislocations present with the arm in a characteristic position of external rotation and slight abduction. Posterior shoulder dislocations are rare and present with the arm held in adduction and internal rotation; the shoulder cannot be externally rotated, either actively or passively. Inferior

shoulder dislocations present with the arm fully abducted and elbow commonly flexed on or behind the head.[21] [22] [54]

- Patellar dislocation often presents with a swollen knee held in flexion with an obvious lateral prominence.
- Elbow dislocation typically presents with the elbow held in flexion.
- The classic appearance of posterior hip dislocation is with the hip in a position of flexion, internal rotation, and adduction. With anterior hip dislocations, the hip is classically held in external rotation, with mild flexion and abduction.[4]

### **pain (common)**

- Typically, patients have significant pain on movement and are very apprehensive about motion of the affected joint.

### **inability to move joint (common)**

- Patients are usually unable to move the joint or have incomplete range of motion.

### **tenderness (common)**

- Patients have tenderness around the dislocated joint.

### **swelling (common)**

- Patients often present with varying degrees of oedema around the dislocated joint.

### **sciatic nerve injury with hip dislocation (common)**

- May occur with stretching of the nerve over the posteriorly dislocated femoral head. Fragments of bone from a posterior wall fracture can also cause injury to the nerve.[4]

### **injury to the femoral artery, vein, or nerve with hip dislocation (common)**

- Anterior hip dislocation can cause injury to the femoral artery, vein, or nerve.

### **concomitant injury with hip dislocation (common)**

- Concomitant injuries are quite common with hip dislocations. Ipsilateral knee, patella, and femur fractures are common. Pelvic fractures and spine injuries may also be seen.[4]

### **cruciate ligament injury with patellar dislocation (common)**

- May accompany patellar dislocation.
- If pain permits, the physician should perform a full knee examination to determine concomitant injury to other ligamentous structures (e.g., anterior/posterior drawer and Lachman's tests to examine cruciate ligaments).

### **meniscal tears with patellar dislocation (common)**

- May accompany patellar.
- McMurray's test can be used to evaluate for meniscal tears in patients with patellar dislocation.

### **ligamentous injuries of the knee with patellar dislocation (common)**

- May accompany patellar dislocation.
- Varus and valgus stress testing can be used to evaluate the function of various knee ligaments.

**patellar or quadriceps tendon rupture with patellar dislocation (common)**

- May accompany patellar dislocation.
- The patient should demonstrate the ability to perform a supine straight leg raise to exclude rupture of these structures.[\[16\]](#) [\[32\]](#) [\[56\]](#) [\[57\]](#)

**Other diagnostic factors****ecchymosis with finger dislocation (common)**

- Finger dislocations may be accompanied by ecchymosis (bruising).

**haemarthrosis with patellar dislocation (uncommon)**

- Bleeding into joint spaces may occur with patellar dislocation.

## Risk factors

**Strong****sports-related activities**

- Most common cause of shoulder, finger, patellar, and elbow dislocations.[\[5\]](#) [\[7\]](#) [\[10\]](#) [\[14\]](#) [\[18\]](#) [\[33\]](#)

**motor vehicle accident (hip dislocation)**

- Axial loading of the femur towards the acetabulum is the classically described mechanism for hip dislocation. It is commonly observed with impact of the bent knee with a dashboard in a motor vehicle accident.[\[36\]](#)

**ligamentous laxity**

- Those with loose ligaments may experience sprains or dislocations more frequently.
- Loose ligaments may be generalised or confined to a few joints; the trait is usually hereditary. Affected patients have joints with a wide range of movement (e.g., 'double-jointed' people).

**Ehlers-Danlos syndrome**

- May be the cause of widespread laxity of connective tissue. This is a rare inherited condition characterised by unusually flexible joints, very elastic skin, and fragile tissues.

**males between adolescence and 30 years of age**

- Shoulder and finger injuries occur most commonly in this patient group following injuries on the sports field.[\[7\]](#) [\[8\]](#) [\[10\]](#)

**women aged 61-80 years (shoulder dislocation)**

- Incidence rates for shoulder dislocation are high in this patient group.[\[5\]](#) [\[7\]](#) [\[8\]](#)

**prior history of joint instability**

- Patients with a previous shoulder or patellar dislocation are more prone to re-dislocation.



**skeletal or muscular dysplasia**

- Causes patellar laxity as a result of hypermobility or lack of medial restraints and appears to be the most significant contributor to instability of the patellofemoral joint.[\[16\]](#) [\[31\]](#) [\[32\]](#)

**external tibial torsion (patellar dislocation)**

- Refers to a tibia that rotates outwards and is associated with over-pronated feet and patellar injuries.[\[30\]](#)

**patella alta (patellar dislocation)**


- Refers to an abnormally high patella in relation to the femur. It may result in dislocation of the patella.[\[26\]](#) [\[28\]](#) [\[29\]](#)

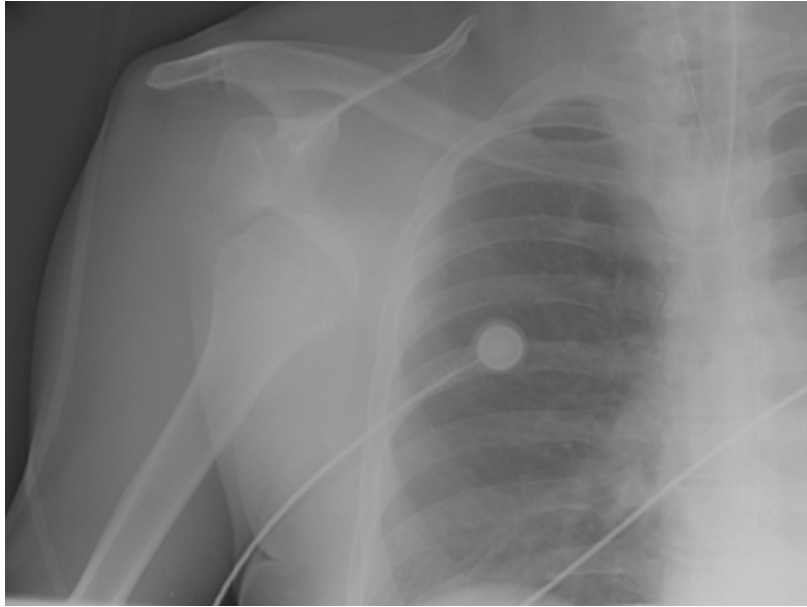

**Weak****high Q angle (patellar dislocation)**

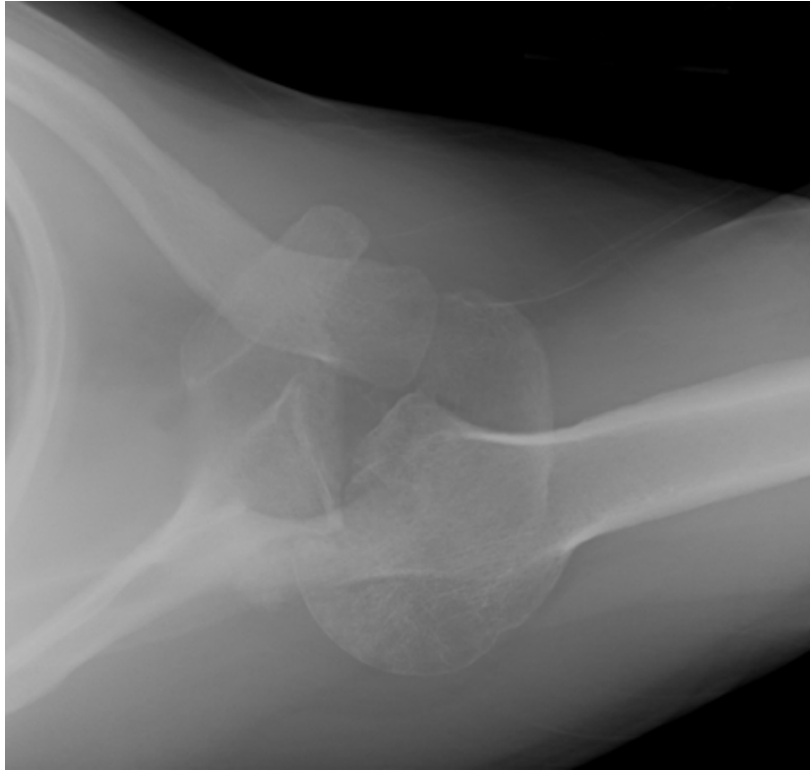
- A measurement of the angle between the quadriceps and the patellar tendon. It provides useful information about the alignment of the knee joint, which, if outside normal ranges, can be a precursor for over-use injuries such as dislocation.[\[27\]](#)
- A high Q angle often results in mal-tracking of the patella (i.e., it does not travel over the front of the knee joint as it should).

# Investigations

## 1st test to order

Test	Result
<p><b>plain x-rays of the shoulder</b></p> <ul style="list-style-type: none"> <li>An anteroposterior (AP) x-ray view of the shoulder should be taken with internal and external humeral rotation.[59]</li> <li>These should be accompanied by axillary lateral and/or scapular Y views to confirm diagnosis. Each of these x-ray views is 92% sensitive for acute shoulder dislocation.[60]</li> <li>On a scapular Y view, the humeral head lies anteriorly to the Y in anterior dislocations, and posteriorly to the Y in posterior dislocations. In standard AP views, the humeral head rests anteroinferiorly to the coracoid in anterior dislocations. However, in posterior dislocations, the humerus can appear to be reduced. Therefore, axillary or scapular Y views are essential for accurate diagnosis, as up to 79% of posterior shoulder dislocations are initially misdiagnosed. Axillary views can correctly identify posterior dislocations in 100% of patients when combined with AP views of the shoulder.[61] [62]</li> <li>An axillary oblique or modified axillary (Velpeau or West Point) view may also be used to confirm diagnosis.</li> <li>A possible fracture of the proximal humerus should be excluded, as attempts at reduction could further displace this fracture.</li> </ul>  <p><i>Scapular Y x-ray view showing an anterior fracture dislocation of the shoulder and fracture of the greater tuberosity</i>  <i>Personal collection of Dr Paul Novakovich</i></p>	<p><b>incongruity, subluxation, or loss of reduction of the glenohumeral joint</b></p>

Test	Result
 <p><i>Anteroposterior x-ray view of a shoulder showing an anteroinferior dislocation</i> <i>Personal collection of Dr Paul Novakovich</i></p>	
 <p><i>Anteroposterior x-ray view of a shoulder showing a missed posterior dislocation: the glenohumeral joint appears reduced</i> <i>Personal collection of Dr Paul Novakovich</i></p>	

Test	Result
<div data-bbox="233 188 1046 958"></div> <div data-bbox="365 981 919 1097"><p><i>Axillary lateral of a shoulder with a missed posterior dislocation: humeral head clearly is not reduced and is locked on the posterior rim of the glenoid</i> <i>Personal collection of Dr Paul Novakovich</i></p></div>	

Test	Result
<p><b>plain x-rays of the finger</b></p> <ul style="list-style-type: none"> <li>• Imaging is usually not necessary in the acute management of simple finger dislocations.</li> <li>• However, anteroposterior, oblique, and lateral views of the affected joint are mandatory in evaluating a hand injury to exclude fracture and/or dislocation.</li> <li>• X-rays should be closely inspected for associated fractures and avulsions, which may indicate ligament or tendon damage.</li> </ul> <div data-bbox="296 477 984 1675">  </div> <p><i>X-ray showing dislocation of the proximal interphalangeal joint, left index finger</i>  Hellerhoff, CC BY-SA 3.0 via Wikimedia Commons</p>	<p><b>incongruity of the proximal interphalangeal, distal interphalangeal, and/or metacarpophalangeal joint or a fracture</b></p>

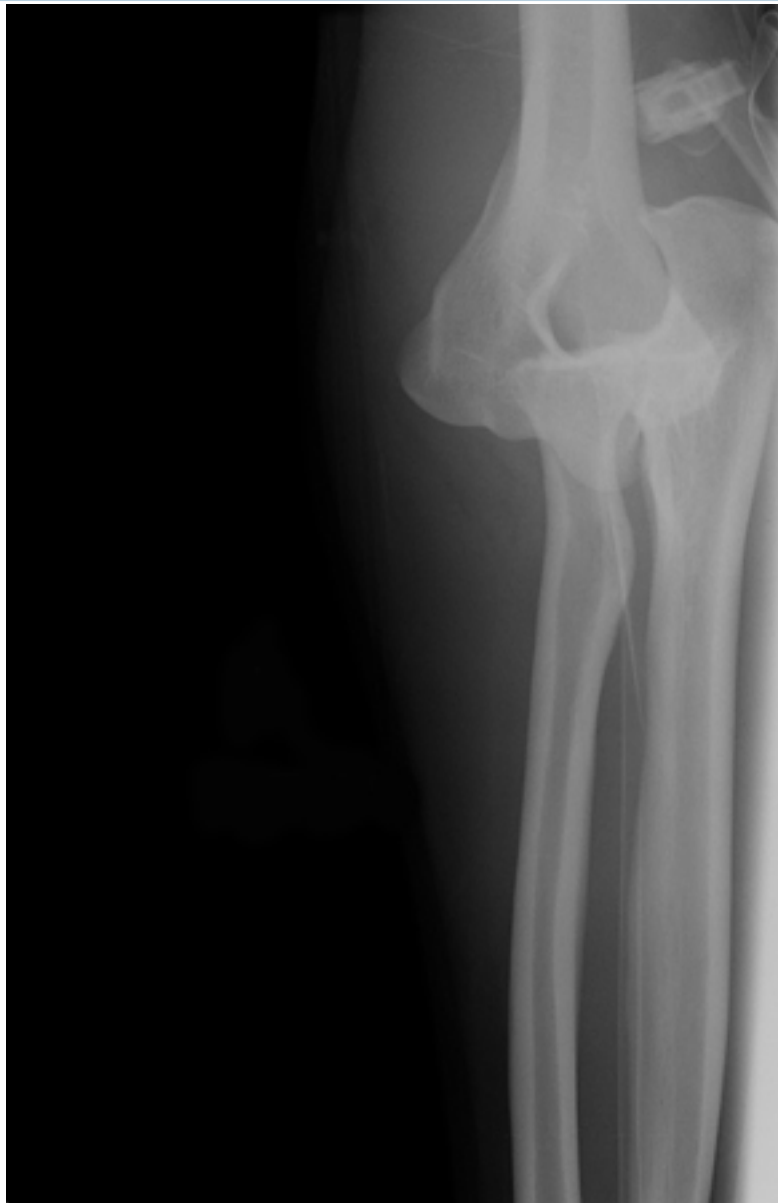Test	Result
<p><b>plain x-rays of the knee</b></p> <ul style="list-style-type: none"> <li>• Anteroposterior and lateral views of the knee are required. However, it is not uncommon for patella dislocations to reduce spontaneously during examination or following leg extension.</li> <li>• Dislocation can be confirmed on a Merchant or sunrise (infra-patellar) view, which demonstrates the medial facet of the patella resting on the lateral trochlea of the femur.</li> <li>• Images should also be inspected closely for evidence of osteochondral lesions.</li> </ul>  <p><i>Left knee radiograph demonstrating lateral patella dislocation</i>  <i>Yerimah G, et al. BMJ Case Rep. 2013 May 2:2013:bcr2013009832; used with permission</i></p>	<p><b>incongruity of the patellofemoral joint, or associated osteochondral fracture</b></p>
<p><b>plain x-rays of the elbow</b></p> <ul style="list-style-type: none"> <li>• In a posterior dislocation, standard AP and lateral views of the elbow joint show the radius and ulna lying posterior to the distal humerus.</li> <li>• The radial head should always be in line with the capitellum, and the olecranon should rest in the trochlea on a standard lateral view.</li> <li>• AP and lateral x-ray views of the forearm are also necessary to exclude associated forearm fractures (e.g., Monteggia fracture).</li> <li>• A radial head/capitellum view may be used to discern radial head and coronoid fractures.</li> </ul>	<p><b>incongruity of the radiocapitellar joint and the humeroulnar joint</b></p>



Test	Result
<div data-bbox="229 185 1046 1200">A lateral x-ray of the elbow joint showing a posterolateral dislocation. The humerus is displaced posteriorly and laterally relative to the ulna and radius. The joint surfaces are clearly separated, and the olecranon is visible in its normal position, indicating a complete dislocation.</div> <p data-bbox="352 1227 930 1279"><i>Lateral x-ray view of a posterolateral elbow dislocation</i> <i>Personal collection of Dr Paul Novakovich</i></p>	

## Test

## Result

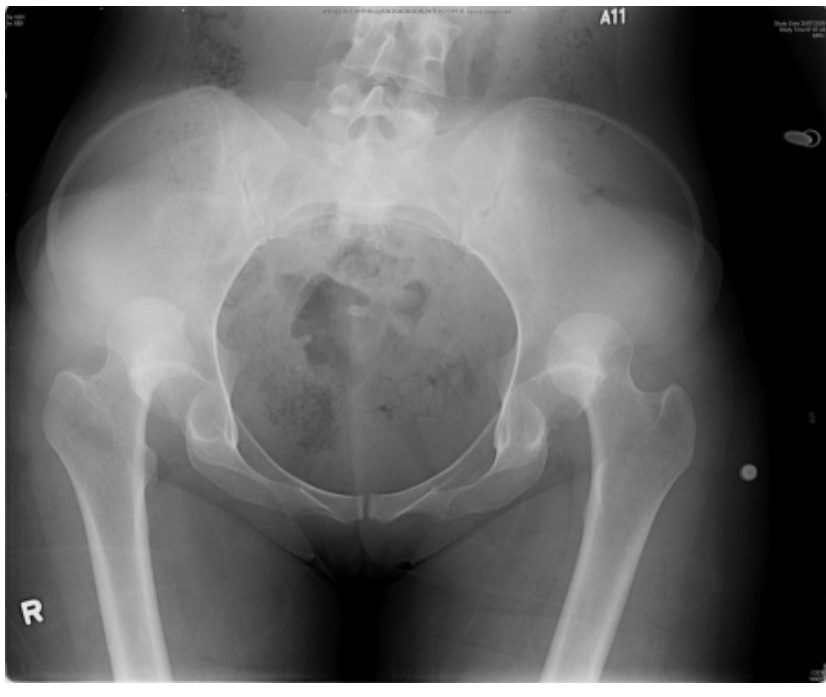


*Anteroposterior x-ray view of an elbow dislocation  
Personal collection of Dr Paul Novakovich*

### plain x-rays of the pelvis

- Pelvic x-rays (Judet views, and inlet and outlet views) are routinely obtained to assess for possible concomitant fractures to the pelvis.

**incongruity of the hip joint (anterior or posterior), or fracture of the femoral neck or pelvis**

Test	Result
<div data-bbox="225 188 1054 882"></div> <div data-bbox="383 896 895 985"><p><i>X-ray showing bilateral hip posterior dislocation</i> Fan KY, et al. <i>BMJ Case Rep.</i> 2015 Mar 25:2015:bcr2014204031; used with permission</p></div>	

## Other tests to consider

Test	Result
<b>MRI scan of the knee</b> <ul style="list-style-type: none"> <li>Provides excellent visualisation of soft tissue anatomy and should be ordered if any associated injuries are suspected.</li> <li>Useful in evaluating concomitant knee injuries including ligamentous and osteochondral lesions.</li> </ul>	<b>incongruity of the patellofemoral joint, or associated osteochondral fracture</b>
<b>MRI scan of the shoulder</b> <ul style="list-style-type: none"> <li>Provides excellent visualisation of soft tissue anatomy and should be ordered if any associated injuries are suspected.</li> <li>Can be useful to exclude concomitant rotator cuff tears, which are not uncommon.</li> </ul>	<b>rotator cuff tears</b>
<b>CT scan of the elbow</b> <ul style="list-style-type: none"> <li>Can further delineate fractures (e.g., of the radial head and coronoid process) if plain film radiography is insufficient to confirm diagnosis.</li> </ul>	<b>incongruity of the radiocapitellar joint and the humeroulnar joint</b>
<b>CT scan of the pelvis</b> <ul style="list-style-type: none"> <li>Can identify specific fracture patterns, as well as smaller bony lesions (loose bodies) that may prevent a closed reduction and mandate an open reduction in the operating room.<sup>[4]</sup></li> </ul>	<b>fracture of the femoral neck or pelvis; presence of loose bodies</b>
<b>arteriogram of the knee or shoulder</b> <ul style="list-style-type: none"> <li>If a vascular injury is of concern based on the physical examination, an arteriogram may be required.</li> <li>Allows radiographic evaluation of the injured vessel by demonstrating interruption of arterial blood flow from the proximal to the distal end of the affected vessel.</li> </ul>	<b>disruption of integrity of the popliteal artery around the knee, axillary artery in the shoulder, and brachial artery in the arm, with concomitant vascular injury</b>

## Emerging tests

Test	Result
<b>ultrasound of the shoulder</b> <ul style="list-style-type: none"> <li>Point-of-care ultrasound (POCUS) has been suggested as an additional diagnostic tool for shoulder dislocation. It has the potential to reduce time to diagnosis and reduction, as well as radiation exposure and healthcare costs. One systematic review found that POCUS had 100% sensitivity and specificity for the identification of shoulder dislocations and reductions, and 96.8% sensitivity and 99.7% specificity for the detection of associated fractures.<sup>[63]</sup></li> </ul>	<b>humeral head displaced anterior or posterior to the glenoid; an anechoic or hypoechoic disruption in the normal contour of the (hyperechoic) bone is seen if coexistent fracture is present</b>

## Differentials

Condition	Differentiating signs / symptoms	Differentiating tests
<b>Proximal humerus fracture</b>	<ul style="list-style-type: none"> <li>• There is usually shoulder and upper arm swelling and bruising.</li> <li>• Possibility of paraesthesias or weakness in the arm.</li> </ul>	<ul style="list-style-type: none"> <li>• Anteroposterior (AP) and lateral view x-rays in the scapular plane and an axillary view confirm the fracture.</li> </ul>
<b>Distal clavicle fracture</b>	<ul style="list-style-type: none"> <li>• Pain, particularly on upper extremity movement, and swelling.</li> <li>• After the swelling has subsided, the fracture can often be felt through the skin.</li> </ul>	<ul style="list-style-type: none"> <li>• AP x-ray shows fracture.</li> </ul>
<b>Acromioclavicular joint separation</b>	<ul style="list-style-type: none"> <li>• Pain is a common symptom of this injury and is usually severe.</li> <li>• Evidence of traumatic injury to the shoulder, such as swelling and bruising, is also commonly found.</li> </ul>	<ul style="list-style-type: none"> <li>• AP x-ray rules out dislocation.</li> <li>• If diagnosis is unclear, an x-ray taken while the patient is holding a weight in the hand may be helpful. The force of the weight accentuates any shoulder joint instability and shows the effects of the injury better.</li> </ul>
<b>Rotator cuff tear</b>	<ul style="list-style-type: none"> <li>• Shoulder pain is the most common presenting symptom.</li> <li>• Pain is typically aggravated by over-head activities.</li> <li>• Patients may also complain of functional weakness, loss of motion, night pain, and pain in the deltoid region.</li> <li>• Acute pain and weakness may be seen following traumatic rotator cuff rupture.</li> </ul>	<ul style="list-style-type: none"> <li>• AP x-ray or MRI scan rules out dislocation.</li> </ul>
<b>Soft tissue contusion of the shoulder</b>	<ul style="list-style-type: none"> <li>• Tenderness, swelling, and bruising of the shoulder.</li> </ul>	<ul style="list-style-type: none"> <li>• An x-ray or MRI scan rules out dislocation.</li> </ul>
<b>Scapula fracture</b>	<ul style="list-style-type: none"> <li>• Relatively rare.</li> <li>• Most patients present after high-energy trauma.</li> <li>• Typically, there is swelling, tenderness, crepitus, and bruising over the scapular region.</li> </ul>	<ul style="list-style-type: none"> <li>• AP, lateral, and axillary x-ray views of the shoulder/scapula show fracture.</li> </ul>
<b>Biceps tendon rupture</b>	<ul style="list-style-type: none"> <li>• Some patients report a sudden pain in the anterior shoulder during activity.</li> <li>• This acute pain, frequently described as sharp in nature,</li> </ul>	<ul style="list-style-type: none"> <li>• AP and axillary x-ray views are the most useful and rule out dislocation.</li> </ul>

Condition	Differentiating signs / symptoms	Differentiating tests
	may be accompanied by an audible pop or a perceived snapping sensation.	
<b>Distal humerus fracture</b>	<ul style="list-style-type: none"> <li>• Pain occurs with palpation or movement of the shoulder or elbow.</li> <li>• Swelling and bruising are usually present.</li> </ul>	<ul style="list-style-type: none"> <li>• AP and lateral views of the humerus, as well as trans-thoracic and axillary views of the shoulder, should be adequate to visualise a fracture.</li> </ul>
<b>Radial head fracture</b>	<ul style="list-style-type: none"> <li>• Usually presents with a history of a fall on the outstretched hand.</li> <li>• Localised swelling, tenderness, and decreased motion of radial head.</li> <li>• The wrist, especially the distal radioulnar joint, may be damaged simultaneously.</li> </ul>	<ul style="list-style-type: none"> <li>• Most radial head injuries can be adequately assessed with standard plain radiography of the elbow.</li> </ul>
<b>Coronoid fracture</b>	<ul style="list-style-type: none"> <li>• Usually occurs in combination with a radial head fracture.</li> <li>• Patients often present with a history of a fall on the outstretched hand and a deformity of the elbow.</li> <li>• The presence of an unstable reduction of the elbow is suggestive of an associated coronoid fracture.</li> </ul>	<ul style="list-style-type: none"> <li>• Radiographs of the elbow in the AP, lateral, and, if required, oblique views should be obtained to ascertain clearly the extent of bony injury.</li> </ul>
<b>Ulnar collateral ligament injury</b>	<ul style="list-style-type: none"> <li>• Medial elbow tenderness and swelling are the most notable findings.</li> <li>• Medial elbow pain is the most common symptom in athletes who throw.</li> </ul>	<ul style="list-style-type: none"> <li>• Plain x-ray or MRI scan rules out dislocation.</li> </ul>
<b>Monteggia fracture</b>	<ul style="list-style-type: none"> <li>• Depending on the type of fracture and severity, patients may experience elbow swelling, deformity, crepitus, and paraesthesia or numbness.</li> <li>• Some patients may not have severe pain at rest, but elbow flexion and forearm rotations are limited and painful.</li> </ul>	<ul style="list-style-type: none"> <li>• Views of the forearm in orthogonal planes (planes at 90° to each other) are needed with the wrist and elbow joints included.</li> <li>• Separate radiographs of the elbow should also be obtained to assess the proximal radioulnar joint, ulnohumeral articulation, and radiocapitellar joint.</li> </ul>
<b>Soft tissue contusion of the knee</b>	<ul style="list-style-type: none"> <li>• Patients usually state that something struck the affected knee.</li> </ul>	<ul style="list-style-type: none"> <li>• Bony pathology can usually be distinguished from soft tissue injury with plain radiographs.</li> </ul>



Condition	Differentiating signs / symptoms	Differentiating tests
	<ul style="list-style-type: none"> <li>On physical examination, there should not be any valgus laxity on abduction stress testing.</li> </ul>	
<b>Chondromalacia patellae</b>	<ul style="list-style-type: none"> <li>Softening and fissuring of articular hyaline cartilage.</li> <li>Patients may report anterior knee pain, especially while climbing stairs.</li> <li>Compression of the patella during flexion and extension of the knee elicits crepitation and discomfort.</li> </ul>	<ul style="list-style-type: none"> <li>Over-exposed lateral x-ray of the knee.</li> <li>Axillary x-ray views of the knee determine which facet is involved.</li> </ul>
<b>Patellar tendon rupture</b>	<ul style="list-style-type: none"> <li>Palpable defect in patellar ligament.</li> <li>With complete tears, patient is unable to extend the knee.</li> <li>With partial tears, patient is able to extend the knee, but extension may not be full.</li> </ul>	<ul style="list-style-type: none"> <li>Lateral radiograph of the knee may reveal small avulsion from the inferior patellar pole.</li> </ul>
<b>Quadriceps tendon rupture</b>	<ul style="list-style-type: none"> <li>Usually occurs in patients over 40 years of age.</li> <li>Patients typically present with acute knee pain, swelling, and functional loss following a stumble, fall, or giving way of the knee.</li> <li>Obvious suprapatellar swelling, bruising, and tenderness are present.</li> </ul>	<ul style="list-style-type: none"> <li>Standing AP x-ray or MRI scan rules out dislocation.</li> </ul>
<b>Medial synovial plica of the knee</b>	<ul style="list-style-type: none"> <li>Symptoms may mimic those of a torn meniscus (e.g., snapping, clicking, and medial joint line tenderness).</li> </ul>	<ul style="list-style-type: none"> <li>Standing AP x-ray or MRI scan rules out dislocation.</li> </ul>
<b>Anterior cruciate ligament injury</b>	<ul style="list-style-type: none"> <li>Subluxation on twisting, turning, or pivoting. Some patients can feel it coming on; other patients are not able to feel it and may experience frequent falls due to their injury.</li> </ul>	<ul style="list-style-type: none"> <li>Standing AP x-ray or MRI scan rules out dislocation.</li> </ul>
<b>Posterior cruciate ligament injury</b>	<ul style="list-style-type: none"> <li>History of hyper-extension mechanism or a blow to anterior aspect of the knee.</li> <li>Difficulty going down inclines, descending stairs, or running down hills.</li> </ul>	<ul style="list-style-type: none"> <li>Standing AP x-ray or MRI scan rules out dislocation.</li> </ul>
<b>Medial collateral ligament injury of the knee</b>	<ul style="list-style-type: none"> <li>Sensation of side-to-side toggle with activity.</li> </ul>	<ul style="list-style-type: none"> <li>Standing AP x-ray or MRI scan rules out dislocation.</li> </ul>

Condition	Differentiating signs / symptoms	Differentiating tests
	<ul style="list-style-type: none"> <li>• Difficulty with twisting or turning.</li> <li>• Difficulty with running or pivoting.</li> </ul>	
<b>Posterolateral knee injury</b>	<ul style="list-style-type: none"> <li>• Sensation of side-to-side toggle of knee with activity.</li> <li>• Weakness of foot and ankle that may be secondary to a concurrent common peroneal nerve neuropraxia or complete injury.</li> </ul>	<ul style="list-style-type: none"> <li>• Standing AP x-ray or MRI scan rules out dislocation.</li> </ul>
<b>Meniscal tear</b>	<ul style="list-style-type: none"> <li>• Patients frequently complain of mechanical symptoms in the knees such as catching, giving way, locking, clicking, and popping.</li> <li>• On physical examination, meniscal injuries may present with quadriceps atrophy; they often have an associated knee effusion, and tenderness localised to the joint line may be present.</li> </ul>	<ul style="list-style-type: none"> <li>• Standing AP x-ray or MRI scan rules out dislocation.</li> </ul>
<b>Osteochondral fracture of the knee</b>	<ul style="list-style-type: none"> <li>• Patients have immediate pain and swelling of the knee at the time of injury.</li> <li>• They also have significant pain with weight-bearing.</li> <li>• The mechanism of injury usually involves a high-force, twisting injury of the knee.</li> </ul>	<ul style="list-style-type: none"> <li>• Diagnosis can be confirmed by an MRI scan.</li> </ul>
<b>Ligament avulsions of the finger</b>	<ul style="list-style-type: none"> <li>• Patients often experience diffuse pain, swelling, and tingling.</li> </ul>	<ul style="list-style-type: none"> <li>• AP, lateral, and oblique radiographs of the affected digit rule out dislocation.</li> </ul>
<b>Tendon avulsions of fingers</b>	<ul style="list-style-type: none"> <li>• Patients often experience diffuse pain, swelling, and tingling.</li> </ul>	<ul style="list-style-type: none"> <li>• AP, lateral, and oblique radiographs of the affected digit rule out dislocation.</li> </ul>
<b>Mallet finger</b>	<ul style="list-style-type: none"> <li>• Patients notice the inability to extend the distal joint, although full passive extension remains intact.</li> <li>• The dorsum of the joint may be slightly tender and swollen, but often the injury is painless or nearly painless.</li> </ul>	<ul style="list-style-type: none"> <li>• AP and lateral radiographs centred at the distal interphalangeal joint of the affected finger are required to rule out dislocation.</li> </ul>
<b>Gamekeeper's thumb</b>	<ul style="list-style-type: none"> <li>• A weakened ability to hold objects, decreased thumb stability (catching</li> </ul>	<ul style="list-style-type: none"> <li>• Plain x-ray or MRI scan rules out dislocation.</li> </ul>

Condition	Differentiating signs / Differentiating tests symptoms	
	the thumb in objects, etc.), local swelling, local pain, and bruising.	
<b>Femoral neck fracture</b>	<ul style="list-style-type: none"> <li>No differentiating signs or symptoms. Pain may preclude weight-bearing.</li> </ul>	<ul style="list-style-type: none"> <li>Femoral head fracture identified, but the femoral head remains reduced on all radiographs.</li> <li>CT of the hip clearly shows the reduced hip joint.</li> </ul>

## Approach

Joint dislocations are usually managed with closed reduction as soon as possible to decrease potential complications including soft tissue injury, articular surface injury, and neurovascular compromise. Reduction usually requires sedation and analgesia.

Patients with abnormal neurological function associated with a joint dislocation should be referred to an orthopaedic specialist.

A period of immobilisation should be followed by active motion exercises and isometric strengthening exercises.

### Shoulder dislocation

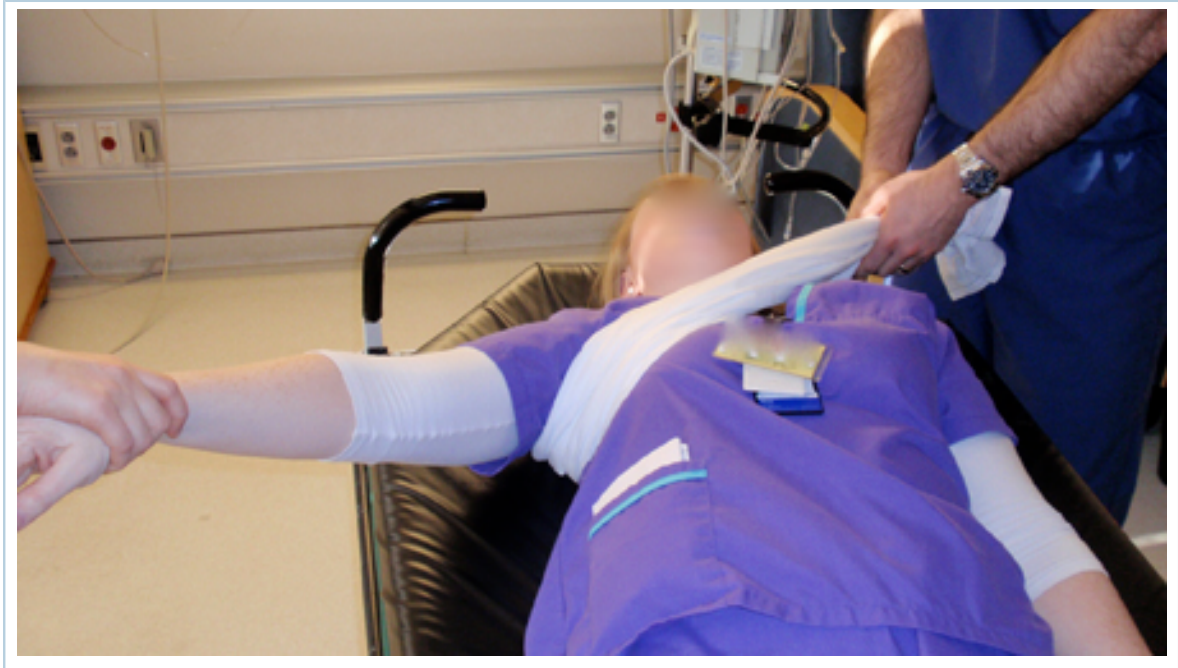
Once the diagnosis has been confirmed, reduction should be attempted. For a successful outcome, adequate analgesia and sedation are necessary before the reduction procedure is attempted.

There are numerous reduction manoeuvres for shoulder injuries, which are usually performed under local anaesthesia (i.e., intra-articular lidocaine) combined with procedural sedation (e.g., intravenous morphine, midazolam, or etomidate). Procedural sedation has the added advantage of reducing spasm in the muscles of the rotator cuff. The choice for sedation depends on the treating physician and must be accompanied by continuous monitoring of the patient with capnography and pulse oximetry, as well as frequent blood pressure measurements. Monitoring should begin before any medicines are administered and continue until the patient is fully awake. Multiple studies have shown that local anaesthesia on its own is equivalent to intravenous sedation.<sup>[64] [65] [66]</sup> However, local anaesthesia on its own should be reserved for patients with contraindications to procedural sedation.

Each reduction method works by abduction and external rotation to disengage the humeral head from the glenoid, with axial traction to reduce it. The following are examples of reduction manoeuvres for anterior dislocations.

#### Traction-countertraction method

- The patient is placed supine on the bed. A sheet is looped around the axilla with one free end on the chest and the other underneath the back. The 2 ends should be of even length. An assistant uses these free ends to apply countertraction. Then the practitioner abducts the arm to 90° and flexes the elbow to 90°. With the forearm, slow longitudinal traction is then applied to the affected extremity.

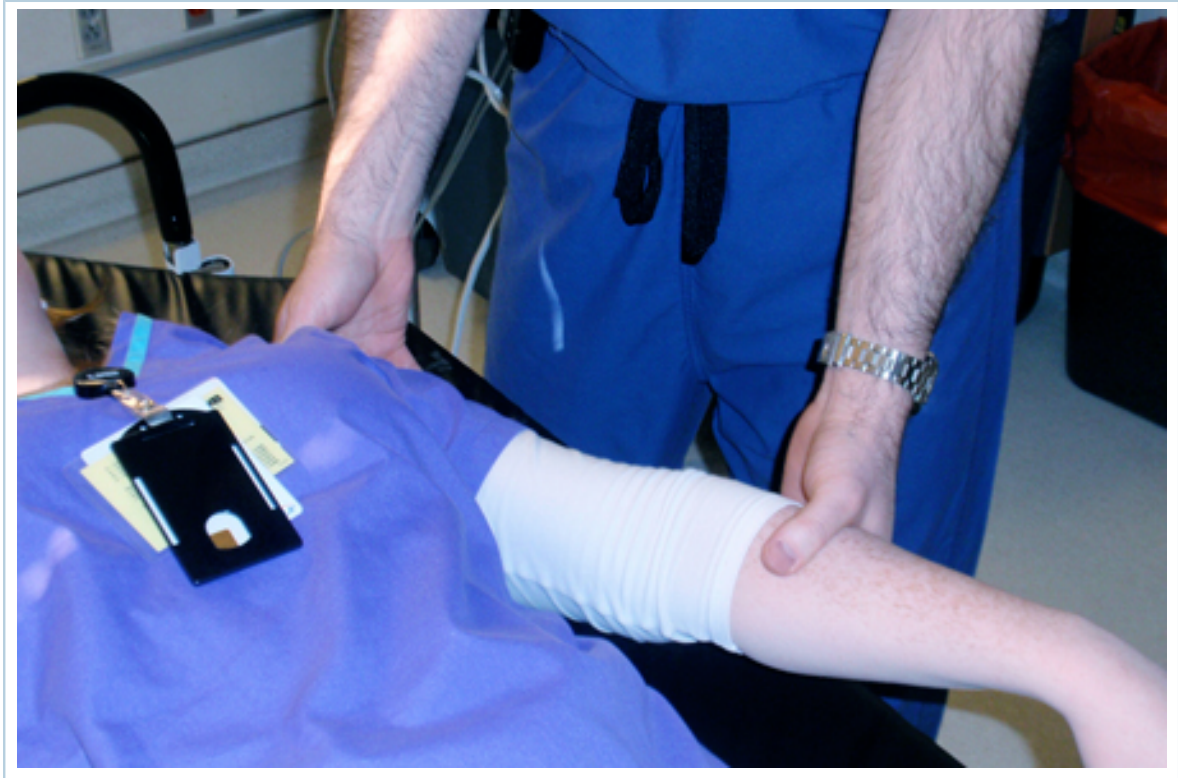

*Traction-countertraction method: with patient supine on the bed, a sheet is looped around the axilla with one free end on the chest and the other underneath the back; the 2 ends should be of even length and are used by an assistant to apply countertraction. The practitioner abducts the arm to 90° and flexes the elbow to 90°; the forearm is used to apply slow longitudinal traction to the affected extremity*

*Personal collection of Dr Paul Novakovich*

#### Modified Milch's technique

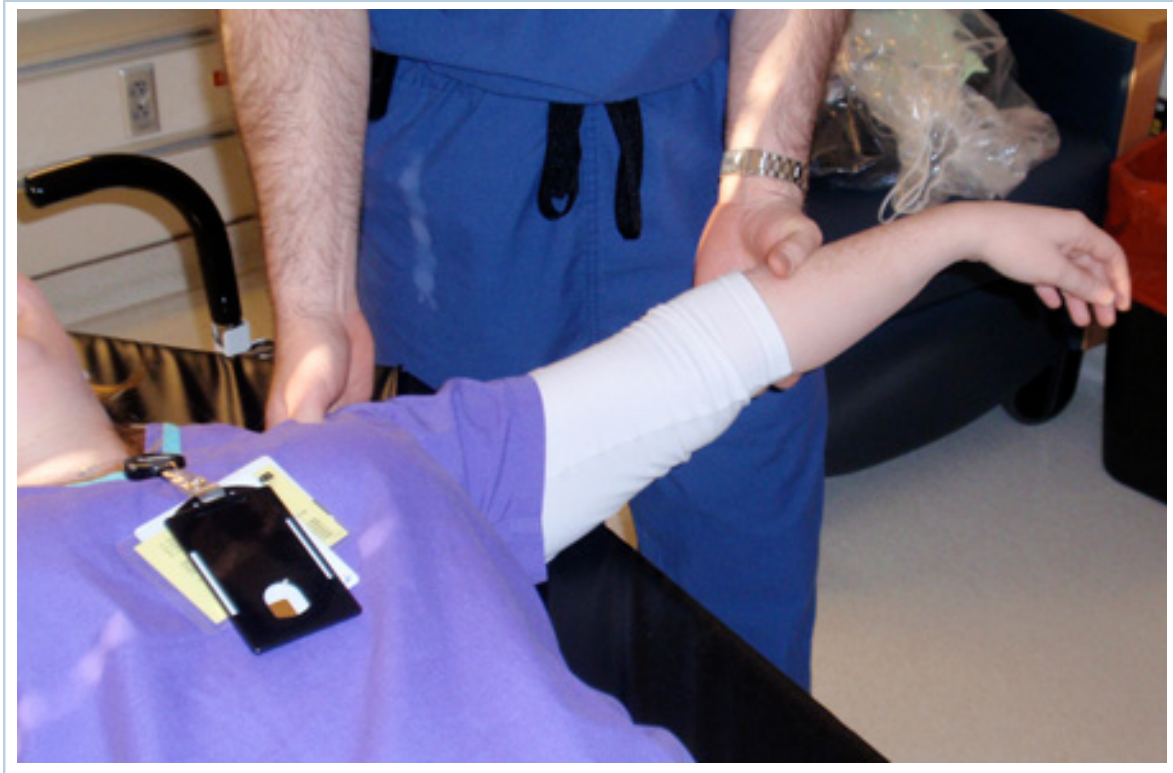- The modified Milch's technique has been reported to be effective in 100% of dislocations without the use of sedation.<sup>[67]</sup> The patient is positioned supine on a bed with the head of the bed elevated approximately 20° to 30°. The arm is slowly abducted and externally rotated without application of longitudinal traction. The practitioner pauses in the case of pain or resistance. Once the arm has reached a position of 90° abduction and 90° external rotation, the shoulder should spontaneously reduce. If not, the humeral head can be palpated in the axilla, and superolateral pressure can then be applied using the thumb and index finger to help guide the humeral head back into the glenoid.<sup>[55] [67]</sup>



*Milch's technique for shoulder reduction, part 1: patient is positioned supine on a bed with the head of the bed elevated about 20° to 30°, then the arm is slowly abducted and externally rotated without application of longitudinal traction (in case of pain or resistance, the practitioner pauses)*

*Personal collection of Dr Paul Novakovich*



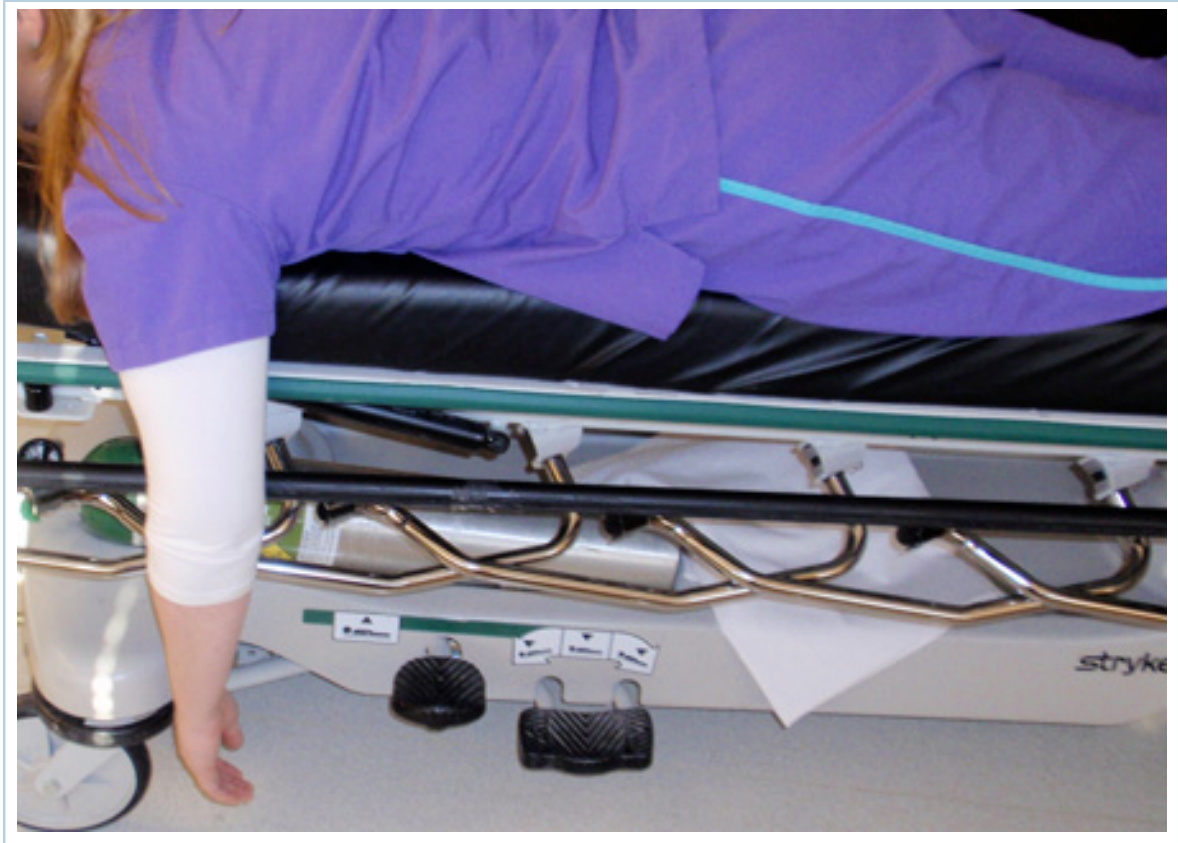

*Milch's technique for shoulder reduction, part 2: once the arm has reached a position of 90° abduction and 90° external rotation, the shoulder dislocation should spontaneously reduce; if not, the humeral head can be palpated in the axilla and superolateral pressure can then be applied using the thumb and index finger to help guide the humeral head back into the glenoid*

*Personal collection of Dr Paul Novakovich*

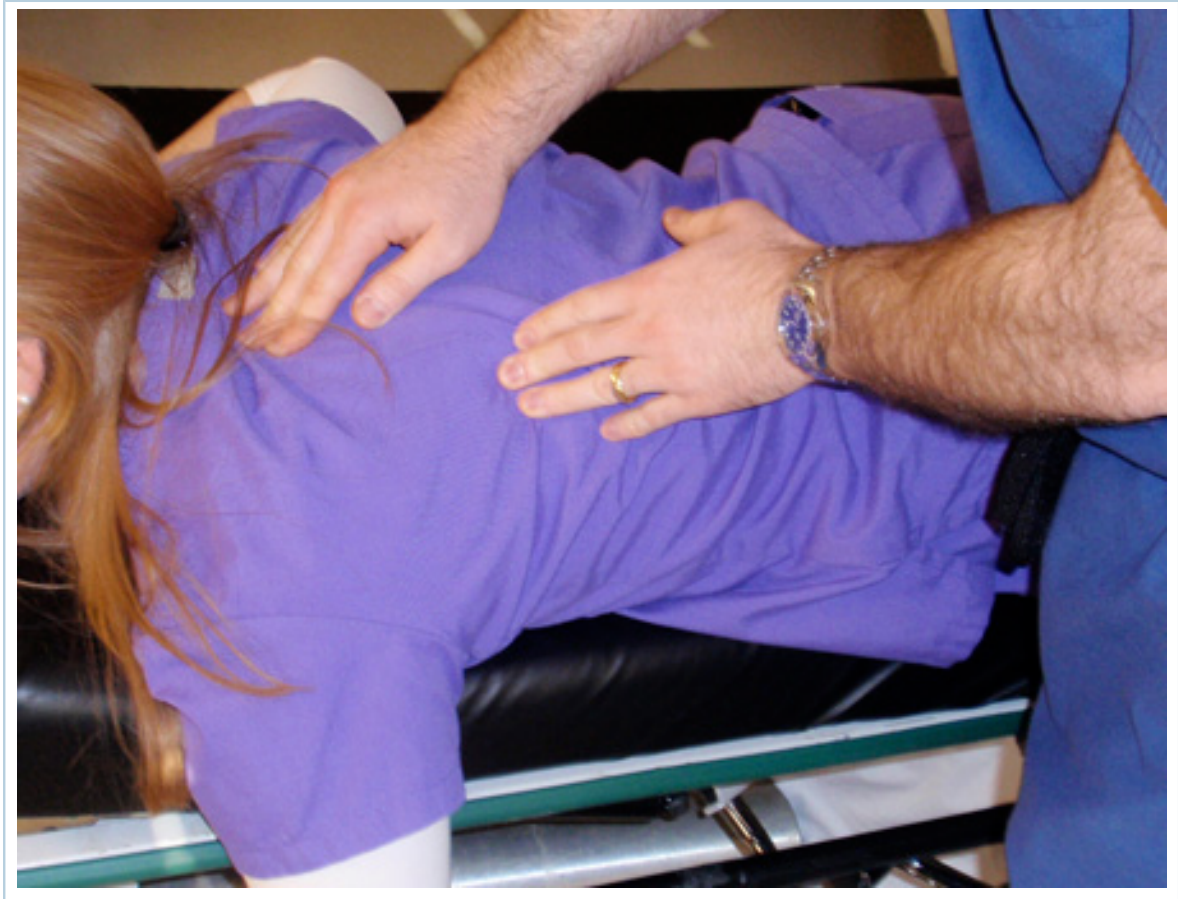#### Stimson's method or scapular manipulation technique

- This method is reported to be effective in 96% of shoulder dislocations.[68] The patient is positioned prone on the stretcher with the affected shoulder slightly off the stretcher. The arm is placed perpendicular to the floor (90° forward flexion) with the stretcher high enough to keep the hand from resting on the floor. Weights of 2.3 to 4.5 kg or 1-L bottles of sterile water are wrapped around the wrist using stockinette and hung high enough to not touch the floor. Reduction should occur within 10 to 20 minutes. Reduction can be facilitated by external rotation, or application of the scapular manipulation technique (where one hand is placed on the superolateral border of the scapula and the other hand on the inferomedial border of the scapula, and pressure is applied to rotate the superior border laterally and the inferior border medially).[55] [68]



*Stimson's method: patient is positioned prone on the stretcher with the affected shoulder slightly off the stretcher; arm is placed perpendicular to the floor (90° forward flexion) with the stretcher high enough to keep the hand from resting on the floor, then weights of 2.3 to 4.5 kg or 1-L bottles of sterile water are wrapped around the wrist using stockinette and hung high enough to not touch the floor*

*Personal collection of Dr Paul Novakovich*



*Scapular manipulation technique: one hand is placed on the superolateral border of the scapula with the other hand on the inferomedial border of the scapula, and pressure is applied to rotate the superior border laterally and the inferior border medially*

*Personal collection of Dr Paul Novakovich*

#### Sitting scapular manipulation technique

- The patient sits upright with an assistant applying scapular pressure using the scapular manipulation technique. The practitioner then flexes the affected arm to 90°, placing one hand on the clavicle and the other on the wrist. Gentle traction is applied to the arm with pressure applied to the clavicle. Simultaneously, the assistant performs the scapular manipulation.

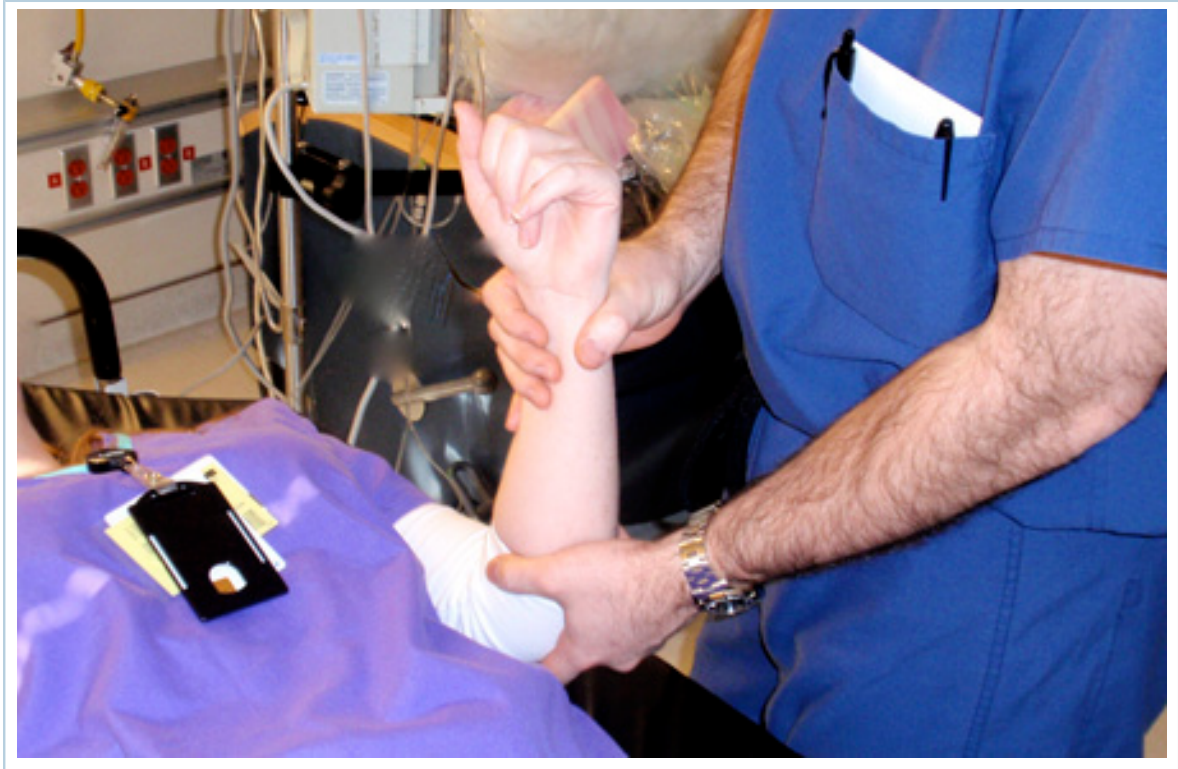
#### Spaso technique

- This is reported to be effective in 88% of shoulder dislocations.<sup>[69]</sup> The patient is positioned supine on the bed. The affected shoulder is slowly forward flexed to 90°. Gentle longitudinal traction is applied while the shoulder is slowly externally rotated. Care must be taken to keep the medial border of the scapula firmly pressed against the bed.

#### External rotation method

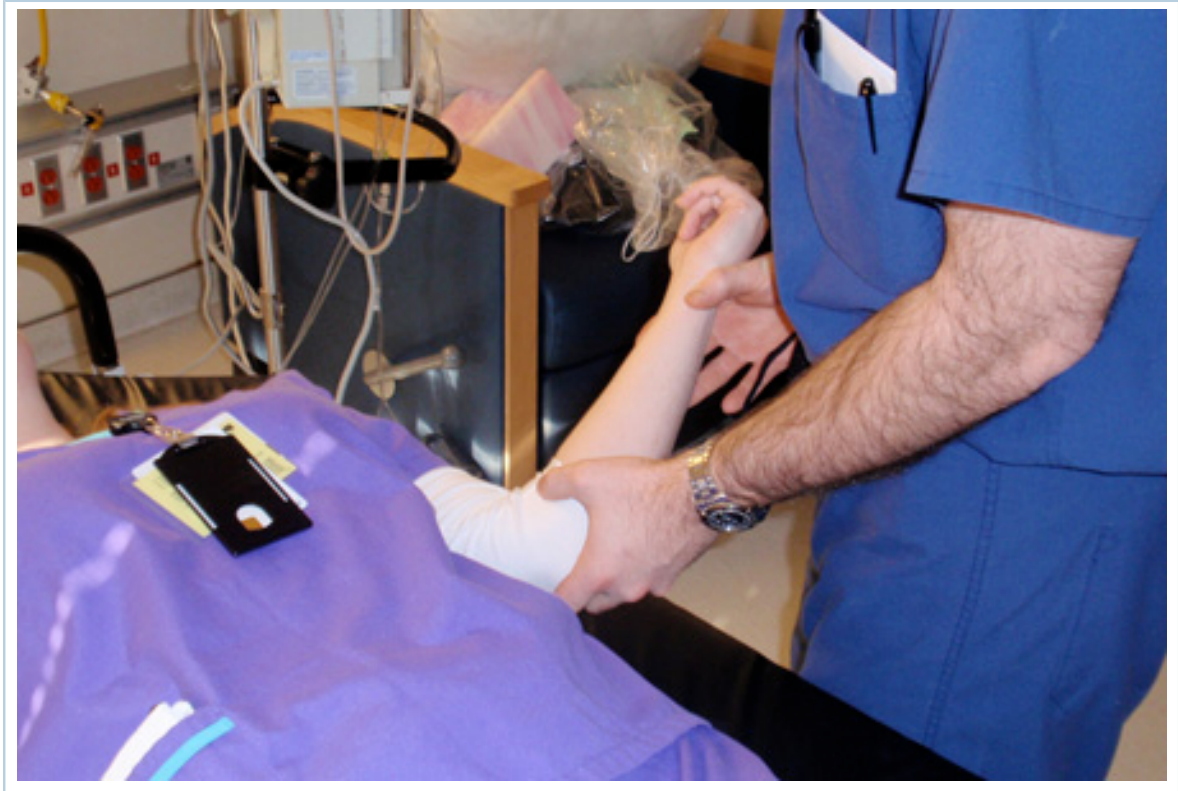- This was initially described by Leidelmeier and is reported to be successful in 78% of patients.<sup>[66]</sup> The patient is positioned supine on the bed and the affected extremity is gently adducted until it is parallel to the long axis of the body. The elbow is then flexed to 90°. By applying gentle pressure to the wrist, the practitioner slowly externally rotates the arm, taking time to allow spasms and contractions to pass. Finally, the arm is externally rotated to 90° (i.e., perpendicular to the long axis of the body). After approximately 5 minutes, the shoulder should reduce.





*External rotation method for shoulder reduction, part 1: patient is positioned supine, and affected extremity is gently adducted until it is parallel to the long axis of the body; elbow is then flexed to 90°*

*Personal collection of Dr Paul Novakovich*

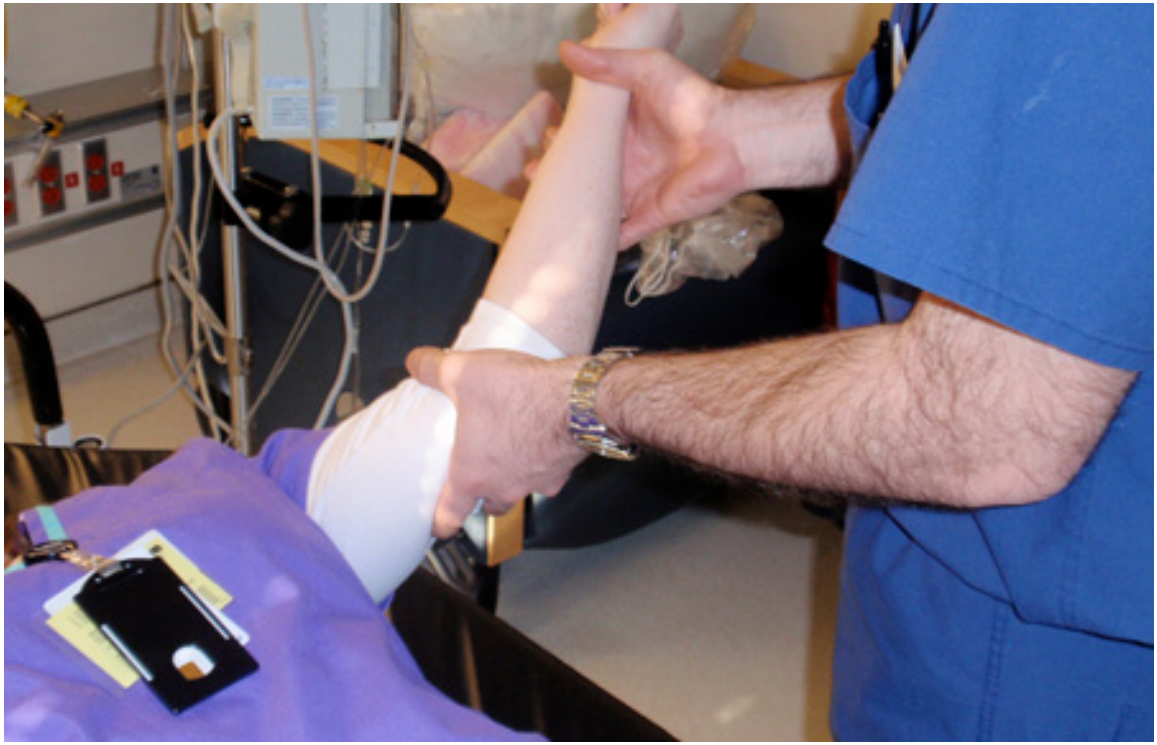

*External rotation method for shoulder reduction, part 2: by applying gentle pressure to the wrist, the practitioner slowly externally rotates the arm, taking time to allow spasms and contractions to pass; finally, the arm is externally rotated to 90° (i.e., perpendicular to the long axis of the body); shoulder dislocation should reduce after about 5 minutes*

*Personal collection of Dr Paul Novakovich*

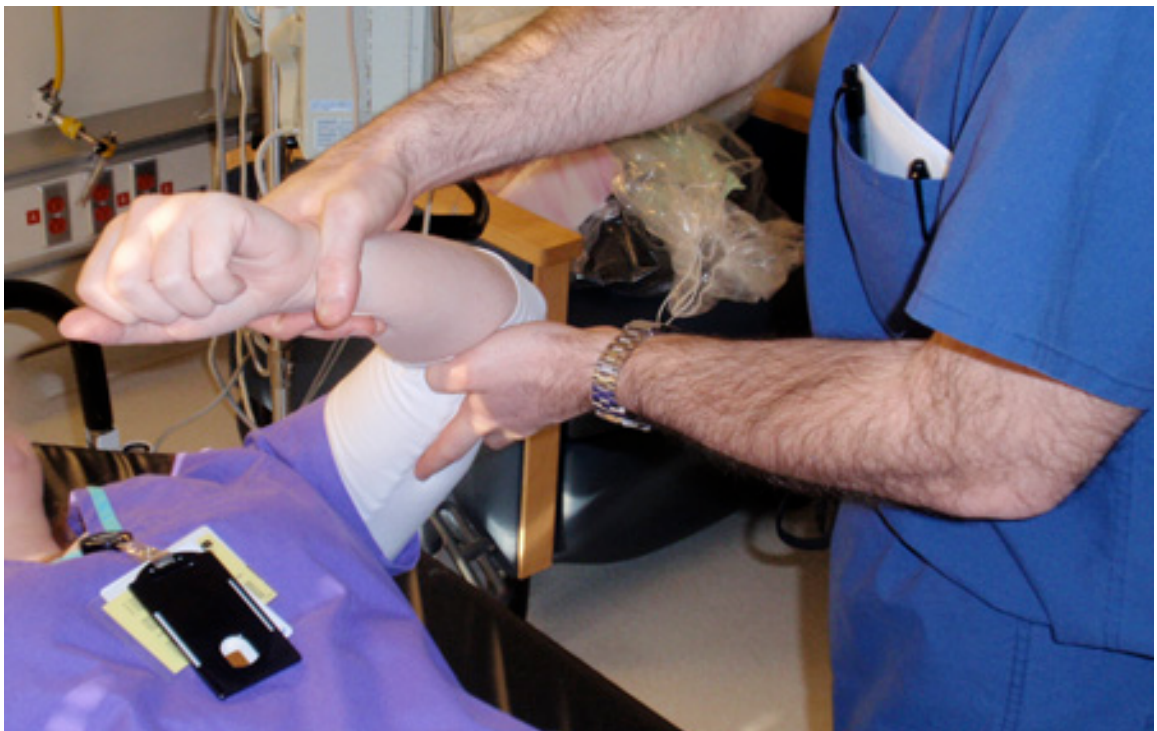#### Kocher's method

- This method is more complex than other methods and may be associated with complications (e.g., fractures, brachial plexus injury and vascular injury). It uses in-line traction of the arm while abducted to 45°. While traction is maintained, the arm is externally rotated and the elbow is brought across the chest to the mid-line. The arm is then internally rotated until the patient's hand touches the shoulder.



*Kocher's method of shoulder reduction, part 1: in-line traction of the arm while abducted to 45°; while traction is maintained, arm is externally rotated and elbow is brought across the chest to the mid-line*

*Personal collection of Dr Paul Novakovich*



*Kocher's method of shoulder reduction, part 2: arm is internally rotated until the patient's hand touches the shoulder*

*Personal collection of Dr Paul Novakovich.*

FARES (Fast Reliable and Safe) method

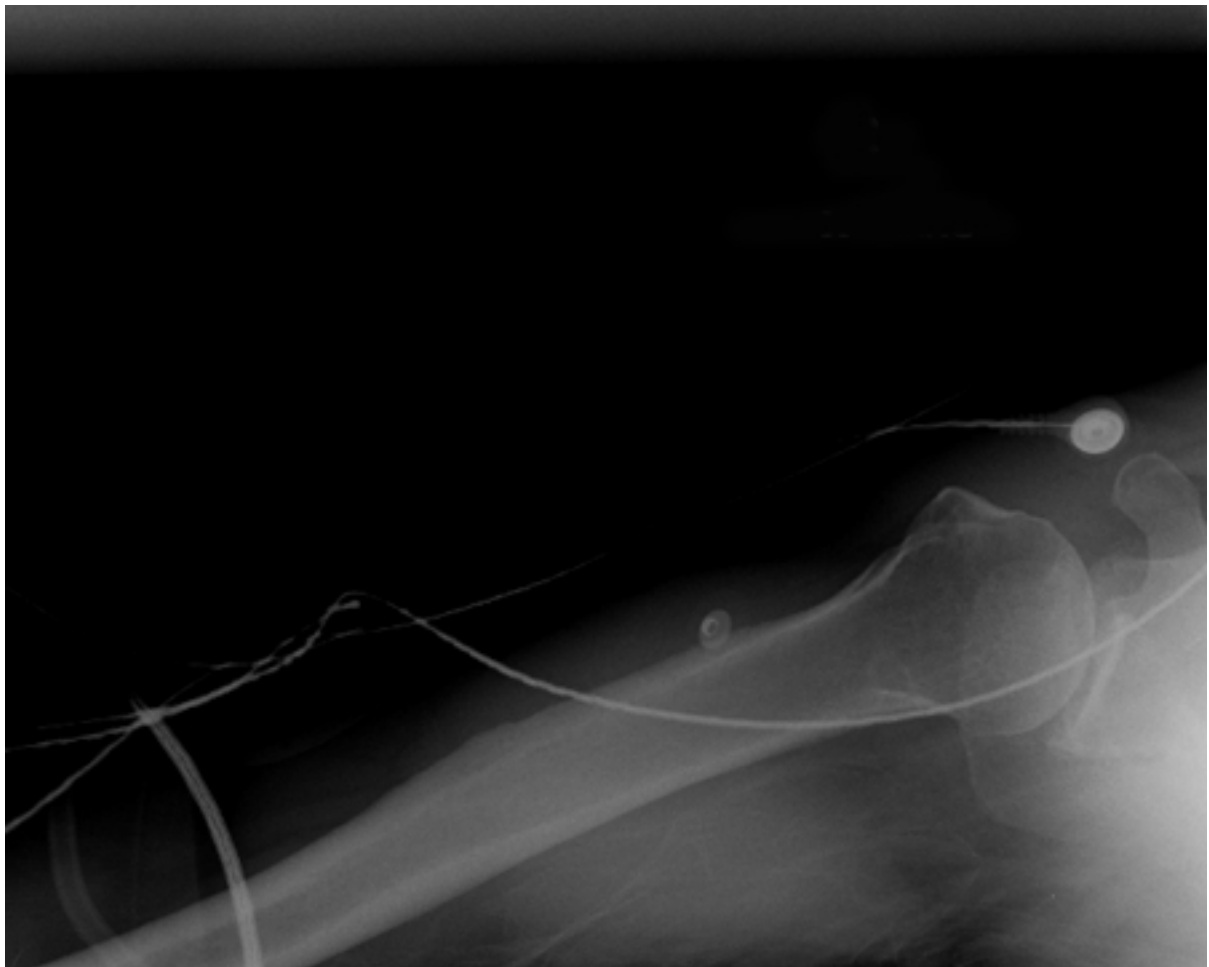

- The physician holds the hand of the patient at the patient's side with the elbow extended and in neutral rotation. Longitudinal traction is applied and the arm is moved into abduction (no countertraction needed). As the arm is abducted, short vertical oscillations are performed to relax the musculature. As the arm passes 90° of abduction, the arm is then externally rotated, and at 120° of arm abduction, the arm typically reduces. When compared with the Kocher and traction-countertraction methods, this method is faster and requires less sedation.<sup>[70]</sup>

Irrespective of the technique used, the physician should feel a distinct clunk as the shoulder reduces. The arm should be immobilised and placed in a sling or a sling and swathe. Anteroposterior (AP) and lateral x-rays should be obtained to confirm reduction of the humeral head and to ensure that no iatrogenic fractures have occurred during the reduction.<sup>[71]</sup>

Once the patient is alert, it is important to perform a neurological examination, with emphasis on the axillary, radial, ulnar, and median nerves. The vascular status of the hand should also be re-assessed to ensure that the axillary or brachial artery has not been injured during the reduction.

The patient should wear the sling for approximately 3 weeks. In subsequent weeks, active-assisted range of motion and isometric strengthening exercises should be advised. Generally, by week 12, limited return to sporting activities is permitted, followed by full return to sporting activities as tolerated by week 16.



*Normal axillary x-ray view of a reduced shoulder dislocation, showing congruency of the glenohumeral joint*

*Personal collection of Dr Paul Novakovich*

### Surgical referral

Patients under 25 years of age should be referred to an orthopaedic surgeon for assessment, as this age group is at significant risk for recurrence. Long-term data support primary stabilisation via anatomical Bankart's repair (over simple arthroscopic lavage or non-operative treatment) for young, high-risk patients with a first-time shoulder dislocation.[72] [73] One systematic review found that patients, particularly active men in their 20s and 30s, undergoing treatment for a first-time anterior shoulder dislocation with a surgical stabilisation procedure, can be expected to experience significantly lower rates of recurrent instability and a significantly decreased need for a future stabilisation procedure when compared with patients treated non-operatively.[74]

The Latarjet's procedure is a commonly used approach for managing chronic and recurrent anterior shoulder dislocation, especially in the presence of bone loss.[75] It involves transplant of the coracoid process to the scapular neck and has demonstrated excellent long-term clinical outcomes and return to sport rate.[76] It may be more effective than Bankart's repair for recurrent instability of the shoulder.[77] Both open and arthroscopic Latarjet's procedures result in significantly improved function and outcome in patients with anterior shoulder instability.[78] However, the Latarjet's procedure has been associated with a complication rate of 15% to 30%; specific complications include graft-related issues (11.7%), hardware-related complications (6.5%), nerve injuries (0.7% to 4%), recurrent instability (8%), and revision (5%).[75]

## Finger dislocation

The goal of treatment for finger dislocations is to restore joint congruity by means of closed reductions. Certain situations can make congruent reduction difficult. These include volar plate entrapment, volar dislocations, and fracture dislocations.

Reduction of finger dislocation often requires the use of a local anaesthetic, typically lidocaine 1%. A neurovascular examination of the digit is essential before reduction is performed because the local anaesthetic may cause complete hypoaesthesia of the finger. Two sets of nerves run on the radial and ulnar side of each digit. Generally, the dorsal nerves lie on the 10-o'clock and 2-o'clock positions, while the palmar digital nerves lie on the 8-o'clock and 4-o'clock positions. Infiltration of lidocaine in these quadrants results in effective anaesthesia for reducing a dislocated finger.

Dorsal proximal interphalangeal (PIP) and distal interphalangeal (DIP) dislocations

- The first step in reduction is to recreate the injury by hyper-extending the PIP or DIP. This should be followed by light axial traction applied to the finger with pressure applied to the base of the dislocated digit until the joint is relocated. Occasionally, these joints will not reduce because of entrapment of the volar plate, and consultation with a hand surgeon will be required. If the joint is stable, buddy taping to an adjacent digit or placement of a splint in slight flexion is an appropriate measure. Neutral splinting for dorsal PIP dislocations can also be used and is reported to avoid post-splinting flexion contractures.[79] Post-reduction x-rays should be obtained to confirm congruency of the joint and to ensure that there are no associated fractures.[15]

Volar DIP and PIP dislocations

- These are more likely to be unstable, but the goals of reduction are the same as for dorsal dislocations. The finger should be flexed with mild axial traction applied to the digit. The physician should then apply pressure to the base of the digit until reduction is complete. Post-reduction x-rays should be obtained to confirm congruence of the joint and to ensure that there are no associated fractures. The finger should be placed in an extension splint immobilising the smallest number of joints possible. If concentric reduction is not possible because of soft tissue entrapment, consultation with a hand surgeon is warranted.

### Metacarpophalangeal (MCP) dislocation

- With simple dislocations, the finger is usually held in extension, and there is some contact between the joint surfaces. The wrist should be flexed to relax the flexor tendons, and the affected digit should then be hyper-extended. The physician should then apply a volar-directed pressure to the dorsum of the affected digit. It is paramount that excessive traction not be applied, as a simple dislocation can be converted into a complex MCP dislocation with significant soft tissue entrapment. If this occurs, the joint will often become irreducible and require operative treatment.[24] [80]

Simple dislocations can be buddy taped, while fracture dislocations require immobilisation in a splint. Post-reduction x-rays should be obtained to confirm congruence of the joint and to ensure that there are no associated fractures. Following reduction, the physician should ensure adequate perfusion to the finger by assessing capillary refill. Post-reduction, patients should begin protected range of motion as pain permits. In treating finger dislocations, instituting early motion and providing stability must be balanced.

## Patellar dislocation

Patellar dislocation often presents to the emergency department or to the clinic having already spontaneously reduced.

In the patient presenting with an acute patellar dislocation, a reduction should be performed with the goal being the concentric reduction of the patella into the femoral notch. Patellar dislocations have been reported to be accompanied by intra-articular lesions in 5% to 71% cases.[16] [56] [57] In these cases, orthopaedic consultation is warranted, as open reduction surgery may be required.

For a successful outcome, adequate analgesia and sedation is necessary before the reduction procedure is attempted. Lateral dislocation is easily managed using local anaesthesia (i.e., intra-articular lidocaine) combined with procedural sedation (e.g., intravenous morphine, midazolam, or etomidate). Procedural sedation has the added advantage of reducing muscle spasm. The choice for sedation depends on the treating physician and must be accompanied by continuous monitoring of the patient with capnography and pulse oximetry, as well as frequent blood pressure measurements. Monitoring should begin before any medicines are administered and continue until the patient is fully awake.

Following adequate analgesia and sedation, the patient should be placed either supine or in a seated position. The affected knee should be flexed to decrease the tension on the quadriceps muscle. The physician should apply a medial-directed force to the lateral aspect of the patella while slowly extending the leg. A palpable clunk should confirm reduction of the patella. Upon successful reduction, the affected extremity should be placed in a knee immobiliser and the patient advised to bear weight on the joint as tolerated.

Merchant, AP, and lateral knee plain x-rays should be ordered to ensure that the patella is reduced. The x-rays should be closely examined for evidence of any osteochondral defects that may have been created during the reduction. Post-reduction, patients should begin protected range of motion as pain permits.

### Surgery versus non-operative approach

A Cochrane review concluded that large multicentre clinical trials are needed to determine whether a surgical or non-operative approach is preferred for the management of patellar dislocation.[81] A systematic review of overlapping meta-analyses found that operative treatment of first-time patellar

dislocations results in a lower recurrence rate but no improvement in functional outcome scores compared with non-operative management.[82]

Medial patellofemoral ligament reconstruction for patellofemoral instability was associated with a high rate of success in one systematic review of the literature.[83] Complications were, however, common (complication rate 26.1%).

## Elbow dislocation

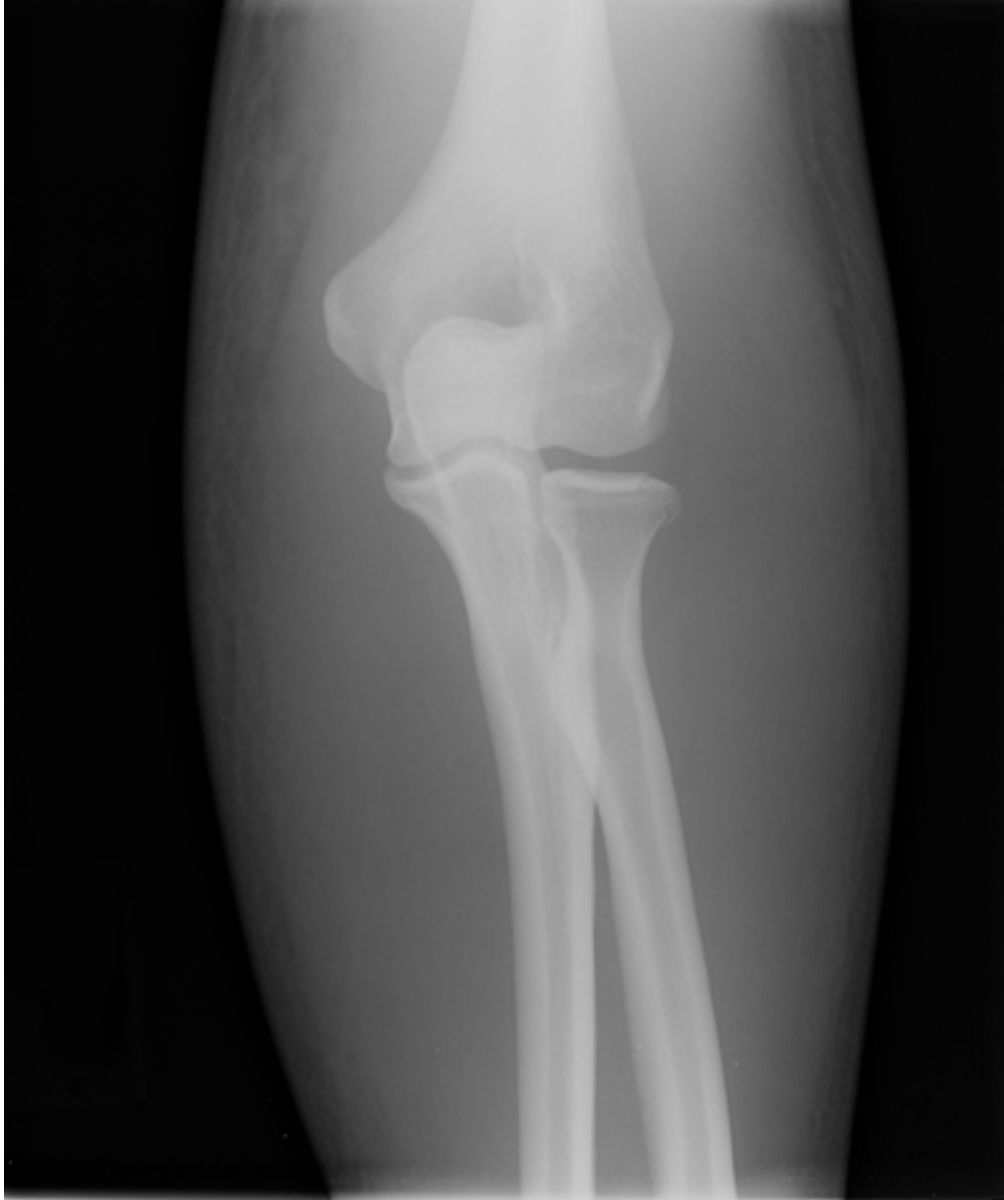For a successful outcome, adequate analgesia and sedation are necessary before the reduction procedure is attempted.

The reduction is usually performed using local anaesthesia (i.e., intra-articular lidocaine) combined with procedural sedation (e.g., intravenous morphine, midazolam, or etomidate). Procedural sedation has the added advantage of reducing muscle spasm. The choice for sedation depends on the treating physician and must be accompanied by continuous monitoring of the patient with capnography and pulse oximetry, as well as frequent blood pressure measurements. Monitoring should begin before any medicines are administered and continue until the patient is fully awake.

The patient should be supine on the bed with the physician positioned on the affected side with an assistant close to the head of the bed. In young children, management of radial head subluxation/dislocation (nursemaid's elbow) may be more effective and less painful when performed with the arm in pronation as opposed to supination.[84] The arm should be initially extended to 30° flexion. The overall gross alignment of the elbow is then manipulated so that the olecranon appears centred between the medial and lateral condyle of the humerus. The forearm is then slowly flexed to approximately 90° with the physician providing longitudinal traction to the forearm while the assistant provides countertraction to the patient's humerus. The arm is then flexed even further with direct downward pressure applied to the olecranon.[44]

If reduction is successful, the physician should feel an audible clunk as the elbow is reduced. It is important not to flex the arm forcefully if there is significant resistance because the coronoid process is typically perched on the distal humerus. Forceful flexion without adequate traction can cause a fracture of this structure, which will result in future instability. Upon reduction, the arm is placed in a posterior splint at 90° flexion with neutral rotation of the forearm.[44] An AP and lateral plain film radiograph of the elbow should be obtained to ensure that the joint is concentrically reduced.

Once the patient is alert, it is important to perform a neurological examination, with emphasis on the radial, ulnar, and median nerves. The vascular status of the hand should also be re-assessed to ensure that the brachial artery has not been injured during the reduction. Several studies have shown better outcomes with early mobilisation than with immobilisation in patients with simple dislocations. Patients should initially be splinted in a posterior splint for comfort with instructions to begin mobilisation when pain permits. Immobilisation should last no longer than 2 weeks.[33] [85] [86] [87] [88]



*Anteroposterior x-ray view of a reduced elbow dislocation*

*Personal collection of Dr Paul Novakovich*

## Hip dislocation

Early reduction and avoidance of complications (e.g., osteonecrosis) is the immediate goal in the setting of an acute hip dislocation.

Every effort should be made to obtain reduction of the dislocated hip within 6 hours from injury, via closed or open reduction techniques to maximise functional recovery.<sup>[4]</sup> Urgent reduction of the femoral head into the acetabulum is indicated in almost all cases. The tenuous blood supply to the femoral head is easily compromised with a dislocation, and the incidence of osteonecrosis has been shown to increase if reduction is delayed. Unless an associated hip or femoral neck fracture is known to exist, a closed reduction under sedation or anaesthesia can be attempted in the accident and emergency department.<sup>[89]</sup>

There are several described techniques for reduction of both anterior and posterior hip dislocations. Hip reduction can be attempted using in-line traction, with the patient lying supine, followed by applying a force opposing the vector of the initial injury. Initially, the traction should be applied in a steady manner to overcome muscular spasms.

Allis's method:

- Traction is applied in line with the deformity. The patient is placed supine, with the surgeon standing above the patient on the stretcher. Initially, the surgeon applies in-line traction, while the assistant applies counter-traction, stabilising the pelvis. While increasing the traction force, the surgeon slowly increases the degree of flexion to approximately 70°. Gentle rotational motions of the hip and slight adduction will often help the femoral head clear the lip of the acetabulum. A lateral force to the proximal thigh may assist in reduction. An audible 'clunk' is a sign of a successful closed reduction.<sup>[90]</sup>

Stimson's gravity technique:

- The patient is placed prone on the stretcher, with the affected leg hanging off the side of the stretcher. This brings the extremity into a position of 90° of both hip and knee flexion. In this position, the assistant immobilises the pelvis and the surgeon applies an anteriorly directed force on the proximal calf. Gentle rotation of the limb may assist in reduction.<sup>[90]</sup>

Hip immobilisation is difficult. Patients usually do well with assisted ambulation using crutches, and bear weight as tolerated. Crutches should be used until the patient can walk relatively pain-free, and the knee immobiliser should be kept in place until strength improves and symptoms abate. Moderate quadriceps strengthening should begin when the patient is comfortable.

## Treatment algorithm overview

Please note that formulations/routes and doses may differ between drug names and brands, drug formularies, or locations. Treatment recommendations are specific to patient groups: [see disclaimer](#)

Acute ( summary )		
shoulder dislocation		
	1st	reduction and immobilisation ± surgical referral
	plus	rehabilitation
finger dislocation		
■ dorsal proximal interphalangeal and distal interphalangeal dislocations	1st	reduction and immobilisation
	plus	rehabilitation
■ volar distal interphalangeal and proximal interphalangeal dislocations	1st	reduction and immobilisation
	plus	rehabilitation
■ metacarpophalangeal dislocation	1st	reduction and immobilisation
	plus	rehabilitation
patellar dislocation		
	1st	reduction and immobilisation
	plus	rehabilitation
elbow dislocation		
	1st	reduction and immobilisation
	plus	rehabilitation
hip dislocation		
	1st	reduction and bracing
	plus	rehabilitation



# Treatment algorithm

Please note that formulations/routes and doses may differ between drug names and brands, drug formularies, or locations. Treatment recommendations are specific to patient groups: [see disclaimer](#)

## Acute

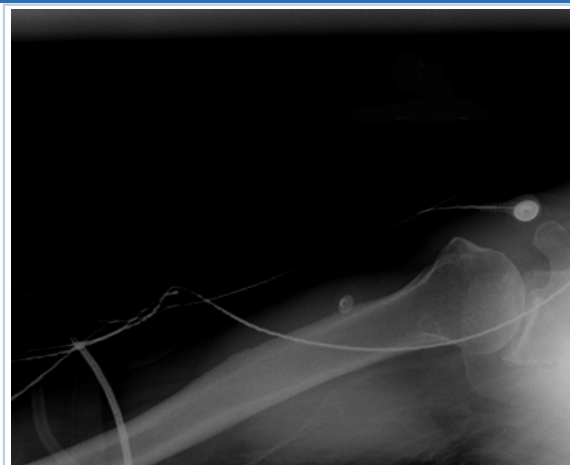### shoulder dislocation

#### 1st

#### reduction and immobilisation ± surgical referral

- » Once the diagnosis has been confirmed, reduction should be attempted. For a successful outcome, adequate analgesia and sedation are necessary before the reduction procedure is attempted. There are numerous reduction manoeuvres for shoulder injuries, which are usually performed under local anaesthesia (i.e., intra-articular lidocaine) combined with procedural sedation (e.g., intravenous morphine, midazolam, or etomidate).
- » The choice for sedation depends on the treating physician and must be accompanied by continuous monitoring of the patient with capnography and pulse oximetry, as well as frequent blood pressure measurements.
- » Local anaesthesia on its own should be reserved for patients with contraindications to procedural sedation.
- » Each of the reduction methods works by abduction and external rotation to disengage the humeral head from the glenoid, with axial traction to reduce it. Irrespective of the technique used, the physician should feel a distinct clunk as the shoulder reduces.
- » The arm should be immobilised and placed in a sling or a sling and swathe.
- » An anteroposterior (AP) and lateral radiograph should be obtained to confirm reduction of the humeral head, and to ensure that no iatrogenic fractures have occurred during the reduction.<sup>[71]</sup>

## Acute



*Normal axillary x-ray view of a reduced shoulder dislocation, showing congruency of the glenohumeral joint*  
 Personal collection of Dr Paul Novakovich

- » Once the patient is alert, it is important to perform a neurological and vascular examination.
- » The patient should wear the sling for approximately 3 weeks.
- » Patients under 25 years of age should be referred to an orthopaedic surgeon for consideration of further intervention (i.e., possible arthroscopic or open repair), as this age group is at significant risk for recurrence. Long-term data support primary stabilisation via anatomical Bankart's repair (over simple arthroscopic lavage or non-operative treatment) for young, high-risk patients with a first-time shoulder dislocation.[72] [73] One systematic review found that patients, particularly active men in their 20s and 30s, undergoing treatment for a first-time anterior shoulder dislocation with a surgical stabilisation procedure, can be expected to experience significantly lower rates of recurrent instability and a significantly decreased need for a future stabilisation procedure when compared with patients treated non-operatively.[74]
- » The Latarjet's procedure is a commonly used approach for managing chronic and recurrent anterior shoulder dislocation, especially in the presence of bone loss.[75] It involves transplant of the coracoid process to the scapular neck and has demonstrated excellent long-term clinical outcomes and return to sport rate.[76] It may be more effective than Bankart's repair for recurrent instability of the shoulder.[77] Both open and arthroscopic Latarjet's procedures result in

## Acute

significantly improved function and outcome in patients with anterior shoulder instability.[78] However, the Latarjet's procedure has been associated with a complication rate of 15% to 30%; specific complications include graft-related issues (11.7%), hardware-related complications (6.5%), nerve injuries (0.7% to 4%), recurrent instability (8%), and revision (5%).[75]

**plus rehabilitation**

Treatment recommended for ALL patients in selected patient group

» In subsequent weeks, active-assisted range of motion and isometric strengthening exercises should be advised.

## finger dislocation

■ **dorsal proximal interphalangeal and distal interphalangeal dislocations**

**1st reduction and immobilisation**

» Reduction of finger dislocation often requires the use of a local anaesthetic, typically lidocaine 1%. A neurovascular examination of the digit is essential before reduction is performed because the local anaesthetic may cause complete hypoaesthesia of the finger.

» The first step in reduction is to recreate the injury by hyper-extending the proximal interphalangeal (PIP) or distal interphalangeal joint.

» This should be followed by light axial traction applied to the finger with pressure applied to the base of the dislocated digit until the joint is relocated.

» If the joint is stable, buddy taping to an adjacent digit or placement of a splint in slight flexion is an appropriate measure.

» Neutral splinting for dorsal PIP dislocation can also be used and is reported to avoid post-splinting flexion contractures.[79]

» Post-reduction x-rays should be obtained to confirm congruency of the joint and to ensure there are no associated fractures.[15]

» Following reduction, the physician should ensure adequate perfusion to the finger by assessing capillary refill.

» If attempts at reduction fail, consult a specialist hand surgeon.

**plus rehabilitation**

## Acute

■ **volar distal interphalangeal and proximal interphalangeal dislocations****1st**

Treatment recommended for ALL patients in selected patient group

» Post-reduction, patients should begin protected range of motion as pain permits. In treating finger dislocations, instituting early motion and providing stability must be balanced.

**reduction and immobilisation**

» These are more likely to be unstable.

» Reduction of finger dislocation often requires the use of a local anaesthetic, typically lidocaine 1%. A neurovascular examination of the digit is essential before reduction is performed because the local anaesthetic may cause complete hypoaesthesia of the finger.

» The finger should be flexed with mild axial traction applied to the digit.

» The physician should then apply pressure to the base of the digit until reduction is complete.

» Post-reduction x-rays should be obtained to confirm congruence of the joint and to ensure that there are no associated fractures.

» The finger should be placed in an extension splint immobilising the smallest number of joints possible.

» Following reduction, the physician should ensure adequate perfusion to the finger by assessing capillary refill.

**plus****rehabilitation**

Treatment recommended for ALL patients in selected patient group

» Post-reduction, patients should begin protected range of motion as pain permits. In treating finger dislocations, instituting early motion and providing stability must be balanced.

■ **metacarpophalangeal dislocation****1st****reduction and immobilisation**

» Reduction of finger dislocation often requires the use of a local anaesthetic, typically lidocaine 1%. A neurovascular examination of the digit is essential before reduction is performed because the local anaesthetic may cause complete hypoaesthesia of the finger.

» With simple dislocations, the finger is usually held in extension, and there is some contact between the joint surfaces.

## Acute

» The patient's wrist should be flexed to relax the flexor tendons, and the affected digit should then be hyper-extended.

» The physician should then apply a volar-directed pressure to the dorsum of the affected digit.

» It is paramount that excessive traction not be applied, as a simple dislocation can be converted into a complex metacarpophalangeal dislocation with significant soft tissue entrapment.

» Simple dislocations can be buddy taped, while fracture dislocations require immobilisation in a splint

» Post-reduction x-rays should be obtained to confirm congruence of the joint and to ensure that there are no associated fractures.

» Following reduction, the physician should ensure adequate perfusion to the finger by assessing capillary refill.

» If attempts at reduction fail, consult a specialist hand surgeon.

**plus rehabilitation**

Treatment recommended for ALL patients in selected patient group

» Post-reduction, patients should begin protected range of motion as pain permits. In treating finger dislocations, instituting early motion and providing stability must be balanced.

## patellar dislocation

**1st reduction and immobilisation**

» Patellar dislocation often presents to the emergency department or to the clinic having already spontaneously reduced.

» In a patient presenting with an acute patellar dislocation, a reduction should be performed with the goal being the concentric reduction of the patella into the femoral notch. In cases of intra-articular lesions, orthopaedic consultation is warranted, as open reduction surgery may be required.

» Lateral dislocation is easily managed using local anaesthesia (i.e., intra-articular lidocaine) combined with procedural sedation (e.g., intravenous morphine, midazolam, or etomidate). The choice for sedation depends on the

## Acute

treating physician and must be accompanied by continuous monitoring of the patient with capnography and pulse oximetry, as well as frequent blood pressure measurements.

» Local anaesthesia on its own should be reserved for patients with contraindications to procedural sedation.

» Following adequate analgesia, the patient should be placed either supine or in a seated position.

» The affected knee should be flexed to decrease the tension on the quadriceps muscle.

» The physician should apply a medial-directed force to the lateral aspect of the patella while slowly extending the leg.

» A palpable clunk should confirm reduction of the patella.

» Upon successful reduction, the affected extremity should be placed in a knee immobiliser and patient advised to bear weight on the joint as tolerated.

» Merchant, anteroposterior (AP), and lateral knee plain x-rays should be ordered to ensure that the patella is reduced. The x-rays should be closely examined for evidence of any osteochondral defects that may have been created during the reduction.

» A Cochrane review concluded that large multicentre clinical trials are needed to determine whether a surgical or non-operative approach is preferred for the management of patellar dislocations.<sup>[81]</sup> A systematic review of overlapping meta-analyses found that operative treatment of first-time patellar dislocations results in a lower recurrence rate but no improvement in functional outcome scores compared with non-operative management.<sup>[82]</sup>

» Medial patellofemoral ligament reconstruction for patellofemoral instability was associated with a high rate of success in one systematic review.<sup>[83]</sup> Complications were, however, common (complication rate 26.1%).

## plus

## rehabilitation

Treatment recommended for ALL patients in selected patient group

» In subsequent weeks, active-assisted range of motion exercises and isometric strengthening exercises should be advised.

## Acute

## elbow dislocation

## 1st

## reduction and immobilisation

» Reduction is usually performed using local anaesthesia (i.e., intra-articular lidocaine) combined with procedural sedation (e.g., intravenous morphine, midazolam, or etomidate). The choice for sedation depends on the treating physician and must be accompanied by continuous monitoring of the patient with capnography and pulse oximetry, as well as frequent blood pressure measurements.

» Local anaesthesia on its own should be reserved for patients with contraindications to procedural sedation.

» The patient should be supine on the bed with the physician positioned on the affected side with an assistant close to the head of the bed. In young children, management of radial head subluxation/dislocation (nursemaid's elbow) may be more effective and less painful when performed with the arm in pronation as opposed to supination.<sup>[84]</sup>

» The arm should be initially extended to 30° flexion.

» The overall gross alignment of the elbow is then manipulated so that the olecranon appears centred between the medial and lateral condyle of the humerus.

» The forearm is then slowly flexed to approximately 90° with the physician providing longitudinal traction to the forearm while the assistant provides countertraction to the patient's humerus.

» The arm is then flexed even further with direct downward pressure applied to the olecranon.<sup>[44]</sup>

» If reduction is successful, the physician should feel an audible clunk as the elbow is reduced.

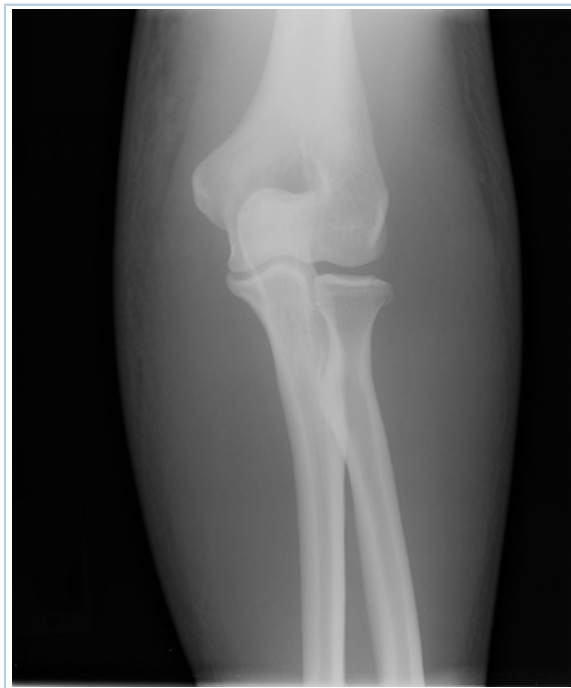» It is important not to flex the arm forcefully if there is significant resistance because the coronoid process is typically perched on the distal humerus. Forceful flexion without adequate traction can cause a fracture of this structure, which will result in future instability.

» Upon reduction, the arm is placed in a posterior splint at 90° flexion with neutral rotation of the forearm.<sup>[44]</sup>



## Acute

» An anteroposterior (AP) and lateral plain film radiograph of the elbow should be obtained to ensure that the joint is concentrically reduced.



*Anteroposterior x-ray view of  
a reduced elbow dislocation  
Personal collection of Dr Paul Novakovich*

» Once the patient is alert, it is important to perform a neurological and vascular examination.

### plus

### rehabilitation

Treatment recommended for ALL patients in selected patient group

» Several studies have shown better outcomes with early range of motion than with immobilisation in patients with simple dislocations.

» Patients should initially be splinted in a posterior splint for comfort with instructions to begin range of motion when pain allows.

» Immobilisation should last no longer than 2 weeks.<sup>[33] [85] [86] [87] [88]</sup>

## hip dislocation

### 1st

### reduction and bracing

» Every effort should be made to obtain reduction of the dislocated hip within 6 hours from injury, via closed or open reduction techniques to maximise functional recovery.<sup>[4]</sup>

## Acute

Urgent reduction of the femoral head into the acetabulum is indicated in almost all cases.

» Unless an associated hip or femoral neck fracture is known to exist, a closed reduction under sedation or anaesthesia can be attempted in the accident and emergency department.[89]

» Allis's method: traction is applied in line with the deformity. The patient is placed supine, with the surgeon standing above the patient on the stretcher. Initially, the surgeon applies in-line traction, while the assistant applies counter-traction, stabilising the pelvis. While increasing the traction force, the surgeon slowly increases the degree of flexion to approximately 70°. Gentle rotational motions of the hip and slight adduction will often help the femoral head clear the lip of the acetabulum. A lateral force to the proximal thigh may assist in reduction. An audible 'clunk' is a sign of a successful closed reduction.[90]

» Stimson's gravity technique: the patient is placed prone on the stretcher, with the affected leg hanging off the side of the stretcher. This brings the extremity into a position of 90° of both hip and knee flexion. In this position, the assistant immobilises the pelvis and the surgeon applies an anteriorly directed force on the proximal calf. Gentle rotation of the limb may assist in reduction.[90]

**plus**

### rehabilitation

Treatment recommended for ALL patients in selected patient group

» Hip immobilisation is difficult. Patients usually do well with assisted ambulation using crutches, and bear weight as tolerated. Crutches should be used until the patient can walk relatively pain-free, and the knee immobiliser should be kept in place until strength improves and symptoms abate. Moderate quadriceps strengthening should begin when the patient is comfortable.

## Primary prevention

Joint dislocations are often the result of an accident and so are not always preventable.

Using correct techniques when exercising or playing sports, and maintaining strength and flexibility of joints, may go some way towards preventing further dislocations. For example, finger dislocations can be prevented by wearing protective gloves when possible and removing jewelry before participating in athletic events.

If loose ligaments or anatomical factors predispose a person to dislocation, the joint can be protected by

elastic bandage wraps, tape wraps, knee and shoulder pads, or special support stockings when exercising or playing sports.

Older patients should be advised to keep away from situations that would make falls more common, such as walking at night, in icy conditions, or on slippery floors.

## Patient discussions

### Shoulder dislocation

- There appears to be no difference between early mobilisation and immobilisation following a shoulder dislocation. However, it is common to place the arm in a sling for comfort.[46] [55] Immobilisation should be for no longer than 3-4 weeks to avoid adhesive capsulitis. All patients should avoid impact activities. Pain permitting, patients should be encouraged to begin range of motion activities.

### Finger dislocation

- For simple stable dislocations that concentrically reduce, patients should be instructed to wear their splints only until the pain subsides. Pain permitting, the patient should buddy tape the affected finger and begin an active range of motion.[57]

### Patellar dislocation

- Patients should be immobilised in a knee immobiliser for 7-10 days with emphasis on early mobilisation as pain permits to limit arthrofibrosis. [New England Musculoskeletal Institute: patellar dislocation] (<https://health.uconn.edu/msi/clinical-services/orthopaedic-surgery/knee-injuries-and-conditions/patellar-dislocation>) Crutches should be used until the patient can walk relatively pain free, and the knee immobiliser should be kept in place until strength improves and symptoms abate. Moderate quadriceps strengthening should begin when the patient is comfortable.[15]

### Elbow dislocation

- Patients who sustain a simple dislocation should be splinted initially but instructed to remove the splint when pain permits.[93]

### Hip dislocation

- Hip immobilisation is difficult. Patients usually do well with assisted ambulation using crutches, and bear weight as tolerated. Crutches should be used until the patient can walk relatively pain-free. Moderate quadriceps strengthening should begin when the patient is comfortable.

# Monitoring

## Monitoring

### Shoulder dislocation

- Patients under 25 years of age should be referred to an orthopaedic surgeon to consider further intervention (i.e., possible arthroscopic or open repair), as this age group is at significant risk of recurrence and has been reported to have a better outcome after primary repair by an orthopaedic surgeon.
- Patients should have routine follow-up with an orthopaedic surgeon and begin physiotherapy. If significant pain and inability to raise the arm remains 3-4 weeks after the reduction, a high suspicion for rotator cuff tear merits an MRI evaluation.

### Finger dislocation

- Any finger dislocation should be followed up by a hand surgeon to ensure appropriate management and to monitor rehabilitation. Patients may or may not need occupational therapy to assist in range of motion and prevent stiffness of the joint.

### Patellar dislocation

- Outpatient orthopaedic referral is appropriate after a dislocation has been reduced to evaluate presence of instability, assess the range of motion, and implement a therapy programme if necessary.

### Elbow dislocation

- Patients with simple dislocations should have routine follow-up with an orthopaedic surgeon to evaluate presence of instability, assess the range of motion, and implement a therapy programme if necessary.

### Hip dislocation

- Patients with hip dislocations should be followed for several years; x-rays should be performed annually to confirm that the femoral head remains reduced and appears healthy, without signs of osteonecrosis.

# Complications

Complications	Timeframe	Likelihood
<b>recurrent instability of shoulder joint</b>	<b>variable</b>	<b>high</b>
<p>The incidence of recurrent instability for those under 25 years of age, treated non-operatively with or without sling immobilisation, ranges from 50% to 95%.<a href="#">[46]</a> <a href="#">[91]</a> <a href="#">[92]</a></p> <p>Inadequate analgesia is a common reason for failure in attempts to reduce a shoulder.</p>		
<b>Hill-Sachs lesion</b>	<b>variable</b>	<b>high</b>
<p>This is a compression fracture on the posterolateral corner of the humeral head, which is caused when the humeral head impinges against the glenoid (scapula) of the shoulder joint.<a href="#">[102]</a></p> <p>Hill-Sachs lesions occur in 47% to 65% of primary shoulder dislocations.<a href="#">[102]</a></p> <p>Large Hill-Sachs lesions are associated with recurrent joint instability.<a href="#">[93]</a></p>		
<b>Bankart's lesions</b>	<b>variable</b>	<b>high</b>
<p>These are avulsions of the glenoid labrum and its attachment to the inferior glenohumeral ligament. This ligament is a primary restraint of the humerus to anterior/inferior translation when the arm is in abduction.<a href="#">[103]</a></p> <p>Avulsion of the capsular restraints to the humeral head contributes to the incidence of instability after a dislocation.</p> <p>Bankart's lesions occur in up to 78% of primary shoulder dislocations.<a href="#">[103]</a></p> <p>Large Bankart's lesions are associated with recurrent instability.<a href="#">[93]</a></p>		
<b>recurrent instability of elbow joint</b>	<b>variable</b>	<b>high</b>
<p>Elbow dislocation with associated fractures, particularly of the radial head and coronoid, often results in significant instability of the joint.<a href="#">[100]</a></p>		
<b>radial head and coronoid fractures</b>	<b>variable</b>	<b>high</b>
<p>Fractures, particularly of the radial head and coronoid, are found in approximately 20% to 50% of elbow dislocations.<a href="#">[33]</a> <a href="#">[100]</a></p> <p>Posterior dislocation of the elbow associated with a fracture of the coronoid process and fracture of the radial head is described as the 'terrible triad'.</p>		
<b>recurrent instability of patellar dislocation</b>	<b>variable</b>	<b>high</b>
<p>Approximately 35% of patients managed conservatively for primary dislocation of the patella experience recurrence.<a href="#">[108]</a> <a href="#">[109]</a></p>		
<b>rotator cuff injury</b>	<b>variable</b>	<b>low</b>
<p>These occur in 11% to 28% of acute shoulder dislocations and are associated with worse prognosis.<a href="#">[80]</a> <a href="#">[103]</a></p>		

Complications	Timeframe	Likelihood
Older patients are more likely to sustain rotator cuff injuries, and early MRI scan may be helpful to rule out this associated pathology. <a href="#">[41]</a> <a href="#">[79]</a> <a href="#">[80]</a>		
<b>neurological injuries following shoulder dislocation</b>	<b>variable</b>	<b>low</b>
<p>The incidence of axillary or brachial plexus injuries associated with acute shoulder dislocation is approximately 4%.</p> <p>However, most are palsies and resolve within 3-6 months.<a href="#">[104]</a></p>		
<b>vascular injuries following shoulder dislocation</b>	<b>variable</b>	<b>low</b>
<p>Brachial and/or axillary artery injuries present with the pathognomonic triad of anterior shoulder dislocation, a diminished or absent pulse, and expanding axillary mass.</p> <p>This typically occurs in older patients due to loss of elasticity of the vessels.</p> <p>Any patient presenting with this triad requires emergent vascular consultation and an angiogram.<a href="#">[105]</a></p>		
<b>greater tuberosity fractures</b>	<b>variable</b>	<b>low</b>
<p>These occur in 7% of shoulder dislocations and, if displaced more than 0.5 cm, they require surgical fixation.<a href="#">[106]</a></p> <p>Early follow-up is important, as non-displaced fractures may displace prior to healing.</p>		
<b>brachial plexus injuries</b>	<b>variable</b>	<b>low</b>
<p>The median, ulnar, or radial nerve can be damaged following elbow dislocation, but most cases are neuropraxias and typically resolve.</p> <p>However, if a deficit appears after reduction of the elbow, consultation with orthopaedics is warranted for emergent exploration of the affected nerve.<a href="#">[15]</a></p>		
<b>vascular injuries following elbow dislocation</b>	<b>variable</b>	<b>low</b>
<p>Brachial artery injury is an extremely rare but devastating complication of elbow dislocation.</p> <p>If a patient presents with an asymmetrical pulse, immediate reduction should be performed, with assessment of pulses post-reduction and referral to a vascular surgeon.</p> <p>If pulses do not return, the patient requires immediate surgical intervention to repair the artery.</p>		
<b>decreased range of motion and stiffness of the elbow</b>	<b>variable</b>	<b>low</b>
<p>Several studies have shown better outcomes with early mobilisation than with immobilisation in patients with simple dislocations of the elbow.</p> <p>Patients should initially be splinted in a posterior splint for comfort, with instructions to begin mobilisation when pain allows. Immobilisation should last no longer than 2 weeks.<a href="#">[33]</a> <a href="#">[85]</a> <a href="#">[86]</a> <a href="#">[87]</a> <a href="#">[88]</a></p>		

Complications	Timeframe	Likelihood
<b>osteochondral lesions of the knee</b>	<b>variable</b>	<b>low</b>
<p>These occur as cartilage covering the end of a bone in a joint (articular cartilage) is torn.</p> <p>One case series found 95% of patients with lateral patellar dislocation showed some degree of articular cartilage injury; cracks with osteochondral fracture were seen in 54% of knees. Other studies have reported rates of between 40% and 76%.<sup>[107]</sup> Damage can occur as a result of reduction in addition to the initial dislocation.</p> <p>Large osteochondral injuries require internal fixation, while small injuries may require arthroscopic debridement.</p> <p>Therefore, orthopaedic consultation is necessary should an osteochondral injury occur.</p>		
<b>ligamentous injury of the knee</b>	<b>variable</b>	<b>low</b>
<p>Other ligamentous structures around the knee can be concomitantly injured.</p>		
<b>finger stiffness</b>	<b>variable</b>	<b>low</b>
<p>Stiffness in finger dislocation is more common than instability and patients can experience residual pain and stiffness for 6-12 months after injury.<sup>[44] [55] [59]</sup></p> <p>In treating finger dislocation, instituting early motion and providing stability must be balanced.</p>		
<b>swan neck deformity of the finger</b>	<b>variable</b>	<b>low</b>
<p>Chronic dorsal proximal interphalangeal dislocation may result in a swan neck deformity of the finger.<sup>[55]</sup></p>		
<b>Boutonniere's deformity</b>	<b>variable</b>	<b>low</b>
<p>Chronic volar proximal interphalangeal dislocation injuries may result in a Boutonniere's deformity.<sup>[55]</sup></p>		
<b>femoral head osteonecrosis</b>	<b>variable</b>	<b>low</b>
<p>May occur after a hip dislocation and is a poor prognostic indicator of clinical outcomes.</p> <p>Studies have documented an osteonecrosis rate of 4.8% when the hip is reduced less than 6 hours after injury; whereas, a rate of 52.9% has been documented in hips reduced more than 6 hours after injury.<sup>[101]</sup></p> <p>When osteonecrosis occurs, it usually appears within 2 years of the injury, but has been observed as long as 5 years after injury. Patients, therefore, should be followed with imaging to monitor for signs of osteonecrosis.</p>		

## Prognosis

Shoulder dislocation



- The incidence of recurrent instability for patients under 25 years of age, treated non-operatively with or without sling immobilisation, ranges from 50% to 95%.[\[46\]](#) [\[91\]](#) [\[92\]](#) In one study, patients with concurrent fractures of the greater tuberosity had an 8% recurrence rate.[\[46\]](#) The presence of Hill-Sachs lesions and bony Bankart's lesions has also been reported to be associated with increased recurrence.[\[93\]](#)
- Immobilisation in external rotation does not appear to be more effective than immobilisation in internal rotation following acute anterior shoulder dislocation.[\[94\]](#) [\[95\]](#)

#### Finger dislocation

- Prognosis is negatively affected by the presence of concurrent fractures, irreducible dislocations, open injuries, and/or ligamentous or tendon injuries.

#### Patellar dislocation

- The risk of recurrence after an acute dislocation, whether treated operatively or non-operatively, has been estimated to range from 25% to 71% of patients. However, even with recurrent dislocations, approximately 75% of patients report good to excellent results with non-operative treatment.[\[96\]](#) [\[97\]](#) [\[98\]](#)
- Medial patellofemoral ligament (MPFL) reconstruction for patellofemoral instability was associated with a high rate of success in one systematic review of the literature.[\[83\]](#) MPFL reconstruction leads to fewer recurrent dislocations than MPFL repair.[\[99\]](#) Both repair and reconstruction successfully returned patients to pre-injury activity levels.[\[99\]](#)

#### Elbow dislocation

- Generally, elbow dislocation without associated fracture has a favourable prognosis when treated by closed reduction, and instability with stiffness is relatively rare.[\[33\]](#) [\[85\]](#) [\[86\]](#) [\[87\]](#) With early range of motion, most patients regain normal function of the affected extremity.[\[88\]](#) Several studies have shown better outcomes with early mobilisation than with immobilisation in patients with simple dislocations.
- Patients with concurrent fractures, particularly of the coronoid process and radial head, require surgical correction to stabilise the elbow. Even after operative intervention, functional outcomes are moderate to poor in more than 50% of patients with complex dislocations.[\[100\]](#)

#### Hip dislocation

- Factors that influence the outcome include the extent of other severe injuries, the time to reduction, the direction of the dislocation, and the overall condition of the patient prior to dislocation. The outcome for individual patients depends largely on the development of late complications such as arthritis, osteonecrosis, and sciatic nerve palsy.[\[52\]](#)
- Due to the high energy nature of native hip dislocations, they are seldom seen without concurrent injury.[\[38\]](#) Associated injuries have a negative prognostic effect on the clinical result. Sciatic nerve injuries are more common after fracture/dislocations when compared with pure dislocations. These injuries are usually partial, and most often affect the peroneal nerve distribution. Resolution after reduction of the dislocation is the rule, and exploration is not required unless nerve function was intact before the reduction and then lost afterwards.[\[101\]](#)
- Isolated anterior dislocations without femoral head fracture or injury have a better prognosis than similar posterior dislocations.[\[52\]](#)
- The most important prognostic factor is generally thought to be the time to reduction, as this directly correlates with subsequent risk of developing osteonecrosis of the femoral head, which is a poor prognostic indicator of clinical outcomes.[\[38\]](#) The rate of osteonecrosis following hip dislocation varies widely. If the hip is reduced within 6 hours, the rate is approximately 2% to 10%.[\[52\]](#) One meta-analysis found that if the hip is reduced after 12 hours, the risk of developing osteonecrosis is 5.6 times greater versus reduction prior to 12 hours. When osteonecrosis occurs, it usually appears within 2 years of the injury, but has been observed as long as 8 years after injury. Patients, therefore, should be followed with imaging to monitor for signs of osteonecrosis.[\[52\]](#)
- Arthritis is the most common complication in patients who have sustained a traumatic hip dislocation, and has been estimated to affect 20%. It probably results from articular cartilage injury during the initial dislocation.[\[52\]](#)
- Femoroacetabular impingement is another potential complication, although incidence is unknown. Patients less than 50 years old should be followed for its development. Although either cam or

pincer type impingement, or a combination, may develop, cam impingement is more common in this population.<sup>[52]</sup>

- Recurrent hip dislocations following an initial simple hip dislocation are rare, with an incidence rate of only 1%.<sup>[52]</sup>

## Diagnostic guidelines

### North America

**ACR appropriateness criteria: osteonecrosis** (<https://www.acr.org/Clinical-Resources/Clinical-Tools-and-Reference/Appropriateness-Criteria>)

**Published by:** American College of Radiology

**Last published:** 2022

**ACR appropriateness criteria: acute trauma to the knee** (<https://www.acr.org/Clinical-Resources/Clinical-Tools-and-Reference/Appropriateness-Criteria>)

**Published by:** American College of Radiology

**Last published:** 2020

**ACR appropriateness criteria: shoulder pain - traumatic** (<https://www.acr.org/Clinical-Resources/Clinical-Tools-and-Reference/Appropriateness-Criteria>)

**Published by:** American College of Radiology

**Last published:** 2018

## Treatment guidelines

### North America

**National Athletic Trainers' Association position statement: immediate management of appendicular joint dislocations** (<https://www.nata.org/news-publications/pressroom/statements/position>)

**Published by:** National Athletic Trainers' Association

**Last published:** 2018

## Online resources

---

1. New England Musculoskeletal Institute: patellar dislocation (<https://health.uconn.edu/msi/clinical-services/orthopaedic-surgery/knee-injuries-and-conditions/patellar-dislocation>) (*external link*)

## Key articles

- Patrick CM, Snowden J, Eckhoff MD, et al. Epidemiology of shoulder dislocations presenting to United States emergency departments: an updated ten-year study. *World J Orthop.* 2023 Sep 18;14(9):690-7. [Full text \(https://www.wjnet.com/2218-5836/full/v14/i9/690.htm\)](https://www.wjnet.com/2218-5836/full/v14/i9/690.htm) [Abstract \(http://www.ncbi.nlm.nih.gov/pubmed/37744717?tool=bestpractice.bmj.com\)](http://www.ncbi.nlm.nih.gov/pubmed/37744717?tool=bestpractice.bmj.com)
- Expert Panel on Musculoskeletal Imaging: Amini B, Beckmann NM, et al. ACR appropriateness criteria: shoulder pain-traumatic. *J Am Coll Radiol.* 2018 May;15(5s):S171-88. [Full text \(https://www.jacr.org/article/S1546-1440\(18\)30338-7/fulltext\)](https://www.jacr.org/article/S1546-1440(18)30338-7/fulltext) [Abstract \(http://www.ncbi.nlm.nih.gov/pubmed/29724420?tool=bestpractice.bmj.com\)](http://www.ncbi.nlm.nih.gov/pubmed/29724420?tool=bestpractice.bmj.com)
- Rozzi SL, Anderson JM, Doberstein ST, et al. National Athletic Trainers' Association position statement: immediate management of appendicular joint dislocations. *J Athl Train.* 2018 Dec;53(12):1117-28. [Full text \(https://www.ncbi.nlm.nih.gov/pmc/articles/PMC6365071\)](https://www.ncbi.nlm.nih.gov/pmc/articles/PMC6365071) [Abstract \(http://www.ncbi.nlm.nih.gov/pubmed/30609383?tool=bestpractice.bmj.com\)](http://www.ncbi.nlm.nih.gov/pubmed/30609383?tool=bestpractice.bmj.com)

## References

1. Brady WJ, Knuth CJ, Pirrallo RG. Bilateral inferior glenohumeral dislocation: luxatio erecta, an unusual presentation of a rare disorder. *J Emerg Med.* 1995 Jan-Feb;13(1):37-42. [Abstract \(http://www.ncbi.nlm.nih.gov/pubmed/7782623?tool=bestpractice.bmj.com\)](http://www.ncbi.nlm.nih.gov/pubmed/7782623?tool=bestpractice.bmj.com)
2. Hildebrand KA, Patterson SD, King GJ. Acute elbow dislocations: simple and complex. *Orthop Clin North Am.* 1999 Jan;30(1):63-79. [Abstract \(http://www.ncbi.nlm.nih.gov/pubmed/9882725?tool=bestpractice.bmj.com\)](http://www.ncbi.nlm.nih.gov/pubmed/9882725?tool=bestpractice.bmj.com)
3. Kani KK, Chew FS. Terrible triad injuries of the elbow. *Emerg Radiol.* 2019 Jun;26(3):341-7. [Abstract \(http://www.ncbi.nlm.nih.gov/pubmed/30690677?tool=bestpractice.bmj.com\)](http://www.ncbi.nlm.nih.gov/pubmed/30690677?tool=bestpractice.bmj.com)
4. Sanders S, Tejwani N, Egol KA. Traumatic hip dislocation - a review. *Bull NYU Hosp Jt Dis.* 2010;68(2):91-6. [Full text \(http://hjdbulletin.org/files/archive/pdfs/281.pdf\)](http://hjdbulletin.org/files/archive/pdfs/281.pdf) [Abstract \(http://www.ncbi.nlm.nih.gov/pubmed/20632983?tool=bestpractice.bmj.com\)](http://www.ncbi.nlm.nih.gov/pubmed/20632983?tool=bestpractice.bmj.com)
5. Patrick CM, Snowden J, Eckhoff MD, et al. Epidemiology of shoulder dislocations presenting to United States emergency departments: an updated ten-year study. *World J Orthop.* 2023 Sep 18;14(9):690-7. [Full text \(https://www.wjnet.com/2218-5836/full/v14/i9/690.htm\)](https://www.wjnet.com/2218-5836/full/v14/i9/690.htm) [Abstract \(http://www.ncbi.nlm.nih.gov/pubmed/37744717?tool=bestpractice.bmj.com\)](http://www.ncbi.nlm.nih.gov/pubmed/37744717?tool=bestpractice.bmj.com)
6. Yeap JS, Lee DJ, Fazir M, et al. The epidemiology of shoulder dislocations in Malaysia. *Med J Malaysia.* 2004 Dec;59 Suppl F:19-23. [Abstract \(http://www.ncbi.nlm.nih.gov/pubmed/15941156?tool=bestpractice.bmj.com\)](http://www.ncbi.nlm.nih.gov/pubmed/15941156?tool=bestpractice.bmj.com)

7. Krøner K, Lind T, Jensen J. The epidemiology of shoulder dislocations. *Arch Orthop Trauma Surg.* 1989;108(5):288-90. [Abstract \(http://www.ncbi.nlm.nih.gov/pubmed/2789505?tool=bestpractice.bmj.com\)](http://www.ncbi.nlm.nih.gov/pubmed/2789505?tool=bestpractice.bmj.com)
8. Shah A, Judge A, Delmestri A, et al. Incidence of shoulder dislocations in the UK, 1995-2015: a population-based cohort study. *BMJ Open.* 2017 Nov 14;7(11):e016112. [Full text \(https://bmjopen.bmj.com/content/7/11/e016112.long\)](https://bmjopen.bmj.com/content/7/11/e016112.long) [Abstract \(http://www.ncbi.nlm.nih.gov/pubmed/29138197?tool=bestpractice.bmj.com\)](http://www.ncbi.nlm.nih.gov/pubmed/29138197?tool=bestpractice.bmj.com)
9. Longo UG, Salvatore G, Locher J, et al. Epidemiology of paediatric shoulder dislocation: a nationwide study in Italy from 2001 to 2014. *Int J Environ Res Public Health.* 2020 Apr 20;17(8):2834. [Full text \(https://www.mdpi.com/1660-4601/17/8/2834\)](https://www.mdpi.com/1660-4601/17/8/2834) [Abstract \(http://www.ncbi.nlm.nih.gov/pubmed/32326066?tool=bestpractice.bmj.com\)](http://www.ncbi.nlm.nih.gov/pubmed/32326066?tool=bestpractice.bmj.com)
10. Golan E, Kang KK, Culbertson M, et al. The epidemiology of finger dislocations presenting for emergency care within the United States. *Hand (N Y).* 2016 Jun;11(2):192-6. [Full text \(https://www.ncbi.nlm.nih.gov/pmc/articles/PMC4920528\)](https://www.ncbi.nlm.nih.gov/pmc/articles/PMC4920528) [Abstract \(http://www.ncbi.nlm.nih.gov/pubmed/27390562?tool=bestpractice.bmj.com\)](http://www.ncbi.nlm.nih.gov/pubmed/27390562?tool=bestpractice.bmj.com)
11. Stefancin JJ, Parker RD. First-time traumatic patellar dislocation: a systematic review. *Clin Orthop Relat Res.* 2007 Feb;455:93-101. [Full text \(https://journals.lww.com/clinorthop/fulltext/2007/02000/first\\_time\\_traumatic\\_patellar\\_dislocation\\_\\_a.16.aspx\)](https://journals.lww.com/clinorthop/fulltext/2007/02000/first_time_traumatic_patellar_dislocation__a.16.aspx) [Abstract \(http://www.ncbi.nlm.nih.gov/pubmed/17279039?tool=bestpractice.bmj.com\)](http://www.ncbi.nlm.nih.gov/pubmed/17279039?tool=bestpractice.bmj.com)
12. Sanders TL, Pareek A, Hewett TE, et al. Incidence of first-time lateral patellar dislocation: a 21-year population-based study. *Sports Health.* 2018 Mar/Apr;10(2):146-51. [Full text \(https://www.ncbi.nlm.nih.gov/pmc/articles/PMC5857724\)](https://www.ncbi.nlm.nih.gov/pmc/articles/PMC5857724) [Abstract \(http://www.ncbi.nlm.nih.gov/pubmed/28795924?tool=bestpractice.bmj.com\)](http://www.ncbi.nlm.nih.gov/pubmed/28795924?tool=bestpractice.bmj.com)
13. Sperner G, Benedetto KP, Glötzer W. Pathology, diagnosis and therapy of patellar dislocation [in German]. *Sportverletz Sportschaden.* 1990 Jun;4(2):69-72. [Abstract \(http://www.ncbi.nlm.nih.gov/pubmed/2382203?tool=bestpractice.bmj.com\)](http://www.ncbi.nlm.nih.gov/pubmed/2382203?tool=bestpractice.bmj.com)
14. Lyons JG, Hudson TL, Krishnamurthy AB. Epidemiology of patellar dislocations in the United States from 2001 to 2020: results of a national emergency department database. *Phys Sportsmed.* 2024 Feb;52(1):26-35. [Abstract \(http://www.ncbi.nlm.nih.gov/pubmed/36476163?tool=bestpractice.bmj.com\)](http://www.ncbi.nlm.nih.gov/pubmed/36476163?tool=bestpractice.bmj.com)
15. Fithian DC, Paxton EW, Stone ML, et al. Epidemiology and natural history of acute patellar dislocation. *Am J Sports Med.* 2004 Jul-Aug;32(5):1114-21. [Abstract \(http://www.ncbi.nlm.nih.gov/pubmed/15262631?tool=bestpractice.bmj.com\)](http://www.ncbi.nlm.nih.gov/pubmed/15262631?tool=bestpractice.bmj.com)
16. Palmu S, Kallio PE, Donell ST, et al. Acute patellar dislocation in children and adolescents: a randomized clinical trial. *J Bone Joint Surg Am.* 2008 Mar;90(3):463-70. [Abstract \(http://www.ncbi.nlm.nih.gov/pubmed/18310694?tool=bestpractice.bmj.com\)](http://www.ncbi.nlm.nih.gov/pubmed/18310694?tool=bestpractice.bmj.com)
17. Morris MS, Ozer K. Elbow dislocations in contact sports. *Hand Clin.* 2017 Feb;33(1):63-72. [Abstract \(http://www.ncbi.nlm.nih.gov/pubmed/27886840?tool=bestpractice.bmj.com\)](http://www.ncbi.nlm.nih.gov/pubmed/27886840?tool=bestpractice.bmj.com)



18. Stoneback JW, Owens BD, Sykes J, et al. Incidence of elbow dislocations in the United States population. *J Bone Joint Surg Am*. 2012 Feb 1;94(3):240-5. [Abstract \(http://www.ncbi.nlm.nih.gov/pubmed/22298056?tool=bestpractice.bmj.com\)](http://www.ncbi.nlm.nih.gov/pubmed/22298056?tool=bestpractice.bmj.com)
19. Habermeyer P, Jung D, Ebert T. Treatment strategy in first traumatic anterior dislocation of the shoulder. Plea for a multi-stage concept of preventive initial management [in German]. *Unfallchirurg*. 1998 May;101(5):328-41. [Abstract \(http://www.ncbi.nlm.nih.gov/pubmed/9629045?tool=bestpractice.bmj.com\)](http://www.ncbi.nlm.nih.gov/pubmed/9629045?tool=bestpractice.bmj.com)
20. Moran J, Cheng R, Schneble CA, et al. Epidemiology of sports-related traumatic hip dislocations reported in United States emergency departments, 2010-2019. *Orthop J Sports Med*. 2022 May;10(5):23259671221088009. [Full text \(https://journals.sagepub.com/doi/full/10.1177/23259671221088009\)](https://journals.sagepub.com/doi/full/10.1177/23259671221088009) [Abstract \(http://www.ncbi.nlm.nih.gov/pubmed/35547614?tool=bestpractice.bmj.com\)](http://www.ncbi.nlm.nih.gov/pubmed/35547614?tool=bestpractice.bmj.com)
21. Robinson CM, Seah M, Akhtar MA. The epidemiology, risk of recurrence, and functional outcome after an acute traumatic posterior dislocation of the shoulder. *J Bone Joint Surg Am*. 2011 Sep 7;93(17):1605-13. [Abstract \(http://www.ncbi.nlm.nih.gov/pubmed/21915575?tool=bestpractice.bmj.com\)](http://www.ncbi.nlm.nih.gov/pubmed/21915575?tool=bestpractice.bmj.com)
22. Grate I Jr. Luxatio erecta: a rarely seen, but often missed shoulder dislocation. *Am J Emerg Med*. 2000 May;18(3):317-21. [Abstract \(http://www.ncbi.nlm.nih.gov/pubmed/10830689?tool=bestpractice.bmj.com\)](http://www.ncbi.nlm.nih.gov/pubmed/10830689?tool=bestpractice.bmj.com)
23. Stiles BM, Drake DB, Gear AJ, et al. Metacarpophalangeal joint dislocation: indications for open surgical reduction. *J Emerg Med*. 1997 Sep-Oct;15(5):669-71. [Abstract \(http://www.ncbi.nlm.nih.gov/pubmed/9348056?tool=bestpractice.bmj.com\)](http://www.ncbi.nlm.nih.gov/pubmed/9348056?tool=bestpractice.bmj.com)
24. Incavo SJ, Mogan JV, Hilfrank BC. Extension splinting of palmar plate avulsion injuries of the proximal interphalangeal joint. *J Hand Surg Am*. 1989 Jul;14(4):659-61. [Abstract \(http://www.ncbi.nlm.nih.gov/pubmed/2754199?tool=bestpractice.bmj.com\)](http://www.ncbi.nlm.nih.gov/pubmed/2754199?tool=bestpractice.bmj.com)
25. Petri M, Ettinger M, Stuebig T, et al. Current concepts for patellar dislocation. *Arch Trauma Res*. 2015 Sep;4(3):e29301. [Full text \(https://www.ncbi.nlm.nih.gov/pmc/articles/PMC4636822\)](https://www.ncbi.nlm.nih.gov/pmc/articles/PMC4636822) [Abstract \(http://www.ncbi.nlm.nih.gov/pubmed/26566512?tool=bestpractice.bmj.com\)](http://www.ncbi.nlm.nih.gov/pubmed/26566512?tool=bestpractice.bmj.com)
26. Parikh SN, Lykissas MG, Gkias I. Predicting risk of recurrent patellar dislocation. *Curr Rev Musculoskelet Med*. 2018 Jun;11(2):253-60. [Full text \(https://www.ncbi.nlm.nih.gov/pmc/articles/PMC5970115\)](https://www.ncbi.nlm.nih.gov/pmc/articles/PMC5970115) [Abstract \(http://www.ncbi.nlm.nih.gov/pubmed/29736871?tool=bestpractice.bmj.com\)](http://www.ncbi.nlm.nih.gov/pubmed/29736871?tool=bestpractice.bmj.com)
27. Buchanan G, Torres L, Czarkowski B, et al. Current concepts in the treatment of gross patellofemoral instability. *Int J Sports Phys Ther*. 2016 Dec;11(6):867-76. [Full text \(https://www.ncbi.nlm.nih.gov/pmc/articles/PMC5095940\)](https://www.ncbi.nlm.nih.gov/pmc/articles/PMC5095940) [Abstract \(http://www.ncbi.nlm.nih.gov/pubmed/27904790?tool=bestpractice.bmj.com\)](http://www.ncbi.nlm.nih.gov/pubmed/27904790?tool=bestpractice.bmj.com)
28. Arendt EA, England K, Agel J, et al. An analysis of knee anatomic imaging factors associated with primary lateral patellar dislocations. *Knee Surg Sports Traumatol Arthrosc*. 2017 Oct;25(10):3099-107. [Abstract \(http://www.ncbi.nlm.nih.gov/pubmed/27145773?tool=bestpractice.bmj.com\)](http://www.ncbi.nlm.nih.gov/pubmed/27145773?tool=bestpractice.bmj.com)

29. Askenberger M, Janarv PM, Finnbogason T, et al. Morphology and anatomic patellar instability risk factors in first-time traumatic lateral patellar dislocations: a prospective magnetic resonance imaging study in skeletally immature children. *Am J Sports Med.* 2017 Jan;45(1):50-8. [Abstract \(http://www.ncbi.nlm.nih.gov/pubmed/27613760?tool=bestpractice.bmj.com\)](http://www.ncbi.nlm.nih.gov/pubmed/27613760?tool=bestpractice.bmj.com)
30. Cameron JC, Saha S. External tibial torsion: an underrecognized cause of recurrent patellar dislocation. *Clin Orthop Relat Res.* 1996 Jul;(328):177-84. [Abstract \(http://www.ncbi.nlm.nih.gov/pubmed/8653953?tool=bestpractice.bmj.com\)](http://www.ncbi.nlm.nih.gov/pubmed/8653953?tool=bestpractice.bmj.com)
31. Beasley LS, Vidal AF. Traumatic patellar dislocation in children and adolescents: treatment update and literature review. *Curr Opin Pediatr.* 2004 Feb;16(1):29-36. [Abstract \(http://www.ncbi.nlm.nih.gov/pubmed/14758111?tool=bestpractice.bmj.com\)](http://www.ncbi.nlm.nih.gov/pubmed/14758111?tool=bestpractice.bmj.com)
32. Buchner M, Baudendistel B, Sabo D, et al. Acute traumatic primary patellar dislocation: long-term results comparing conservative and surgical treatment. *Clin J Sport Med.* 2005 Mar;15(2):62-6. [Abstract \(http://www.ncbi.nlm.nih.gov/pubmed/15782048?tool=bestpractice.bmj.com\)](http://www.ncbi.nlm.nih.gov/pubmed/15782048?tool=bestpractice.bmj.com)
33. Källicke T, Muhr G, Frangen TM. Dislocation of the elbow with fractures of the coronoid process and radial head. *Arch Orthop Trauma Surg.* 2007 Dec;127(10):925-31. [Abstract \(http://www.ncbi.nlm.nih.gov/pubmed/17713772?tool=bestpractice.bmj.com\)](http://www.ncbi.nlm.nih.gov/pubmed/17713772?tool=bestpractice.bmj.com)
34. Rezaie N, Gupta S, Service BC, et al. Elbow dislocation. *Clin Sports Med.* 2020 Jul;39(3):637-55. [Abstract \(http://www.ncbi.nlm.nih.gov/pubmed/32446580?tool=bestpractice.bmj.com\)](http://www.ncbi.nlm.nih.gov/pubmed/32446580?tool=bestpractice.bmj.com)
35. Reichert IL, Ganeshamoorthy S, Aggarwal S, et al. Dislocations of the elbow - an instructional review. *J Clin Orthop Trauma.* 2021 Oct;21:101484. [Full text \(https://www.ncbi.nlm.nih.gov/pmc/articles/PMC8321949\)](https://www.ncbi.nlm.nih.gov/pmc/articles/PMC8321949) [Abstract \(http://www.ncbi.nlm.nih.gov/pubmed/34367909?tool=bestpractice.bmj.com\)](http://www.ncbi.nlm.nih.gov/pubmed/34367909?tool=bestpractice.bmj.com)
36. Kundu ZS, Mittal R, Sangwan SS, et al. Simultaneous asymmetric bilateral hip dislocation with unilateral fracture of femur-peculiar mode of trauma in a case. *Eur J Orthop Surg Traumatol.* 2003 Dec;13(4):255-7.
37. Upadhyay SS, Moulton A, Srikrishnamurthy K. An analysis of the late effects of traumatic posterior dislocation of the hip without fractures. *J Bone Joint Surg Br.* 1983 Mar;65(2):150-2. [Abstract \(http://www.ncbi.nlm.nih.gov/pubmed/6826619?tool=bestpractice.bmj.com\)](http://www.ncbi.nlm.nih.gov/pubmed/6826619?tool=bestpractice.bmj.com)
38. Dawson-Amoah K, Raszewski J, Duplantier N, et al. Dislocation of the hip: a review of types, causes, and treatment. *Ochsner J.* 2018 Fall;18(3):242-52. [Full text \(https://www.ncbi.nlm.nih.gov/pmc/articles/PMC6162140\)](https://www.ncbi.nlm.nih.gov/pmc/articles/PMC6162140) [Abstract \(http://www.ncbi.nlm.nih.gov/pubmed/30275789?tool=bestpractice.bmj.com\)](http://www.ncbi.nlm.nih.gov/pubmed/30275789?tool=bestpractice.bmj.com)
39. Emond M, Le Sage N, Lavoie A, et al. Clinical factors predicting fractures associated with an anterior shoulder dislocation. *Acad Emerg Med.* 2004 Aug;11(8):853-8. [Abstract \(http://www.ncbi.nlm.nih.gov/pubmed/15289192?tool=bestpractice.bmj.com\)](http://www.ncbi.nlm.nih.gov/pubmed/15289192?tool=bestpractice.bmj.com)
40. Horst K, Von Harten R, Weber C, et al. Assessment of coincidence and defect sizes in Bankart and Hill-Sachs lesions after anterior shoulder dislocation: a radiological study. *Br J Radiol.* 2014 Feb;87(1034):20130673. [Full text \(https://academic.oup.com/bjr/article/87/1034/20130673/7445263\)](https://academic.oup.com/bjr/article/87/1034/20130673/7445263) [Abstract \(http://www.ncbi.nlm.nih.gov/pubmed/24452107?tool=bestpractice.bmj.com\)](http://www.ncbi.nlm.nih.gov/pubmed/24452107?tool=bestpractice.bmj.com)

41. Tietjen R. Occult glenohumeral interposition of a torn rotator cuff: a case report. *J Bone Joint Surg Am.* 1982 Mar;64(3):458-9. [Abstract \(http://www.ncbi.nlm.nih.gov/pubmed/7061567?tool=bestpractice.bmj.com\)](http://www.ncbi.nlm.nih.gov/pubmed/7061567?tool=bestpractice.bmj.com)
42. Gombera MM, Sekiya JK. Rotator cuff tear and glenohumeral instability: a systematic review. *Clin Orthop Relat Res.* 2014 Aug;472(8):2448-56. [Full text \(https://journals.lww.com/clinorthop/fulltext/2014/08000/rotator\\_cuff\\_tear\\_and\\_glenohumeral\\_instability\\_\\_a.23.aspx\)](https://journals.lww.com/clinorthop/fulltext/2014/08000/rotator_cuff_tear_and_glenohumeral_instability__a.23.aspx) [Abstract \(http://www.ncbi.nlm.nih.gov/pubmed/24043432?tool=bestpractice.bmj.com\)](http://www.ncbi.nlm.nih.gov/pubmed/24043432?tool=bestpractice.bmj.com)
43. Simank HG, Dauer G, Schneider S, et al. Incidence of rotator cuff tears in shoulder dislocations and results of therapy in older patients. *Arch Orthop Trauma Surg.* 2006 May;126(4):235-40. [Abstract \(http://www.ncbi.nlm.nih.gov/pubmed/16151824?tool=bestpractice.bmj.com\)](http://www.ncbi.nlm.nih.gov/pubmed/16151824?tool=bestpractice.bmj.com)
44. Hovelius L, Olofsson A, Sandström B, et al. Nonoperative treatment of primary anterior shoulder dislocation in patients 40 years of age and younger: a prospective 25-year follow-up. *J Bone Joint Surg Am.* 2008 May;90(5):945-52. [Abstract \(http://www.ncbi.nlm.nih.gov/pubmed/18451384?tool=bestpractice.bmj.com\)](http://www.ncbi.nlm.nih.gov/pubmed/18451384?tool=bestpractice.bmj.com)
45. Vicar AJ. Proximal interphalangeal joint dislocations without fractures. *Hand Clin.* 1988 Feb;4(1):5-13. [Abstract \(http://www.ncbi.nlm.nih.gov/pubmed/3277980?tool=bestpractice.bmj.com\)](http://www.ncbi.nlm.nih.gov/pubmed/3277980?tool=bestpractice.bmj.com)
46. Wen DY. Current concepts in the treatment of anterior shoulder dislocations. *Am J Emerg Med.* 1999 Jul;17(4):401-7. [Abstract \(http://www.ncbi.nlm.nih.gov/pubmed/10452444?tool=bestpractice.bmj.com\)](http://www.ncbi.nlm.nih.gov/pubmed/10452444?tool=bestpractice.bmj.com)
47. Robinson PM, Griffiths E, Watts AC. Simple elbow dislocation. *Shoulder Elbow.* 2017 Jul;9(3):195-204. [Full text \(https://www.ncbi.nlm.nih.gov/pmc/articles/PMC5444606\)](https://www.ncbi.nlm.nih.gov/pmc/articles/PMC5444606) [Abstract \(http://www.ncbi.nlm.nih.gov/pubmed/28588660?tool=bestpractice.bmj.com\)](http://www.ncbi.nlm.nih.gov/pubmed/28588660?tool=bestpractice.bmj.com)
48. O'Driscoll SW, Morrey BF, Korinek S, et al. Elbow subluxation and dislocation. A spectrum of instability. *Clin Orthop Relat Res.* 1992 Jul;(280):186-97. [Abstract \(http://www.ncbi.nlm.nih.gov/pubmed/1611741?tool=bestpractice.bmj.com\)](http://www.ncbi.nlm.nih.gov/pubmed/1611741?tool=bestpractice.bmj.com)
49. Schreiber JJ, Warren RF, Hotchkiss RN, et al. An online video investigation into the mechanism of elbow dislocation. *J Hand Surg Am.* 2013 Mar;38(3):488-94. [Abstract \(http://www.ncbi.nlm.nih.gov/pubmed/23391358?tool=bestpractice.bmj.com\)](http://www.ncbi.nlm.nih.gov/pubmed/23391358?tool=bestpractice.bmj.com)
50. Schreiber JJ, Potter HG, Warren RF, et al. Magnetic resonance imaging findings in acute elbow dislocation: insight into mechanism. *J Hand Surg Am.* 2014 Feb;39(2):199-205. [Abstract \(http://www.ncbi.nlm.nih.gov/pubmed/24480682?tool=bestpractice.bmj.com\)](http://www.ncbi.nlm.nih.gov/pubmed/24480682?tool=bestpractice.bmj.com)
51. Rhyou IH, Kim YS. New mechanism of the posterior elbow dislocation. *Knee Surg Sports Traumatol Arthrosc.* 2012 Dec;20(12):2535-41. [Abstract \(http://www.ncbi.nlm.nih.gov/pubmed/22228377?tool=bestpractice.bmj.com\)](http://www.ncbi.nlm.nih.gov/pubmed/22228377?tool=bestpractice.bmj.com)
52. Clegg TE, Roberts CS, Greene JW, et al. Hip dislocations--epidemiology, treatment, and outcomes. *Injury.* 2010 Apr;41(4):329-34. [Abstract \(http://www.ncbi.nlm.nih.gov/pubmed/19796765?tool=bestpractice.bmj.com\)](http://www.ncbi.nlm.nih.gov/pubmed/19796765?tool=bestpractice.bmj.com)

53. Zarei R, Tavassoli M, Baroutkoub M, et al. Concurrent ipsilateral fractures of acetabular posterior wall and femoral shaft associated with posterior hip dislocation: a case report and literature review of a rare injury. *Int J Surg Case Rep.* 2023 Dec;113:109035. [Full text \(https://www.sciencedirect.com/science/article/pii/S2210261223011641\)](https://www.sciencedirect.com/science/article/pii/S2210261223011641) [Abstract \(http://www.ncbi.nlm.nih.gov/pubmed/37976719?tool=bestpractice.bmj.com\)](http://www.ncbi.nlm.nih.gov/pubmed/37976719?tool=bestpractice.bmj.com)
54. Verweij LP, Baden DN, van der Zande JM, et al. Assessment and management of shoulder dislocation. *BMJ.* 2020 Dec 7;371:m4485. [Abstract \(http://www.ncbi.nlm.nih.gov/pubmed/33288499?tool=bestpractice.bmj.com\)](http://www.ncbi.nlm.nih.gov/pubmed/33288499?tool=bestpractice.bmj.com)
55. Ugras AA, Mahirogullari M, Kural C, et al. Reduction of anterior shoulder dislocations by Spaso technique: clinical results. *J Emerg Med.* 2008 May;34(4):383-7. [Abstract \(http://www.ncbi.nlm.nih.gov/pubmed/18226873?tool=bestpractice.bmj.com\)](http://www.ncbi.nlm.nih.gov/pubmed/18226873?tool=bestpractice.bmj.com)
56. Elias DA, White LM, Fithian DC. Acute lateral patellar dislocation at MR imaging: injury patterns of medial patellar soft-tissue restraints and osteochondral injuries of the inferomedial patella. *Radiology.* 2002 Dec;225(3):736-43. [Abstract \(http://www.ncbi.nlm.nih.gov/pubmed/12461254?tool=bestpractice.bmj.com\)](http://www.ncbi.nlm.nih.gov/pubmed/12461254?tool=bestpractice.bmj.com)
57. Packer GJ, Shaheen MA. Patterns of hand fractures and dislocations in a district general hospital. *J Hand Surg Br.* 1993 Aug;18(4):511-4. [Abstract \(http://www.ncbi.nlm.nih.gov/pubmed/8409670?tool=bestpractice.bmj.com\)](http://www.ncbi.nlm.nih.gov/pubmed/8409670?tool=bestpractice.bmj.com)
58. Zemel NP. Metacarpophalangeal joint injuries in fingers. *Hand Clin.* 1992 Nov;8(4):745-54. [Abstract \(http://www.ncbi.nlm.nih.gov/pubmed/1460071?tool=bestpractice.bmj.com\)](http://www.ncbi.nlm.nih.gov/pubmed/1460071?tool=bestpractice.bmj.com)
59. Expert Panel on Musculoskeletal Imaging: Amini B, Beckmann NM, et al. ACR appropriateness criteria: shoulder pain-traumatic. *J Am Coll Radiol.* 2018 May;15(5s):S171-88. [Full text \(https://www.jacr.org/article/S1546-1440\(18\)30338-7/fulltext\)](https://www.jacr.org/article/S1546-1440(18)30338-7/fulltext) [Abstract \(http://www.ncbi.nlm.nih.gov/pubmed/29724420?tool=bestpractice.bmj.com\)](http://www.ncbi.nlm.nih.gov/pubmed/29724420?tool=bestpractice.bmj.com)
60. Silfverskiöld JP, Straehley DJ, Jones WW. Roentgenographic evaluation of suspected shoulder dislocation: a prospective study comparing the axillary view and the scapular 'Y' view. *Orthopedics.* 1990 Jan;13(1):63-9. [Abstract \(http://www.ncbi.nlm.nih.gov/pubmed/2300518?tool=bestpractice.bmj.com\)](http://www.ncbi.nlm.nih.gov/pubmed/2300518?tool=bestpractice.bmj.com)
61. Rowe CR, Zarins B. Chronic unreduced dislocations of the shoulder. *J Bone Joint Surg Am.* 1982 Apr;64(4):494-505. [Abstract \(http://www.ncbi.nlm.nih.gov/pubmed/7068692?tool=bestpractice.bmj.com\)](http://www.ncbi.nlm.nih.gov/pubmed/7068692?tool=bestpractice.bmj.com)
62. Hawkins RJ, Neer CS 2nd, Pianta RM, et al. Locked posterior dislocation of the shoulder. *J Bone Joint Surg Am.* 1987 Jan;69(1):9-18. [Abstract \(http://www.ncbi.nlm.nih.gov/pubmed/3805075?tool=bestpractice.bmj.com\)](http://www.ncbi.nlm.nih.gov/pubmed/3805075?tool=bestpractice.bmj.com)
63. Gottlieb M, Patel D, Marks A, et al. Ultrasound for the diagnosis of shoulder dislocation and reduction: a systematic review and meta-analysis. *Acad Emerg Med.* 2022 Aug;29(8):999-1007. [Full text \(https://onlinelibrary.wiley.com/doi/10.1111/acem.14454\)](https://onlinelibrary.wiley.com/doi/10.1111/acem.14454) [Abstract \(http://www.ncbi.nlm.nih.gov/pubmed/35094451?tool=bestpractice.bmj.com\)](http://www.ncbi.nlm.nih.gov/pubmed/35094451?tool=bestpractice.bmj.com)

64. Moharari RS, Khademhosseini P, Espandar R, et al. Intra-articular lidocaine versus intravenous meperidine/diazepam in anterior shoulder dislocation: a randomised clinical trial. *Emerg Med J*. 2008 May;25(5):262-4. [Abstract \(http://www.ncbi.nlm.nih.gov/pubmed/18434457?tool=bestpractice.bmj.com\)](http://www.ncbi.nlm.nih.gov/pubmed/18434457?tool=bestpractice.bmj.com)
65. Kosnik J, Shamsa F, Raphael E, et al. Anesthetic methods for reduction of acute shoulder dislocations: a prospective randomized study comparing intraarticular lidocaine with intravenous analgesia and sedation. *Am J Emerg Med*. 1999 Oct;17(6):566-70. [Abstract \(http://www.ncbi.nlm.nih.gov/pubmed/10530535?tool=bestpractice.bmj.com\)](http://www.ncbi.nlm.nih.gov/pubmed/10530535?tool=bestpractice.bmj.com)
66. Miller SL, Cleeman E, Auerbach J, et al. Comparison of intra-articular lidocaine and intravenous sedation for reduction of shoulder dislocations: a randomized, prospective study. *J Bone Joint Surg Am*. 2002 Dec;84-A(12):2135-9. [Abstract \(http://www.ncbi.nlm.nih.gov/pubmed/12473699?tool=bestpractice.bmj.com\)](http://www.ncbi.nlm.nih.gov/pubmed/12473699?tool=bestpractice.bmj.com)
67. O'Connor DR, Schwarze D, Fragomen AT, et al. Painless reduction of acute anterior shoulder dislocations without anesthesia. *Orthopedics*. 2006 Jun;29(6):528-32. [Abstract \(http://www.ncbi.nlm.nih.gov/pubmed/16786945?tool=bestpractice.bmj.com\)](http://www.ncbi.nlm.nih.gov/pubmed/16786945?tool=bestpractice.bmj.com)
68. Kothari RU, Dronen SC. Prospective evaluation of the scapular manipulation technique in reducing anterior shoulder dislocations. *Ann Emerg Med*. 1992 Nov;21(11):1349-52. [Abstract \(http://www.ncbi.nlm.nih.gov/pubmed/1416331?tool=bestpractice.bmj.com\)](http://www.ncbi.nlm.nih.gov/pubmed/1416331?tool=bestpractice.bmj.com)
69. Saragaglia D, Picard F, Le Bredonchel T, et al. Acute anterior instability of the shoulder: short- and mid-term outcome after conservative treatment [in French]. *Rev Chir Orthop Reparatrice Appar Mot*. 2001 May;87(3):215-20. [Abstract \(http://www.ncbi.nlm.nih.gov/pubmed/11351220?tool=bestpractice.bmj.com\)](http://www.ncbi.nlm.nih.gov/pubmed/11351220?tool=bestpractice.bmj.com)
70. Sayegh FE, Kenanidis EI, Papavasiliou KA, et al. Reduction of acute anterior dislocations: a prospective randomized study comparing a new technique with the Hippocratic and Kocher methods. *J Bone Joint Surg Am*. 2009 Dec;91(12):2775-82. [Abstract \(http://www.ncbi.nlm.nih.gov/pubmed/19952238?tool=bestpractice.bmj.com\)](http://www.ncbi.nlm.nih.gov/pubmed/19952238?tool=bestpractice.bmj.com)
71. Rozzi SL, Anderson JM, Doberstein ST, et al. National Athletic Trainers' Association position statement: immediate management of appendicular joint dislocations. *J Athl Train*. 2018 Dec;53(12):1117-28. [Full text \(https://www.ncbi.nlm.nih.gov/pmc/articles/PMC6365071\)](https://www.ncbi.nlm.nih.gov/pmc/articles/PMC6365071) [Abstract \(http://www.ncbi.nlm.nih.gov/pubmed/30609383?tool=bestpractice.bmj.com\)](http://www.ncbi.nlm.nih.gov/pubmed/30609383?tool=bestpractice.bmj.com)
72. Yapp LZ, Nicholson JA, Robinson CM. Primary arthroscopic stabilization for a first-time anterior dislocation of the shoulder: long-term follow-up of a randomized, double-blinded trial. *J Bone Joint Surg Am*. 2020 Mar 18;102(6):460-7. [Abstract \(http://www.ncbi.nlm.nih.gov/pubmed/31895236?tool=bestpractice.bmj.com\)](http://www.ncbi.nlm.nih.gov/pubmed/31895236?tool=bestpractice.bmj.com)
73. Adam M, Attia AK, Alhammoud A, et al. Arthroscopic Bankart repair for the acute anterior shoulder dislocation: systematic review and meta-analysis. *Int Orthop*. 2018 Oct;42(10):2413-22. [Abstract \(http://www.ncbi.nlm.nih.gov/pubmed/29982868?tool=bestpractice.bmj.com\)](http://www.ncbi.nlm.nih.gov/pubmed/29982868?tool=bestpractice.bmj.com)
74. Belk JW, Wharton BR, Houck DA, et al. Shoulder stabilization versus immobilization for first-time anterior shoulder dislocation: a systematic review and meta-analysis of level 1 randomized



- controlled trials. *Am J Sports Med.* 2023 May;51(6):1634-43. [Abstract \(http://www.ncbi.nlm.nih.gov/pubmed/35148222?tool=bestpractice.bmj.com\)](http://www.ncbi.nlm.nih.gov/pubmed/35148222?tool=bestpractice.bmj.com)
75. Alkhelaifi K, Alzobi OZ, Mahmoud SA, et al. Recurrent instability after the Latarjet procedure. *J Am Acad Orthop Surg Glob Res Rev.* 2023 Nov 27;7(12):e23.00205. [Full text \(https://journals.lww.com/jaaosglobal/fulltext/2023/12000/recurrent\\_instability\\_after\\_the\\_latarjet\\_procedure.1.aspx\)](https://journals.lww.com/jaaosglobal/fulltext/2023/12000/recurrent_instability_after_the_latarjet_procedure.1.aspx) [Abstract \(http://www.ncbi.nlm.nih.gov/pubmed/38011051?tool=bestpractice.bmj.com\)](http://www.ncbi.nlm.nih.gov/pubmed/38011051?tool=bestpractice.bmj.com)
76. Hasebroock AW, Brinkman J, Foster L, et al. Management of primary anterior shoulder dislocations: a narrative review. *Sports Med Open.* 2019 Jul 11;5(1):31. [Full text \(https://sportsmedicine-open.springeropen.com/articles/10.1186/s40798-019-0203-2\)](https://sportsmedicine-open.springeropen.com/articles/10.1186/s40798-019-0203-2) [Abstract \(http://www.ncbi.nlm.nih.gov/pubmed/31297678?tool=bestpractice.bmj.com\)](http://www.ncbi.nlm.nih.gov/pubmed/31297678?tool=bestpractice.bmj.com)
77. An VV, Sivakumar BS, Phan K, et al. A systematic review and meta-analysis of clinical and patient-reported outcomes following two procedures for recurrent traumatic anterior instability of the shoulder: Latarjet procedure vs. Bankart repair. *J Shoulder Elbow Surg.* 2016 May;25(5):853-63. [Abstract \(http://www.ncbi.nlm.nih.gov/pubmed/26809355?tool=bestpractice.bmj.com\)](http://www.ncbi.nlm.nih.gov/pubmed/26809355?tool=bestpractice.bmj.com)
78. Hurley ET, Lim Fat D, Farrington SK, et al. Open versus arthroscopic Latarjet procedure for anterior shoulder instability: a systematic review and meta-analysis. *Am J Sports Med.* 2019 Apr;47(5):1248-53. [Abstract \(http://www.ncbi.nlm.nih.gov/pubmed/29558168?tool=bestpractice.bmj.com\)](http://www.ncbi.nlm.nih.gov/pubmed/29558168?tool=bestpractice.bmj.com)
79. Antonio GE, Griffith JF, Yu AB, et al. First-time shoulder dislocation: High prevalence of labral injury and age-related differences revealed by MR arthrography. *J Magn Reson Imaging.* 2007 Oct;26(4):983-91. [Abstract \(http://www.ncbi.nlm.nih.gov/pubmed/17896393?tool=bestpractice.bmj.com\)](http://www.ncbi.nlm.nih.gov/pubmed/17896393?tool=bestpractice.bmj.com)
80. Tijmes J, Loyd HM, Tullos HS. Arthrography in acute shoulder dislocations. *South Med J.* 1979 May;72(5):564-7. [Abstract \(http://www.ncbi.nlm.nih.gov/pubmed/441768?tool=bestpractice.bmj.com\)](http://www.ncbi.nlm.nih.gov/pubmed/441768?tool=bestpractice.bmj.com)
81. Smith TO, Gaukroger A, Metcalfe A, et al. Surgical versus non-surgical interventions for treating patellar dislocation. *Cochrane Database Syst Rev.* 2023 Jan 24;(1):CD008106. [Full text \(https://www.cochranelibrary.com/cdsr/doi/10.1002/14651858.CD008106.pub4/full\)](https://www.cochranelibrary.com/cdsr/doi/10.1002/14651858.CD008106.pub4/full) [Abstract \(http://www.ncbi.nlm.nih.gov/pubmed/36692346?tool=bestpractice.bmj.com\)](http://www.ncbi.nlm.nih.gov/pubmed/36692346?tool=bestpractice.bmj.com)
82. Erickson BJ, Mascarenhas R, Sayegh ET, et al. Does operative treatment of first-time patellar dislocations lead to increased patellofemoral stability? A systematic review of overlapping meta-analyses. *Arthroscopy.* 2015 Jun;31(6):1207-15. [Abstract \(http://www.ncbi.nlm.nih.gov/pubmed/25636989?tool=bestpractice.bmj.com\)](http://www.ncbi.nlm.nih.gov/pubmed/25636989?tool=bestpractice.bmj.com)
83. Shah JN, Howard JS, Flanigan DC, et al. A systematic review of complications and failures associated with medial patellofemoral ligament reconstruction for recurrent patellar dislocation. *Am J Sports Med.* 2012 Aug;40(8):1916-23. [Full text \(https://www.ncbi.nlm.nih.gov/pmc/articles/PMC3615712\)](https://www.ncbi.nlm.nih.gov/pmc/articles/PMC3615712) [Abstract \(http://www.ncbi.nlm.nih.gov/pubmed/22679297?tool=bestpractice.bmj.com\)](http://www.ncbi.nlm.nih.gov/pubmed/22679297?tool=bestpractice.bmj.com)
84. Krul M, van der Wouden JC, van Suijlekom-Smit LW, et al. Manipulative interventions for reducing pulled elbow in young children. *Cochrane Database Syst Rev.* 2017 Jul 28;(7):CD007759. [Full](#)



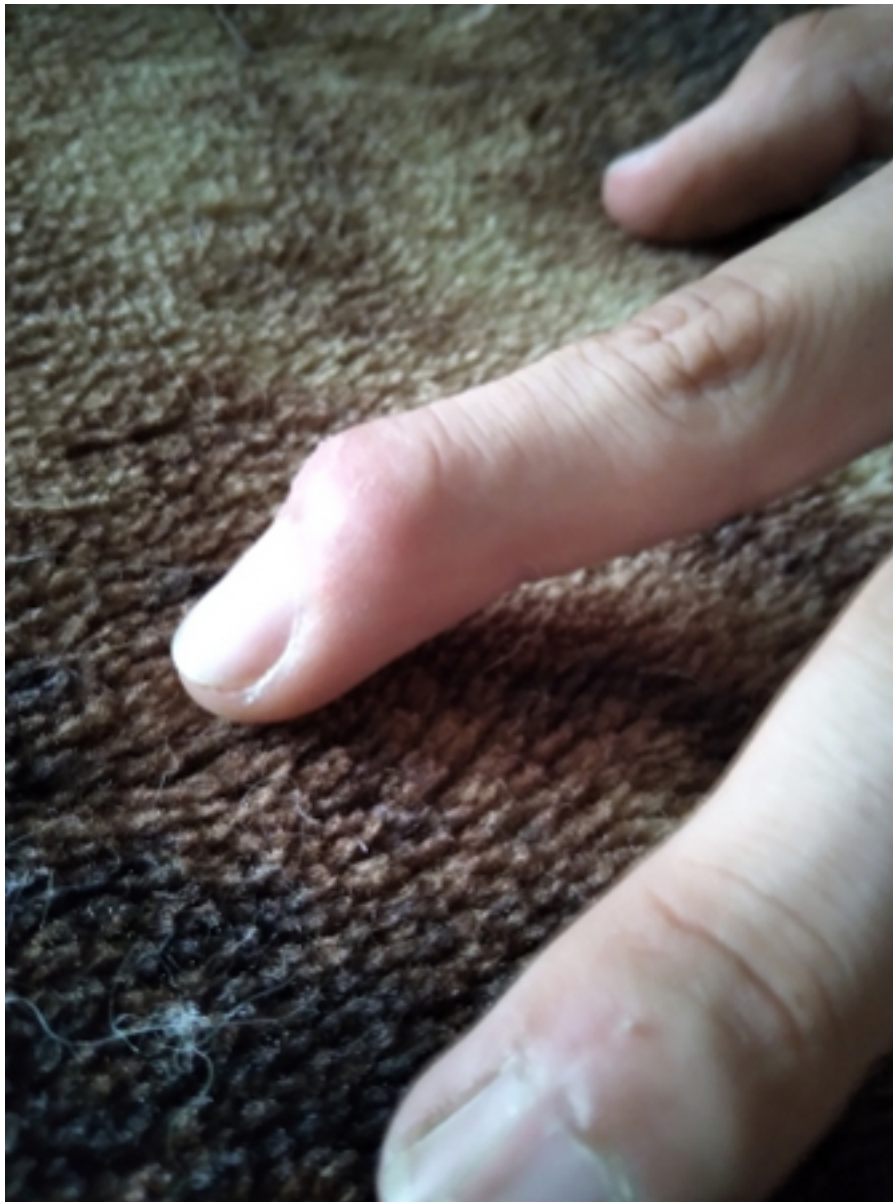text (<http://onlinelibrary.wiley.com/doi/10.1002/14651858.CD007759.pub4/full>) Abstract (<http://www.ncbi.nlm.nih.gov/pubmed/28753234?tool=bestpractice.bmj.com>)

85. Cohen MS, Hastings H 2nd. Acute elbow dislocation: evaluation and management. *J Am Acad Orthop Surg*. 1998 Jan-Feb;6(1):15-23. Abstract (<http://www.ncbi.nlm.nih.gov/pubmed/9692937?tool=bestpractice.bmj.com>)
86. Ross G, McDevitt ER, Chronister R, et al. Treatment of simple elbow dislocation using an immediate motion protocol. *Am J Sports Med*. 1999 May-Jun;27(3):308-11. Abstract (<http://www.ncbi.nlm.nih.gov/pubmed/10352765?tool=bestpractice.bmj.com>)
87. Arendt EA, Fithian DC, Cohen E. Current concepts of lateral patella dislocation. *Clin Sports Med*. 2002 Jul;21(3):499-519. Abstract (<http://www.ncbi.nlm.nih.gov/pubmed/12365240?tool=bestpractice.bmj.com>)
88. Sillanpää P, Mattila VM, Iivonen T, et al. Incidence and risk factors of acute traumatic primary patellar dislocation. *Med Sci Sports Exerc*. 2008 Apr;40(4):606-11. Abstract (<http://www.ncbi.nlm.nih.gov/pubmed/18317388?tool=bestpractice.bmj.com>)
89. Stewart MJ, Milford LW. Fracture-dislocation of the hip; an end-result study. *J Bone Joint Surg Am*. 1954 Apr;36(A:2):315-42. Abstract (<http://www.ncbi.nlm.nih.gov/pubmed/13152141?tool=bestpractice.bmj.com>)
90. DeLee JC. Fractures and dislocations of the hip. In: Rockwood CA Jr, Green DP, Bucholz R, eds. *Fractures in adults*. Vol 2. 4th ed. Philadelphia, PA: Lippincott-Raven; 1996:1756-1803.
91. Hovelius L. Anterior dislocation of the shoulder in teen-agers and young adults: five-year prognosis. *J Bone Joint Surg Am*. 1987 Mar;69(3):393-9. Abstract (<http://www.ncbi.nlm.nih.gov/pubmed/2434509?tool=bestpractice.bmj.com>)
92. Kelley SP, Hinsche AF, Hossain JF. Axillary artery transection following anterior shoulder dislocation: classical presentation and current concepts. *Injury*. 2004 Nov;35(11):1128-32. Abstract (<http://www.ncbi.nlm.nih.gov/pubmed/15488503?tool=bestpractice.bmj.com>)
93. Mehlhoff TL, Noble PC, Bennett JB, et al. Simple dislocation of the elbow in the adult. Results after closed treatment. *J Bone Joint Surg Am*. 1988 Feb;70(2):244-9. Abstract (<http://www.ncbi.nlm.nih.gov/pubmed/3343270?tool=bestpractice.bmj.com>)
94. Braun C, McRobert CJ. Conservative management following closed reduction of traumatic anterior dislocation of the shoulder. *Cochrane Database Syst Rev*. 2019 May 10;5:CD004962. Full text (<https://www.cochranelibrary.com/cdsr/doi/10.1002/14651858.CD004962.pub4/full>) Abstract (<http://www.ncbi.nlm.nih.gov/pubmed/31074847?tool=bestpractice.bmj.com>)
95. Whelan DB, Kletke SN, Schemitsch G, et al. Immobilization in external rotation versus internal rotation after primary anterior shoulder dislocation: a meta-analysis of randomized controlled trials. *Am J Sports Med*. 2016 Feb;44(2):521-32. Abstract (<http://www.ncbi.nlm.nih.gov/pubmed/26116355?tool=bestpractice.bmj.com>)

96. Freiberg A, Pollard BA, Macdonald MR, et al. Management of proximal interphalangeal joint injuries. *Hand Clin.* 2006 Aug;22(3):235-42. [Abstract \(http://www.ncbi.nlm.nih.gov/pubmed/16843790?tool=bestpractice.bmj.com\)](http://www.ncbi.nlm.nih.gov/pubmed/16843790?tool=bestpractice.bmj.com)
97. Failla JM. Irreducible thumb interphalangeal joint dislocation due to a sesamoid and palmar plate: a case report. *J Hand Surg Am.* 1995 May;20(3):490-1. [Abstract \(http://www.ncbi.nlm.nih.gov/pubmed/7642934?tool=bestpractice.bmj.com\)](http://www.ncbi.nlm.nih.gov/pubmed/7642934?tool=bestpractice.bmj.com)
98. Sabapathy SR, Bose VC, Rex C. Irreducible dislocation of the interphalangeal joint of the thumb due to sesamoid bone interposition: a case report. *J Hand Surg Am.* 1995 May;20(3):487-9. [Abstract \(http://www.ncbi.nlm.nih.gov/pubmed/7642933?tool=bestpractice.bmj.com\)](http://www.ncbi.nlm.nih.gov/pubmed/7642933?tool=bestpractice.bmj.com)
99. Matic GT, Magnussen RA, Kolovich GP, et al. Return to activity after medial patellofemoral ligament repair or reconstruction. *Arthroscopy.* 2014 Aug;30(8):1018-25. [Abstract \(http://www.ncbi.nlm.nih.gov/pubmed/24768468?tool=bestpractice.bmj.com\)](http://www.ncbi.nlm.nih.gov/pubmed/24768468?tool=bestpractice.bmj.com)
100. Atkin DM, Fithian DC, Marangi KS, et al. Characteristics of patients with primary acute lateral patellar dislocation and their recovery within the first 6 months of injury. *Am J Sports Med.* 2000 Jul-Aug;28(4):472-9. [Abstract \(http://www.ncbi.nlm.nih.gov/pubmed/10921637?tool=bestpractice.bmj.com\)](http://www.ncbi.nlm.nih.gov/pubmed/10921637?tool=bestpractice.bmj.com)
101. Hougaard K, Thomsen PB. Traumatic posterior dislocation of the hip - prognostic factors influencing the incidence of avascular necrosis of the femoral head. *Arch Orthop Trauma Surg.* 1986;106(1):32-5. [Abstract \(http://www.ncbi.nlm.nih.gov/pubmed/3566493?tool=bestpractice.bmj.com\)](http://www.ncbi.nlm.nih.gov/pubmed/3566493?tool=bestpractice.bmj.com)
102. Calandra JJ, Baker CL, Uribe J. The incidence of Hill-Sachs lesions in initial anterior shoulder dislocations. *Arthroscopy.* 1989;5(4):254-7. [Abstract \(http://www.ncbi.nlm.nih.gov/pubmed/2590322?tool=bestpractice.bmj.com\)](http://www.ncbi.nlm.nih.gov/pubmed/2590322?tool=bestpractice.bmj.com)
103. Turkel SJ, Panio MW, Marshall JL, et al. Stabilizing mechanisms preventing anterior dislocation of the glenohumeral joint. *J Bone Joint Surg Am.* 1981 Oct;63(8):1208-17. [Abstract \(http://www.ncbi.nlm.nih.gov/pubmed/7287791?tool=bestpractice.bmj.com\)](http://www.ncbi.nlm.nih.gov/pubmed/7287791?tool=bestpractice.bmj.com)
104. McLaughlin HL, MacLellan DI. Recurrent anterior dislocation of the shoulder: II. a comparative study. *J Trauma.* 1967 Mar;7(2):191-201. [Abstract \(http://www.ncbi.nlm.nih.gov/pubmed/6018942?tool=bestpractice.bmj.com\)](http://www.ncbi.nlm.nih.gov/pubmed/6018942?tool=bestpractice.bmj.com)
105. Dimakopoulos P, Panagopoulos A, Kasimatis G, et al. Anterior traumatic shoulder dislocation associated with displaced greater tuberosity fracture: the necessity of operative treatment. *J Orthop Trauma.* 2007 Feb;21(2):104-12. [Abstract \(http://www.ncbi.nlm.nih.gov/pubmed/17304065?tool=bestpractice.bmj.com\)](http://www.ncbi.nlm.nih.gov/pubmed/17304065?tool=bestpractice.bmj.com)
106. Hobgood ER, Khan SO, Field LD. Acute dislocations of the adult elbow. *Hand Clin.* 2008 Feb;24(1):1-7. [Abstract \(http://www.ncbi.nlm.nih.gov/pubmed/18299016?tool=bestpractice.bmj.com\)](http://www.ncbi.nlm.nih.gov/pubmed/18299016?tool=bestpractice.bmj.com)
107. Nomura E, Inoue M, Kurimura M. Chondral and osteochondral injuries associated with acute patellar dislocation. *Arthroscopy.* 2003 Sep;19(7):717-21. [Abstract \(http://www.ncbi.nlm.nih.gov/pubmed/12966379?tool=bestpractice.bmj.com\)](http://www.ncbi.nlm.nih.gov/pubmed/12966379?tool=bestpractice.bmj.com)

108. Jaquith BP, Parikh SN. Predictors of recurrent patellar instability in children and adolescents after first-time dislocation. *J Pediatr Orthop*. 2017 Oct/Nov;37(7):484-90. [Abstract \(http://www.ncbi.nlm.nih.gov/pubmed/26491910?tool=bestpractice.bmj.com\)](http://www.ncbi.nlm.nih.gov/pubmed/26491910?tool=bestpractice.bmj.com)
109. Longo UG, Ciuffreda M, Locher J, et al. Treatment of primary acute patellar dislocation: systematic review and quantitative synthesis of the literature. *Clin J Sport Med*. 2017 Nov;27(6):511-23. [Full text \(https://journals.lww.com/cjsportsmed/Fulltext/2017/11000/Treatment\\_of\\_Primary\\_Acute\\_Patellar\\_Dislocation\\_.1.aspx\)](https://journals.lww.com/cjsportsmed/Fulltext/2017/11000/Treatment_of_Primary_Acute_Patellar_Dislocation_.1.aspx) [Abstract \(http://www.ncbi.nlm.nih.gov/pubmed/28107220?tool=bestpractice.bmj.com\)](http://www.ncbi.nlm.nih.gov/pubmed/28107220?tool=bestpractice.bmj.com)

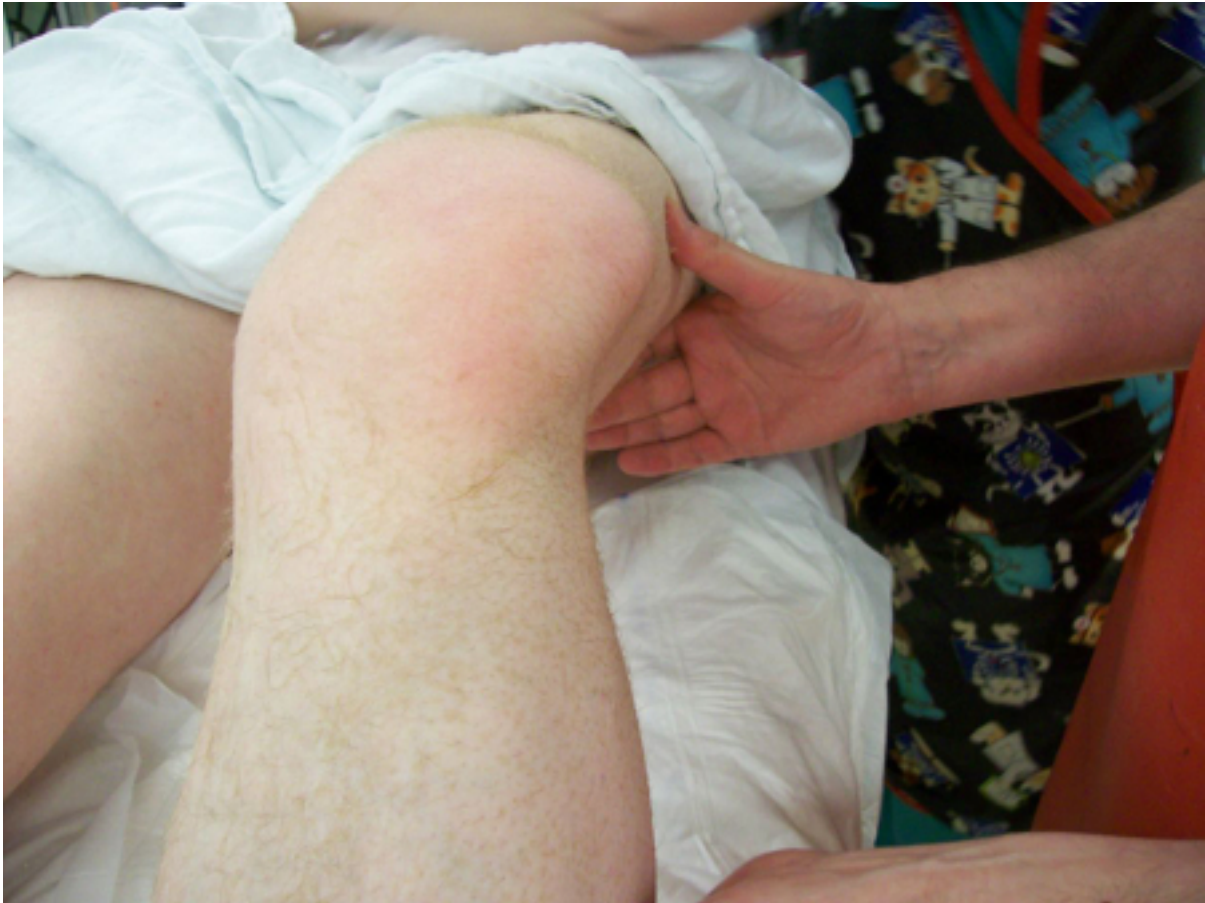## Images



IMAGES

*Figure 1: Dislocated distal phalanx, index finger, left hand*

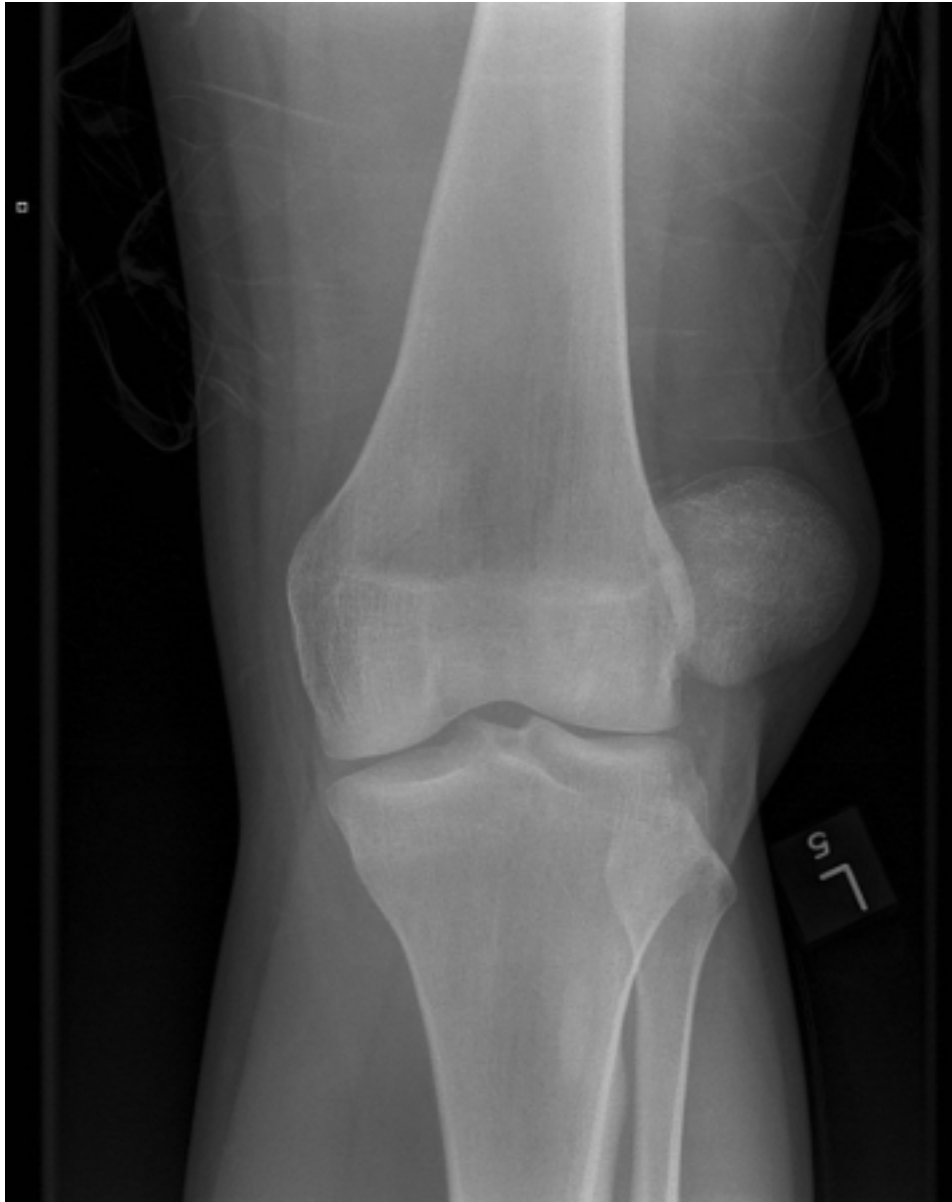*Bobjgalindo, CC BY-SA 4.0, via Wikimedia Commons*



*Figure 2: Patellar dislocation: knee held in partial flexion with a visible mass lateral to the lateral femoral condyle*

*Yerimah G et al. BMJ Case Rep. 2013 May 2;2013:bcr2013009832; used with permission*

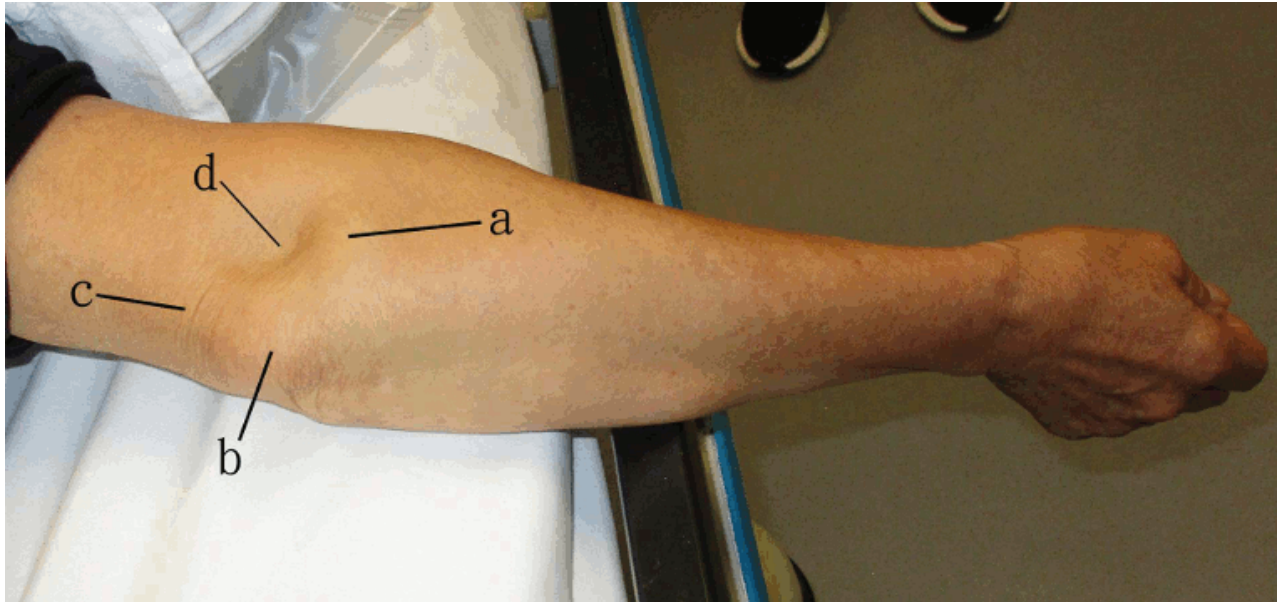




*Figure 3: Left knee radiograph demonstrating lateral patella dislocation*

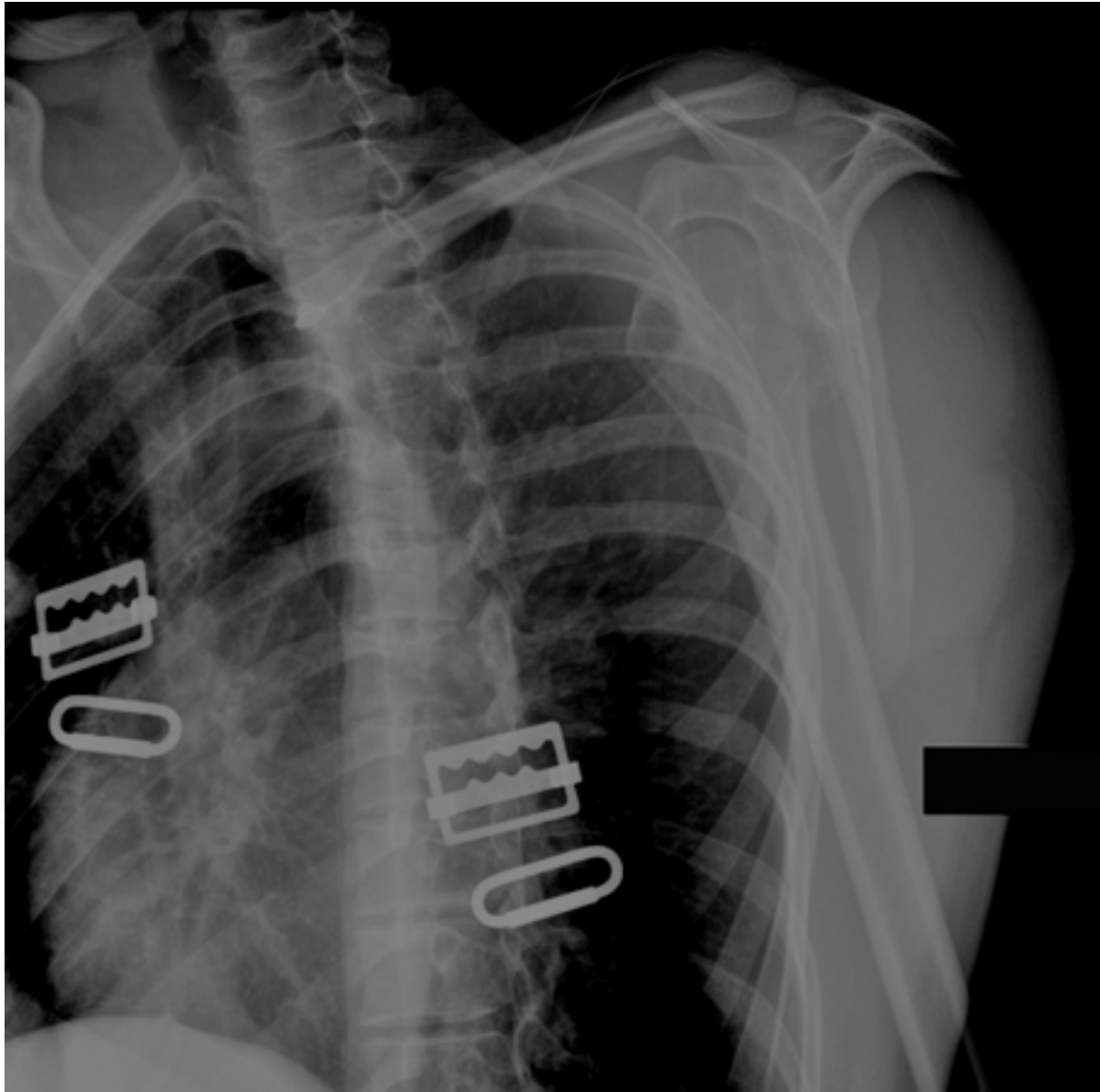
*Yerimah G, et al. BMJ Case Rep. 2013 May 2;2013:bcr2013009832; used with permission*





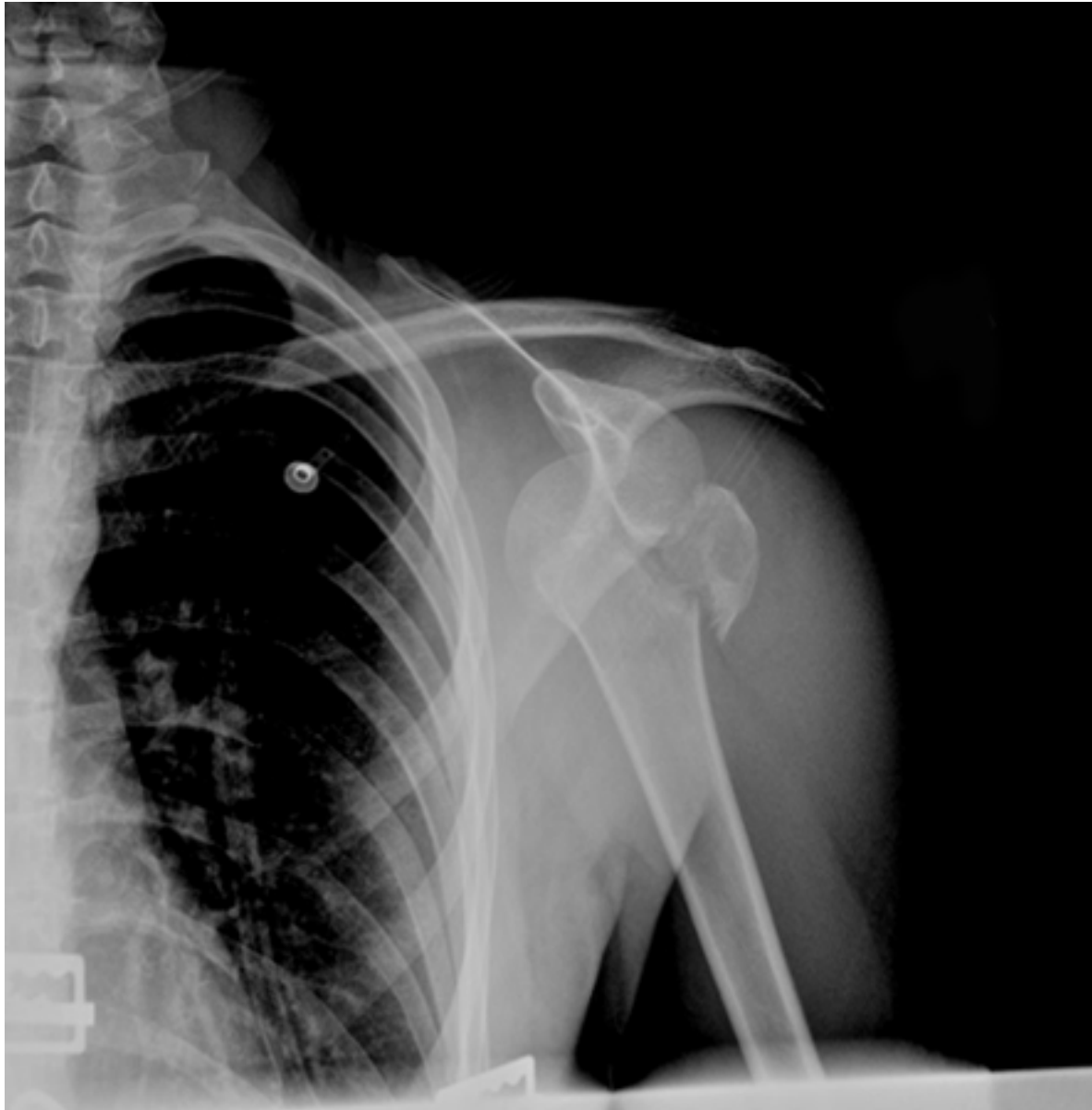*Figure 4: Right elbow dislocation: dislocated radial head (a), olecranon (b), and tensed triceps tendon (c) resulting in a skin depression (d) just proximal to the radial head*

*Lui TH, et al. BMJ. 2020 Oct 8;371:m3494; used with permission*



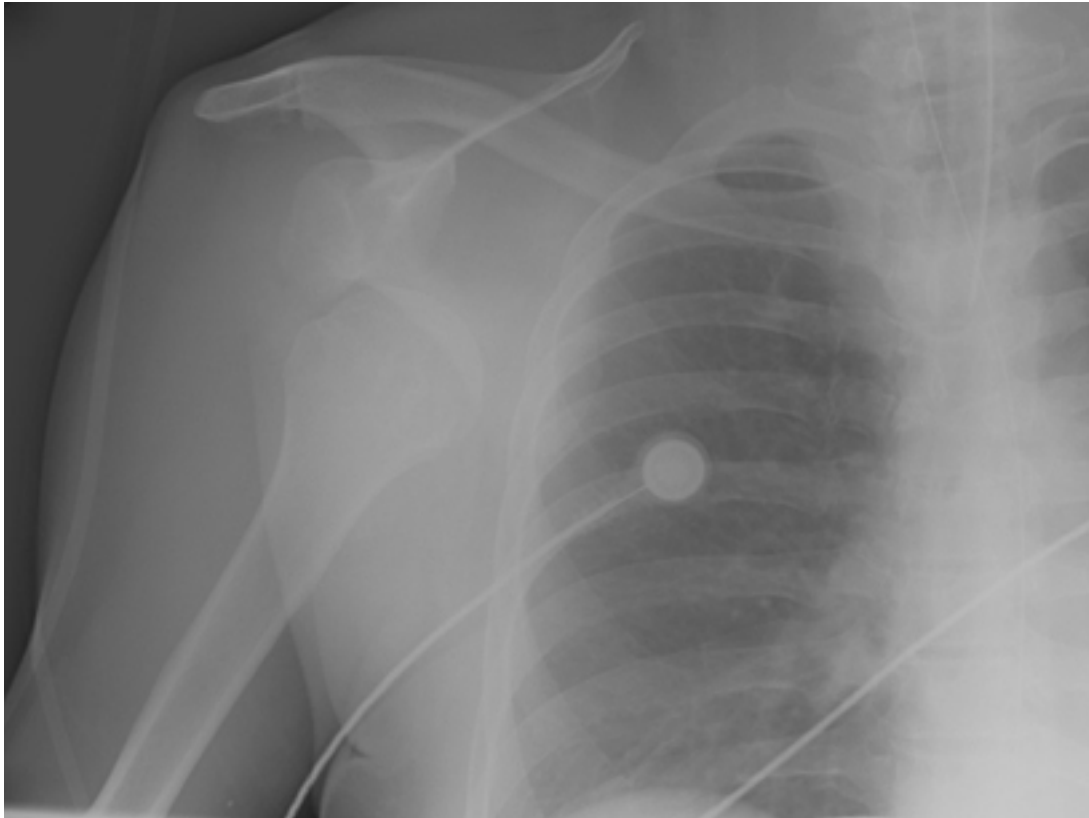
*Figure 5: Scapular Y x-ray view showing an anterior dislocation of the shoulder*

*Personal collection of Dr Paul Novakovich*



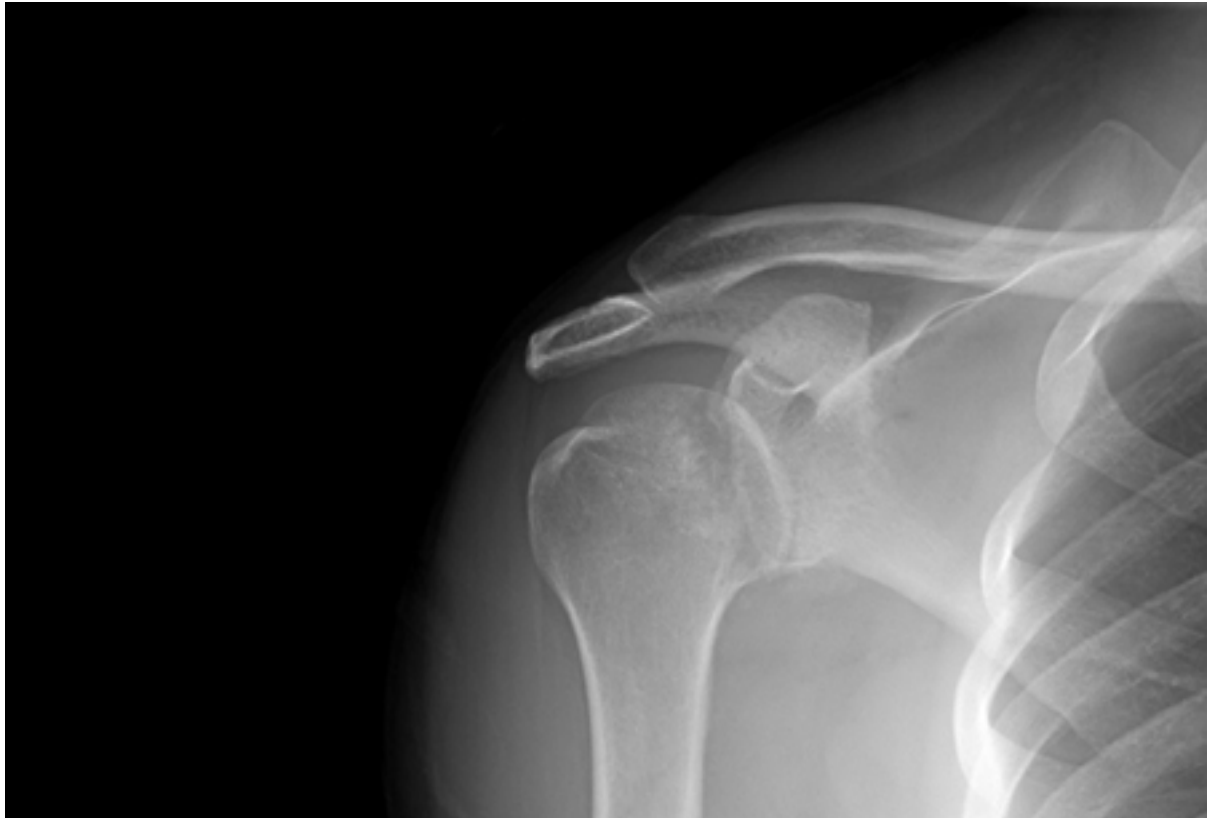*Figure 6: Scapular Y x-ray view showing an anterior fracture dislocation of the shoulder and fracture of the greater tuberosity*

*Personal collection of Dr Paul Novakovich*



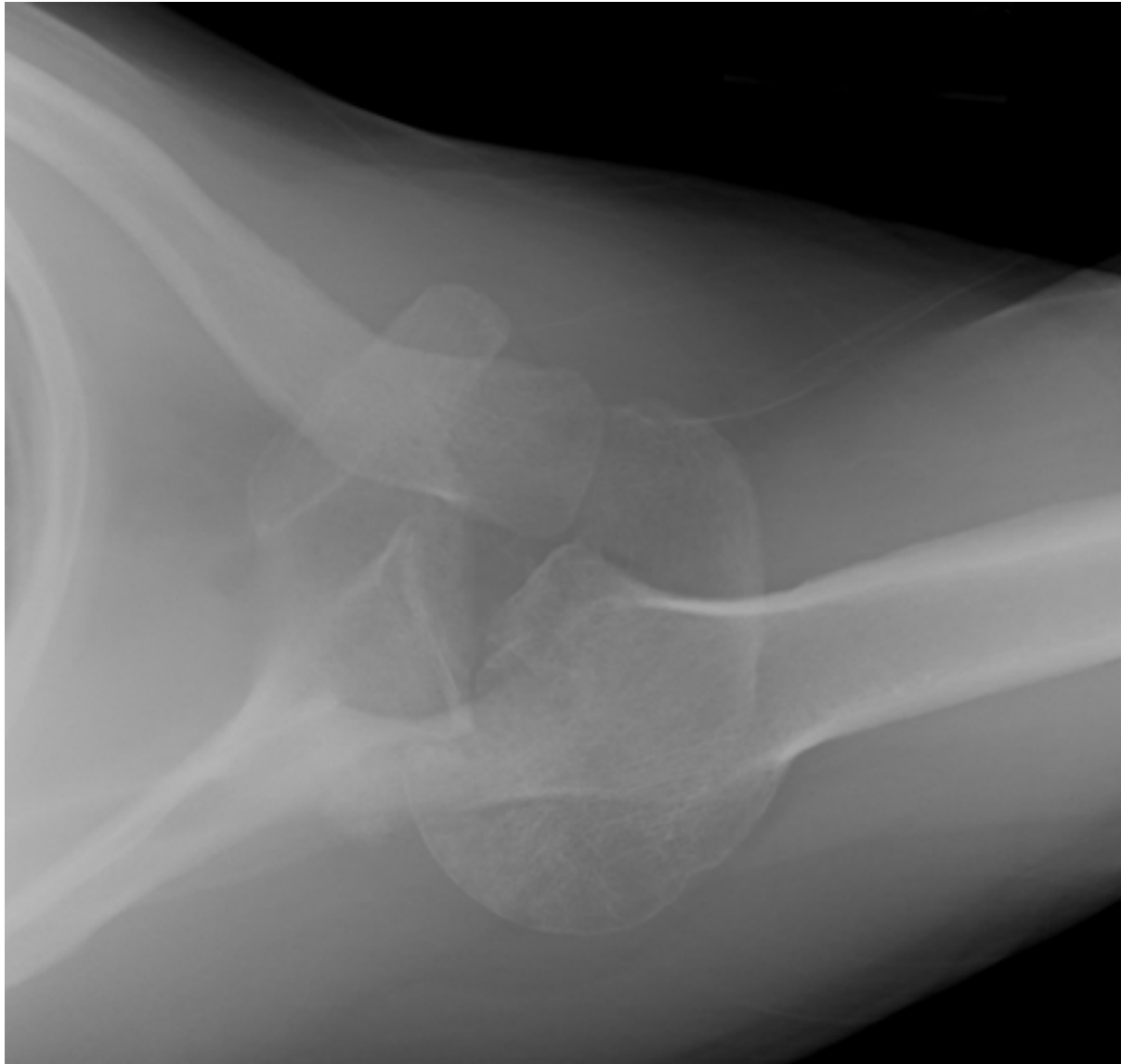
*Figure 7: Anteroposterior x-ray view of a shoulder showing an anteroinferior dislocation*

*Personal collection of Dr Paul Novakovich*



*Figure 8: Anteroposterior x-ray view of a shoulder showing a missed posterior dislocation: the glenohumeral joint appears reduced*

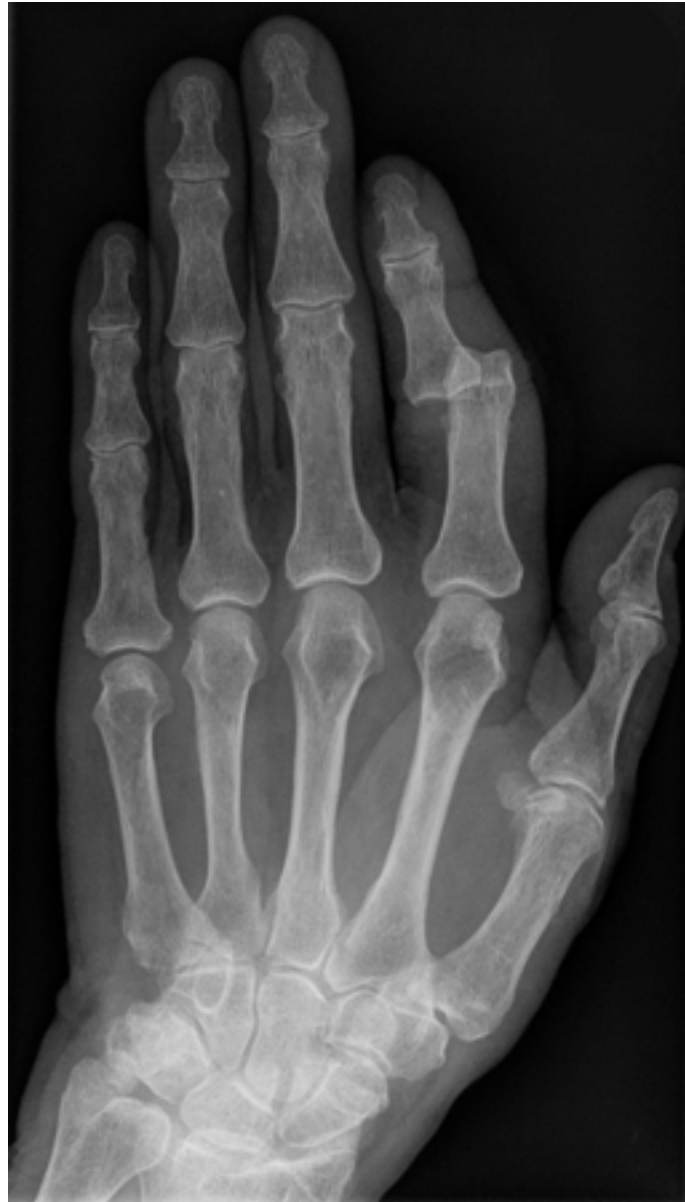*Personal collection of Dr Paul Novakovich*



*Figure 9: Axillary lateral of a shoulder with a missed posterior dislocation: humeral head clearly is not reduced and is locked on the posterior rim of the glenoid*

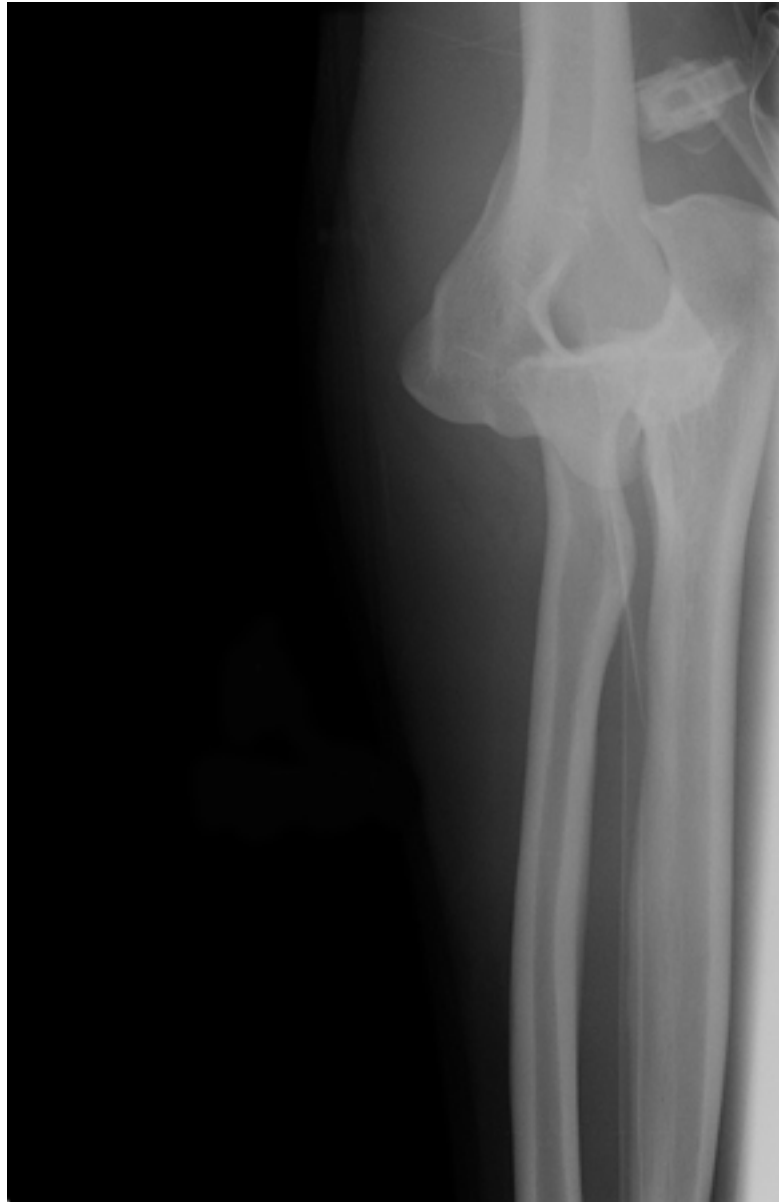*Personal collection of Dr Paul Novakovich*





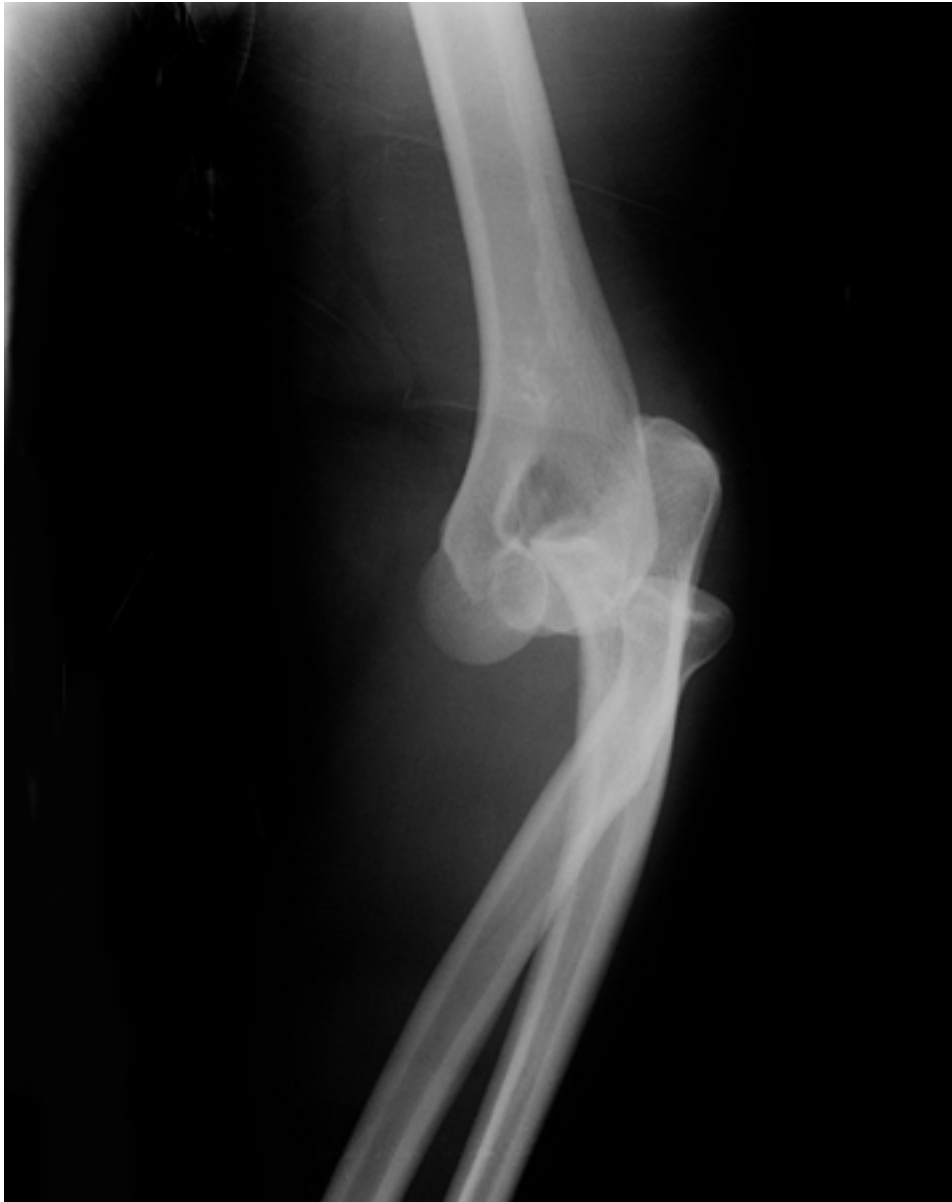*Figure 10: X-ray showing dislocation of the proximal interphalangeal joint, left index finger*

*Hellerhoff, CC BY-SA 3.0 via Wikimedia Commons*



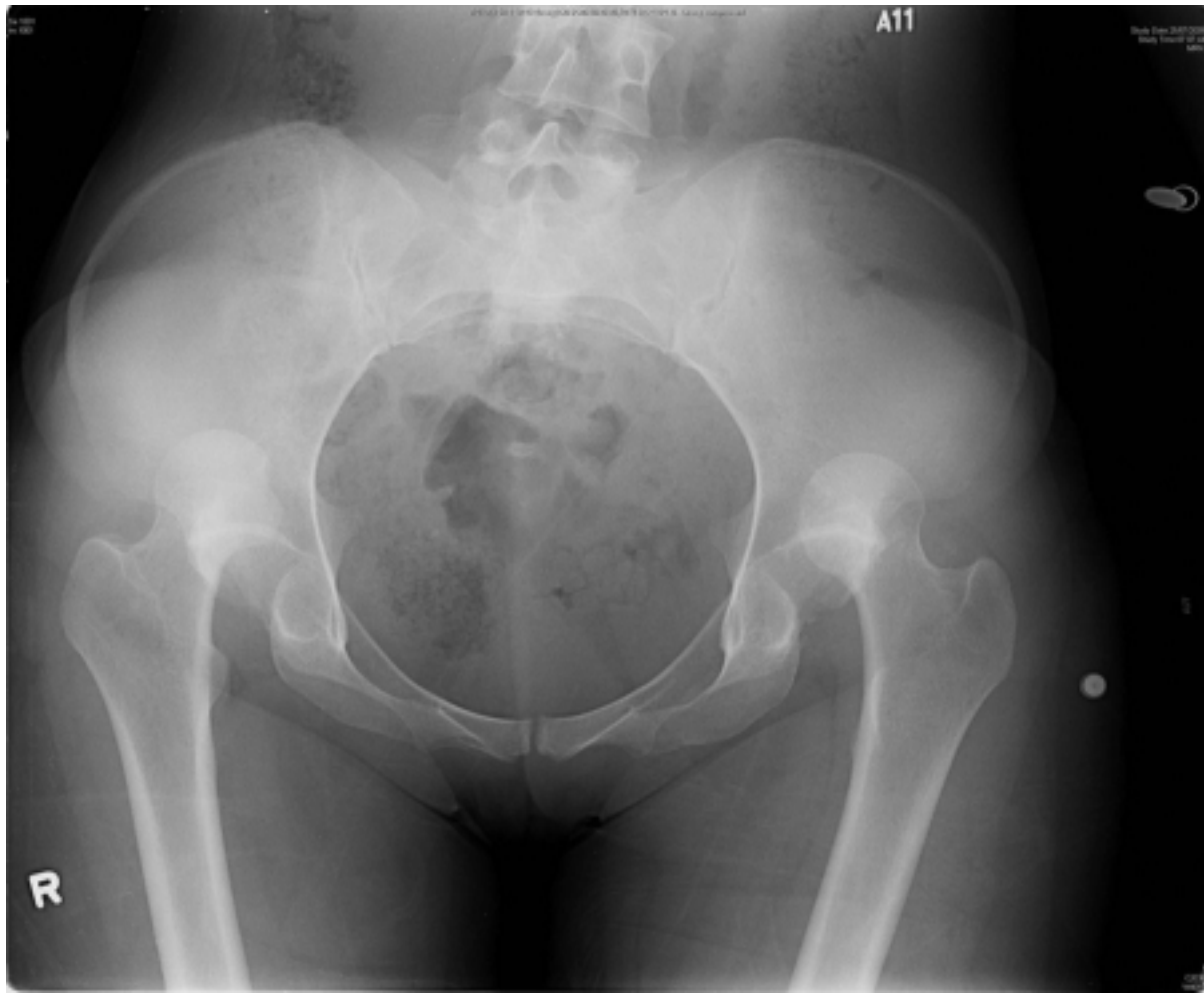
*Figure 11: Anteroposterior x-ray view of an elbow dislocation*

*Personal collection of Dr Paul Novakovich*



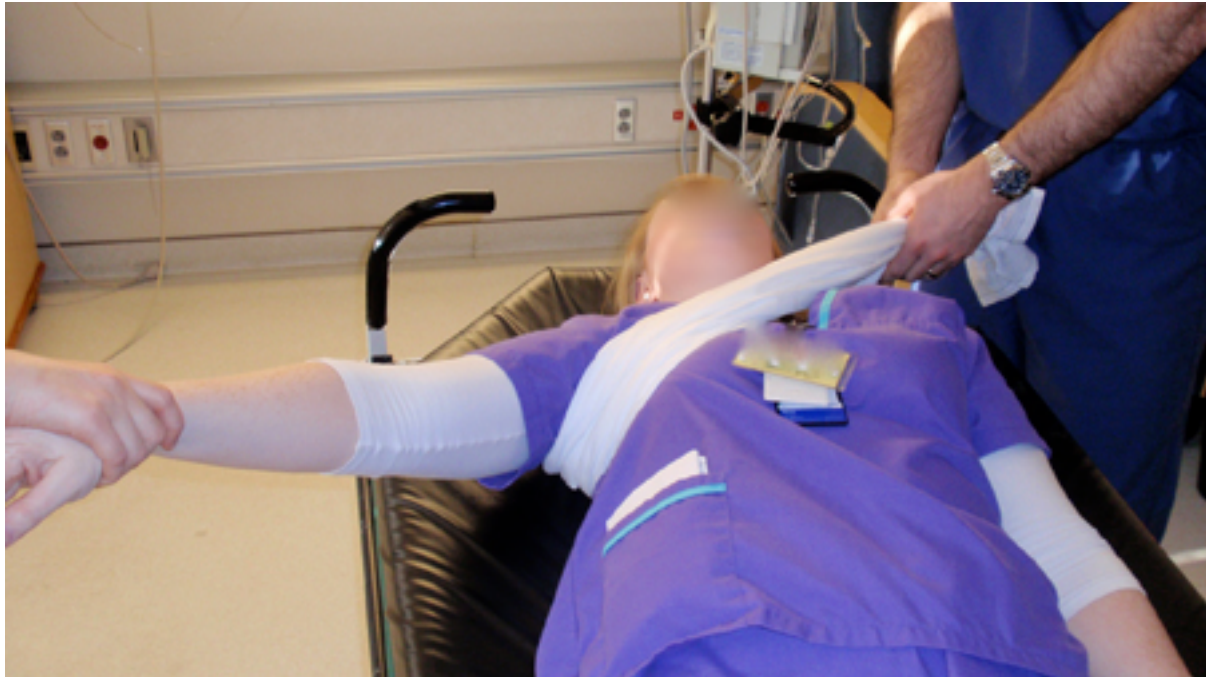*Figure 12: Lateral x-ray view of a posterolateral elbow dislocation*

*Personal collection of Dr Paul Novakovich*



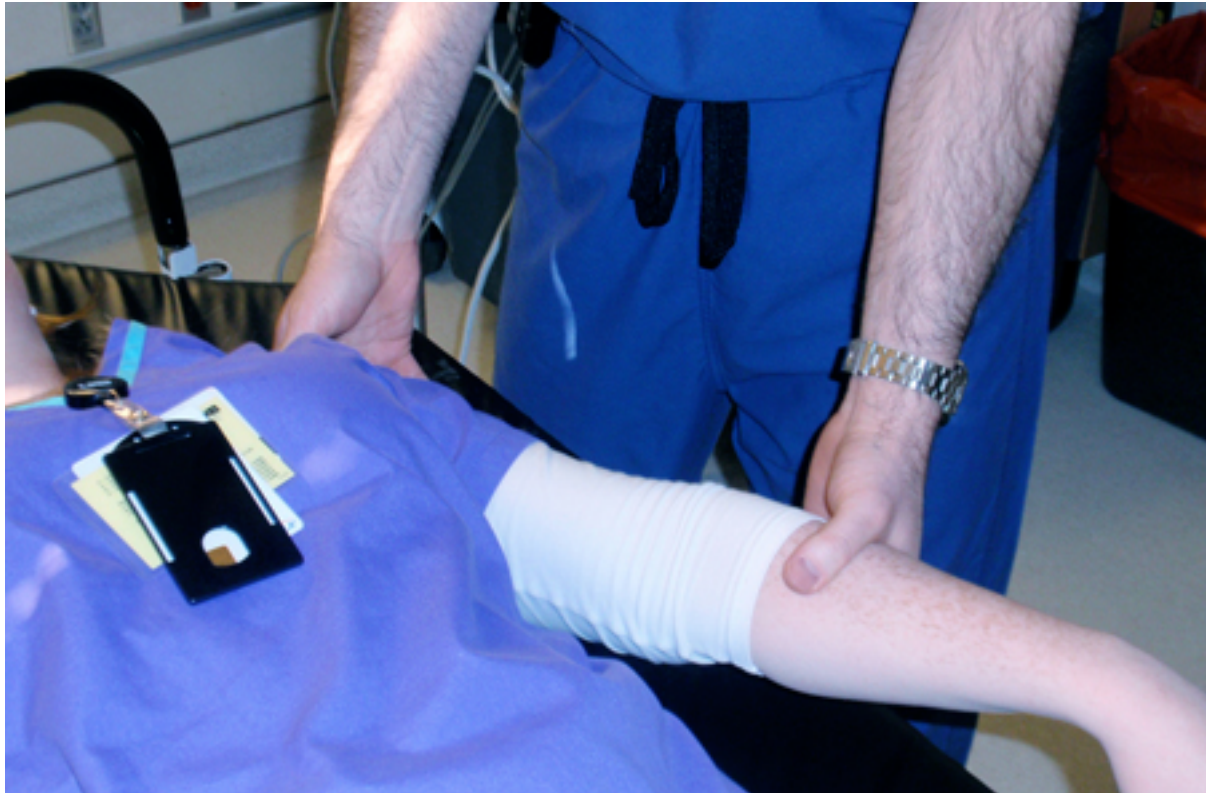*Figure 13: X-ray showing bilateral hip posterior dislocation*

*Fan KY, et al. BMJ Case Rep. 2015 Mar 25;2015:bcr2014204031; used with permission*



*Figure 14: Traction-countertraction method: with patient supine on the bed, a sheet is looped around the axilla with one free end on the chest and the other underneath the back; the 2 ends should be of even length and are used by an assistant to apply countertraction. The practitioner abducts the arm to 90° and flexes the elbow to 90°; the forearm is used to apply slow longitudinal traction to the affected extremity*

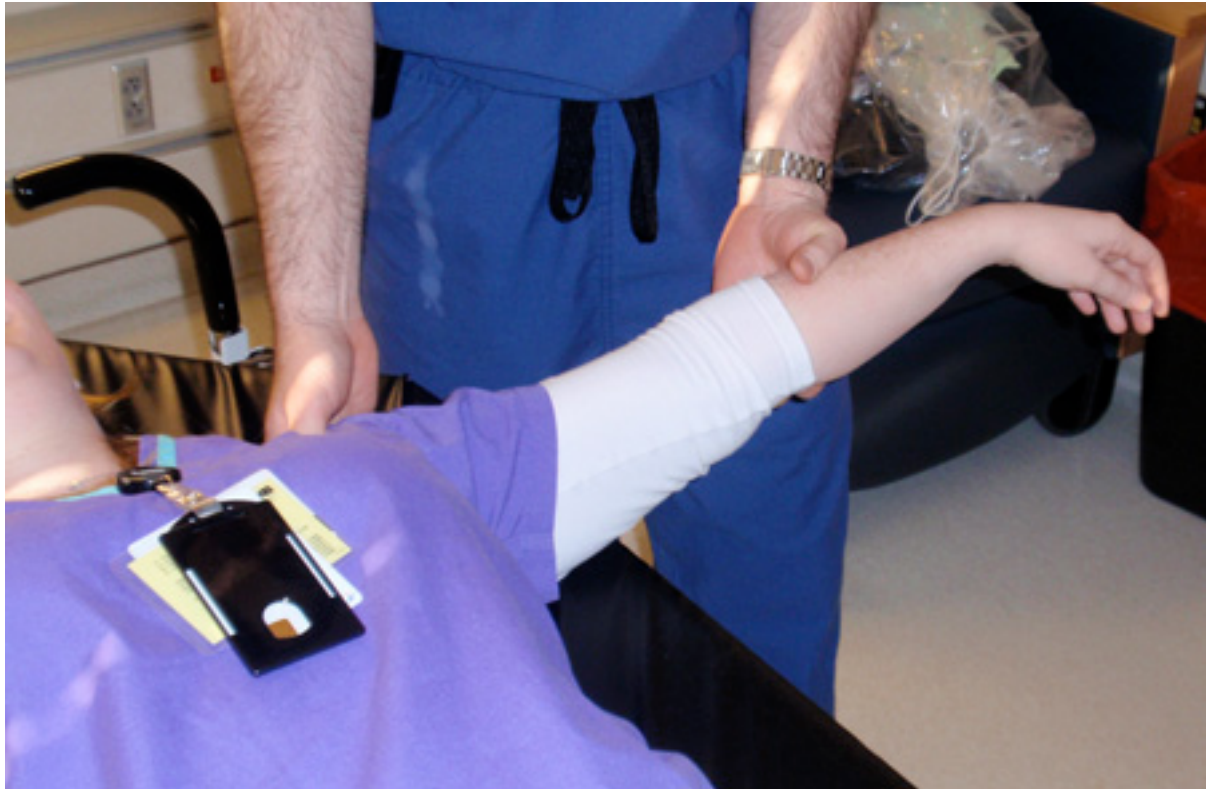
*Personal collection of Dr Paul Novakovich*



*Figure 15: Milch's technique for shoulder reduction, part 1: patient is positioned supine on a bed with the head of the bed elevated about 20° to 30°, then the arm is slowly abducted and externally rotated without application of longitudinal traction (in case of pain or resistance, the practitioner pauses)*

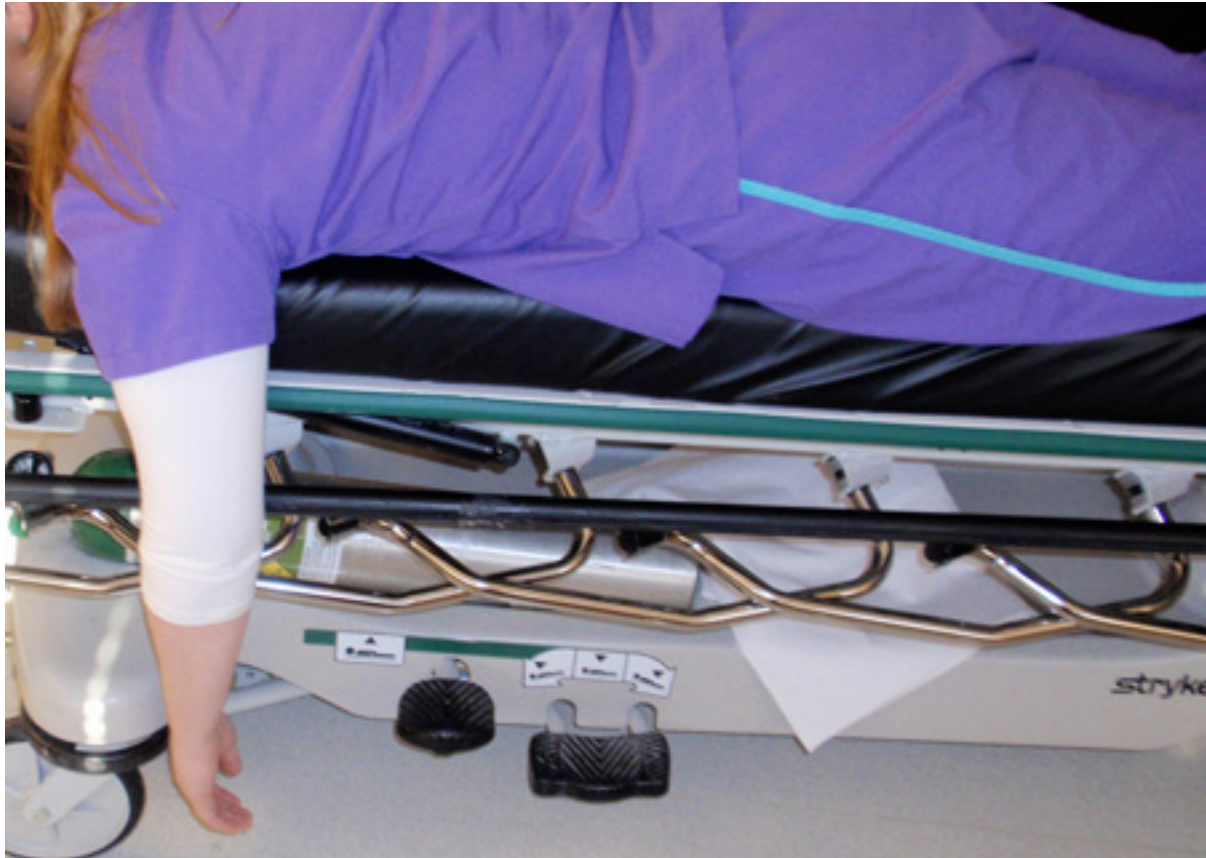*Personal collection of Dr Paul Novakovich*





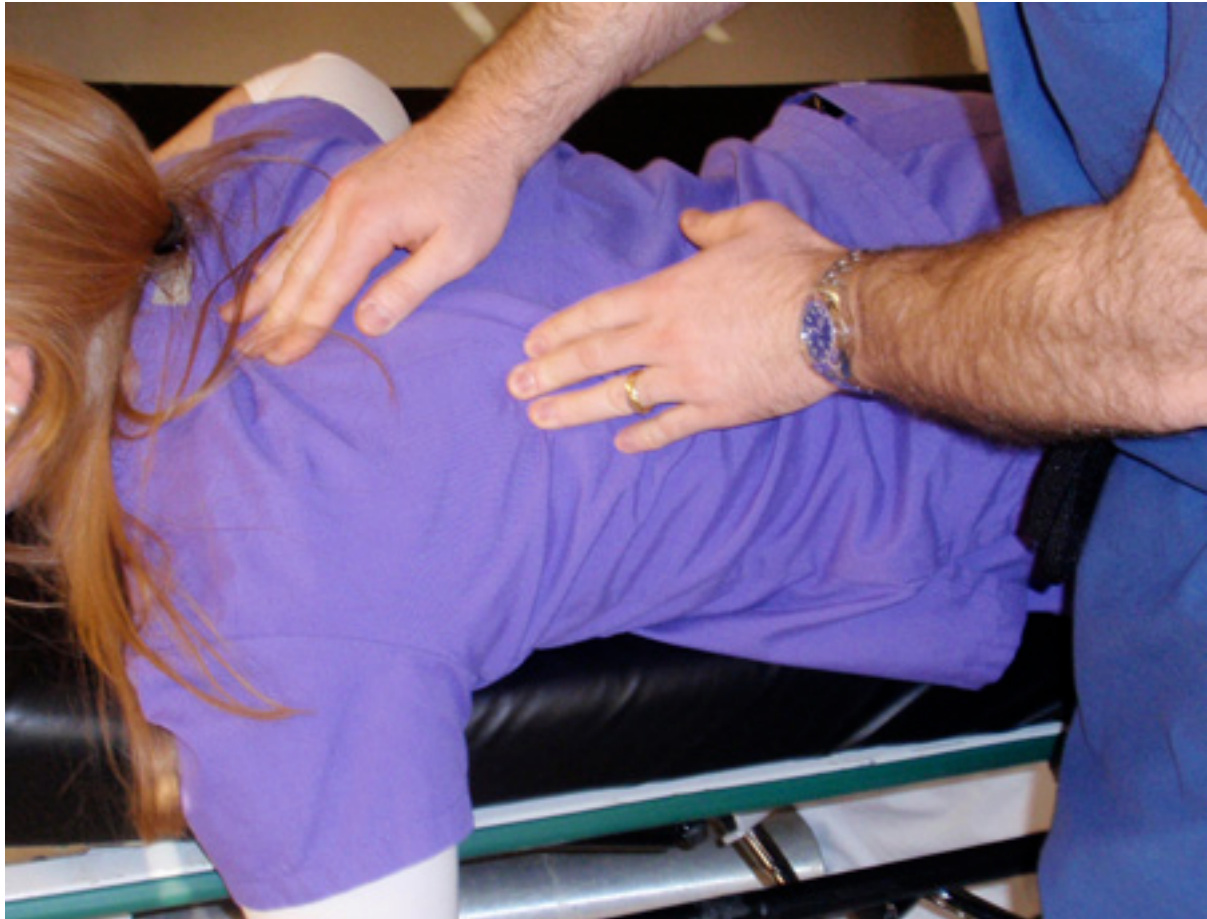*Figure 16: Milch's technique for shoulder reduction, part 2: once the arm has reached a position of 90° abduction and 90° external rotation, the shoulder dislocation should spontaneously reduce; if not, the humeral head can be palpated in the axilla and superolateral pressure can then be applied using the thumb and index finger to help guide the humeral head back into the glenoid*

*Personal collection of Dr Paul Novakovich*



*Figure 17: Stimson's method: patient is positioned prone on the stretcher with the affected shoulder slightly off the stretcher; arm is placed perpendicular to the floor (90° forward flexion) with the stretcher high enough to keep the hand from resting on the floor, then weights of 2.3 to 4.5 kg or 1-L bottles of sterile water are wrapped around the wrist using stockinette and hung high enough to not touch the floor*

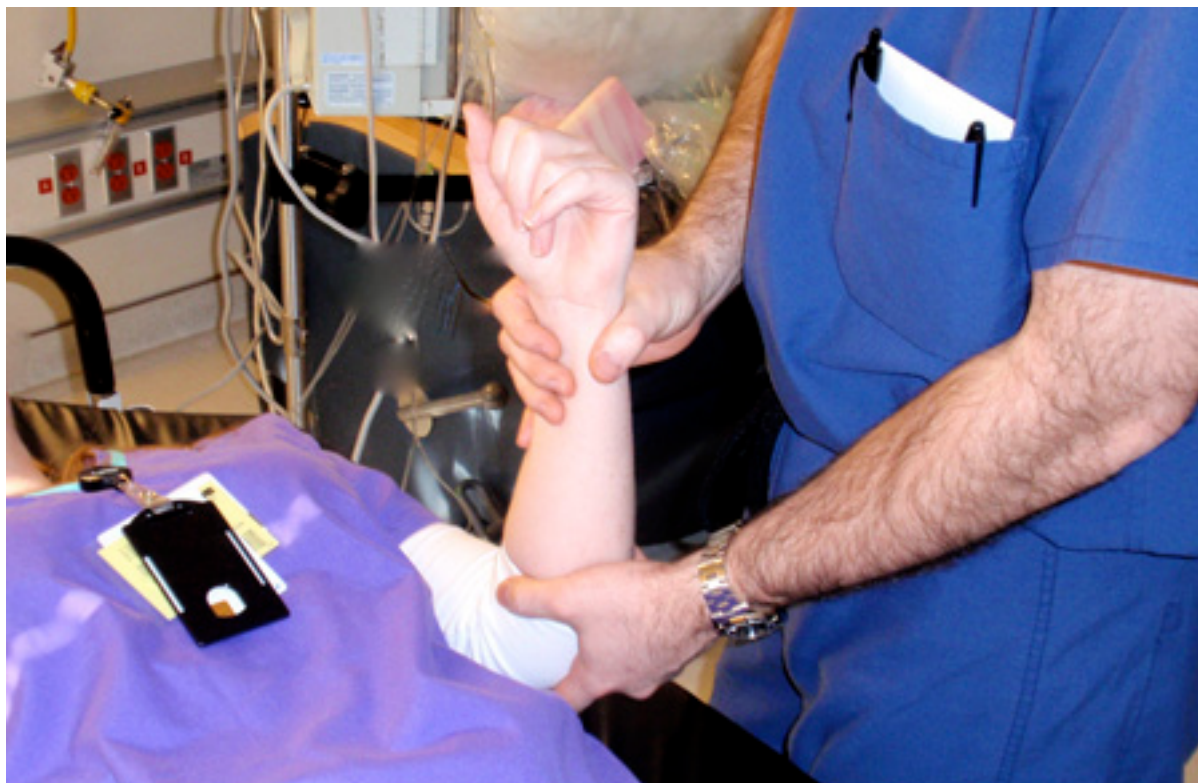*Personal collection of Dr Paul Novakovich*



*Figure 18: Scapular manipulation technique: one hand is placed on the superolateral border of the scapula with the other hand on the inferomedial border of the scapula, and pressure is applied to rotate the superior border laterally and the inferior border medially*

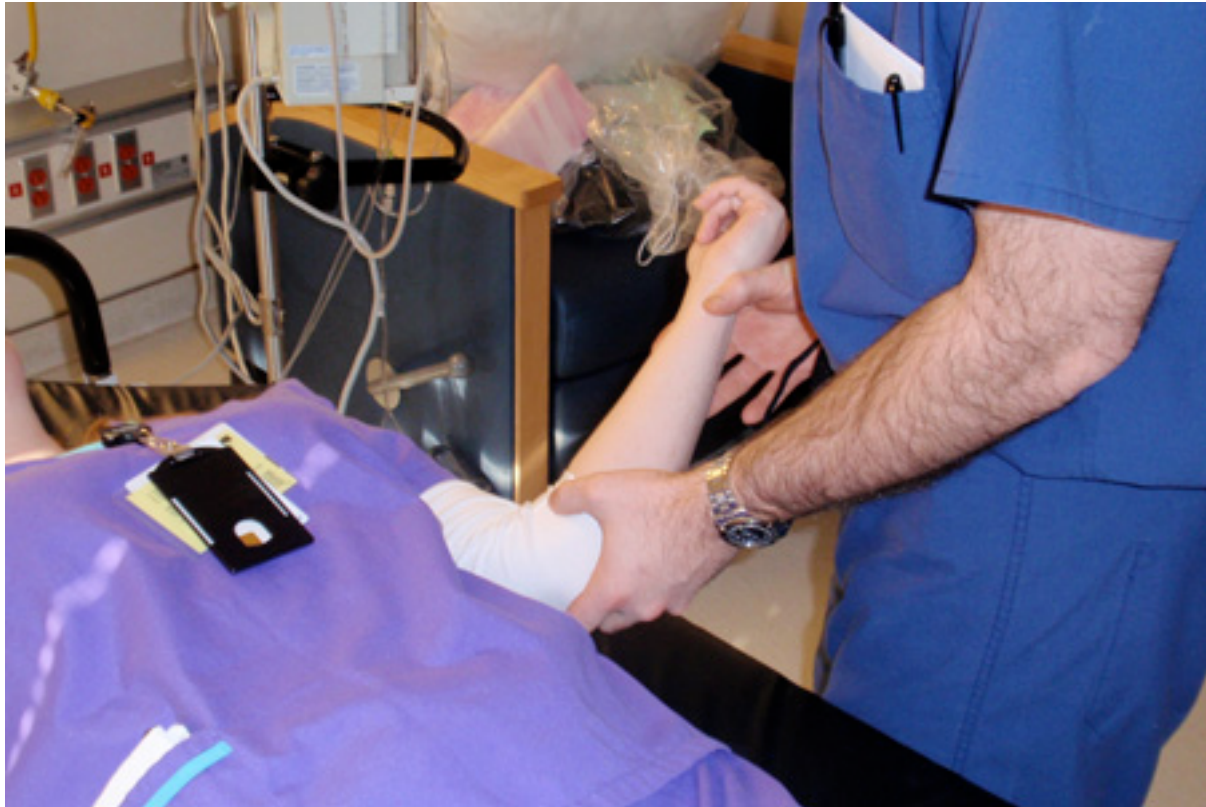*Personal collection of Dr Paul Novakovich*





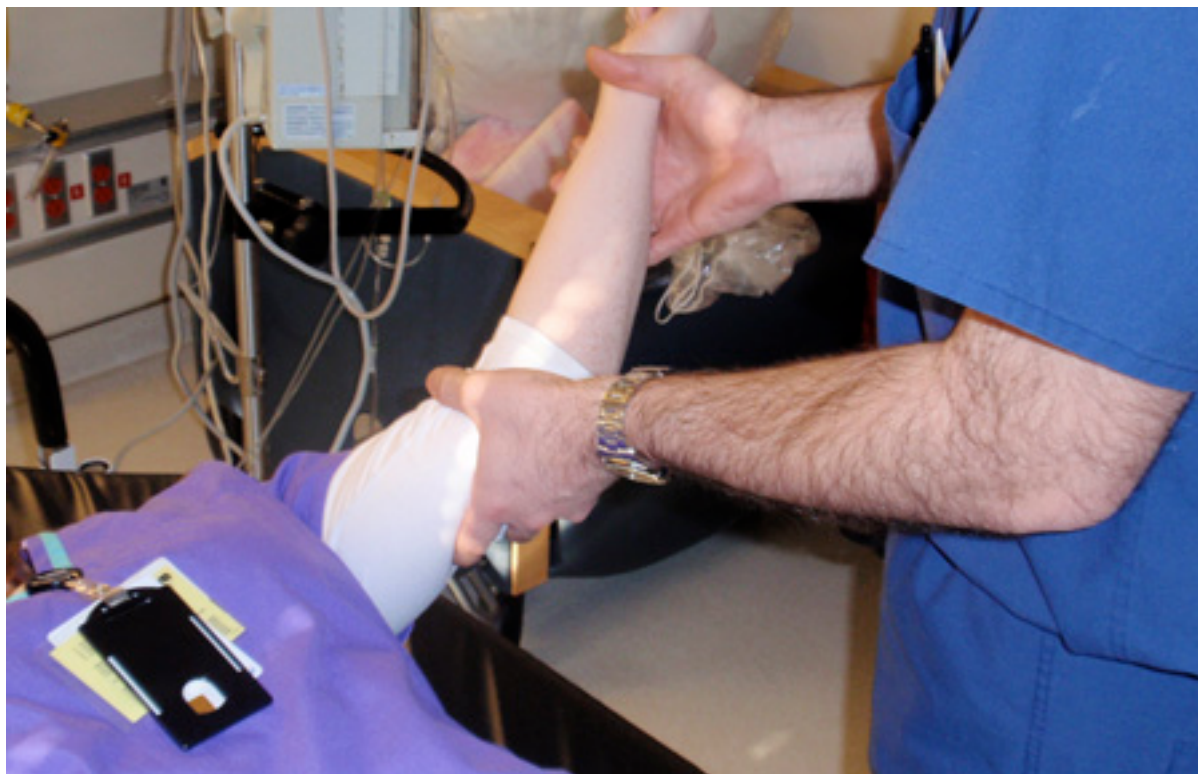*Figure 19: External rotation method for shoulder reduction, part 1: patient is positioned supine, and affected extremity is gently adducted until it is parallel to the long axis of the body; elbow is then flexed to 90°*

*Personal collection of Dr Paul Novakovich*



*Figure 20: External rotation method for shoulder reduction, part 2: by applying gentle pressure to the wrist, the practitioner slowly externally rotates the arm, taking time to allow spasms and contractions to pass; finally, the arm is externally rotated to 90° (i.e., perpendicular to the long axis of the body); shoulder dislocation should reduce after about 5 minutes*

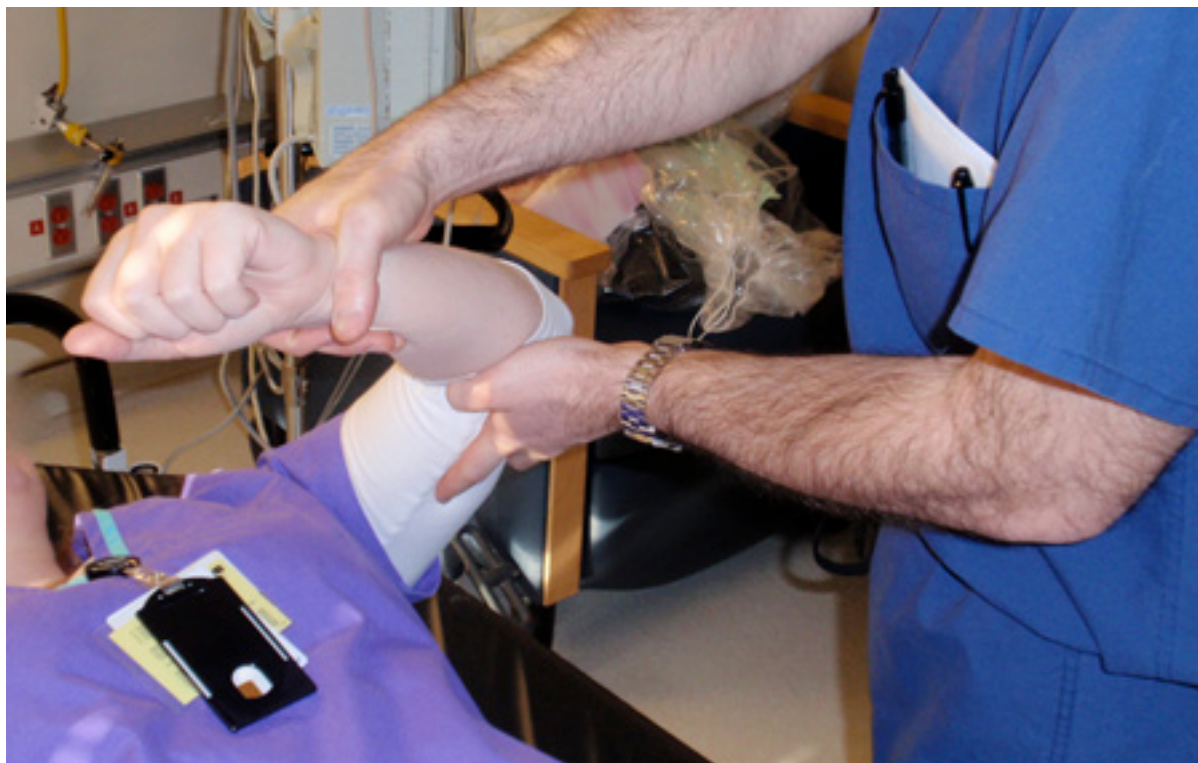*Personal collection of Dr Paul Novakovich*



*Figure 21: Kocher's method of shoulder reduction, part 1: in-line traction of the arm while abducted to 45°; while traction is maintained, arm is externally rotated and elbow is brought across the chest to the mid-line*

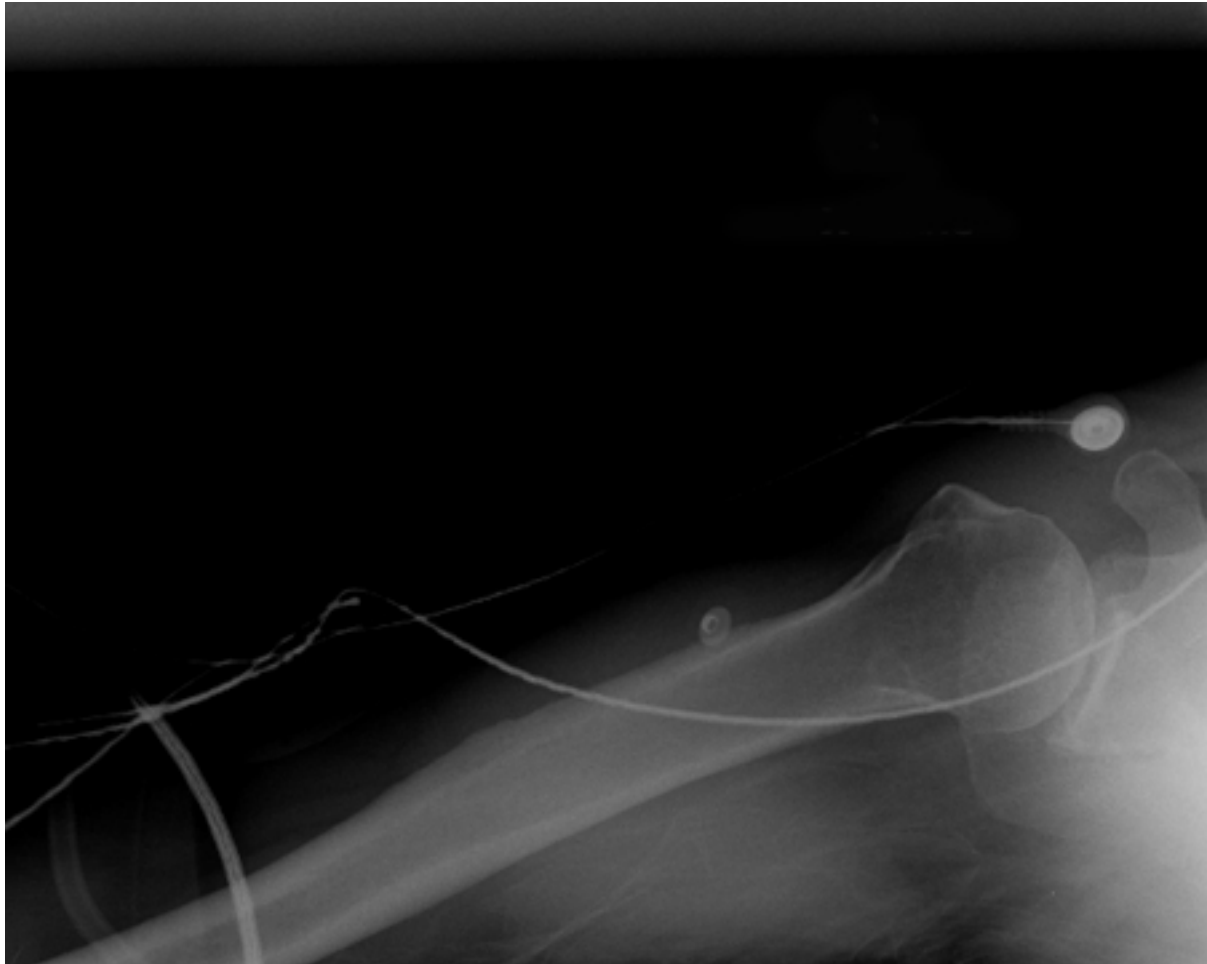*Personal collection of Dr Paul Novakovich*





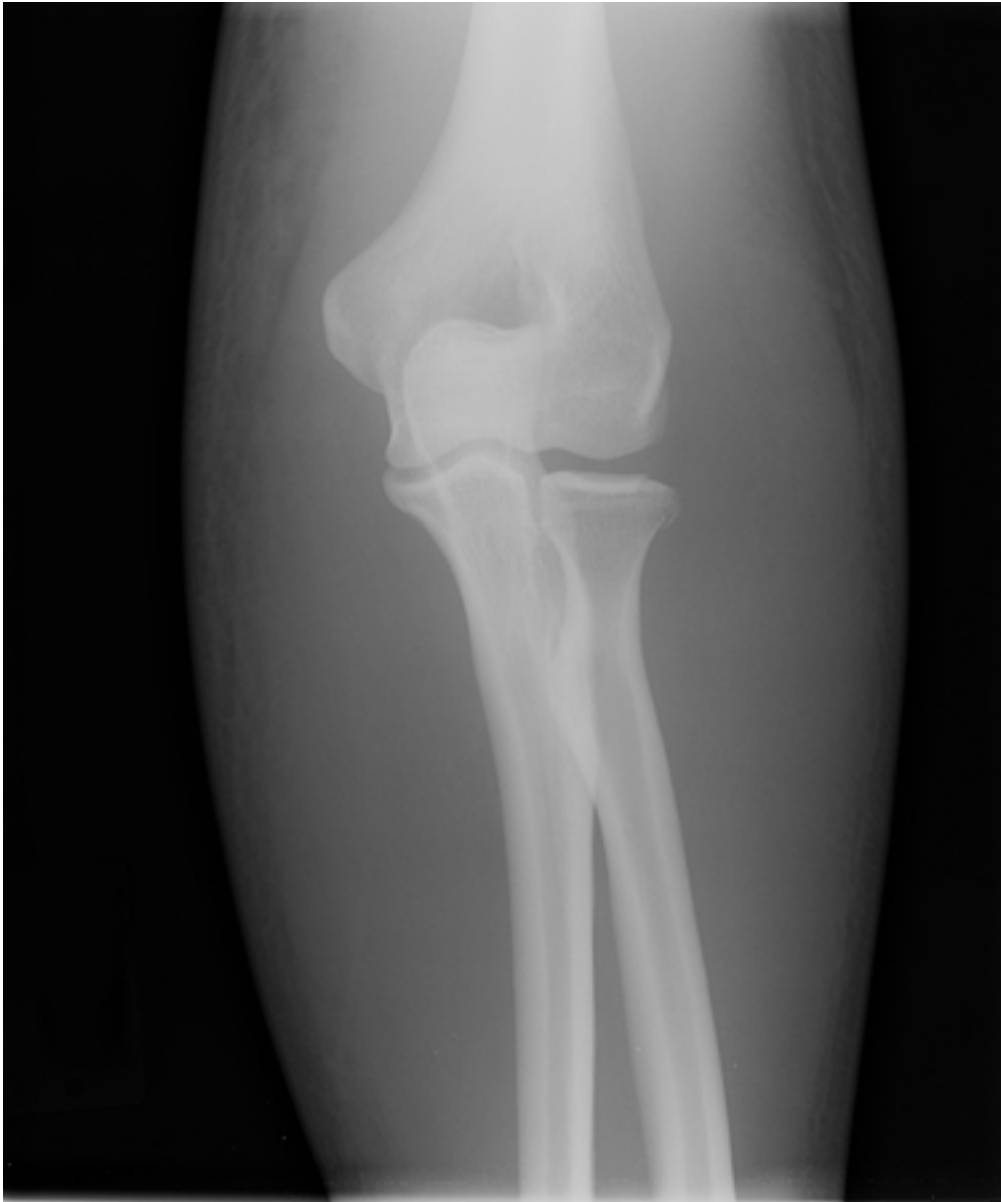*Figure 22: Kocher's method of shoulder reduction, part 2: arm is internally rotated until the patient's hand touches the shoulder*

*Personal collection of Dr Paul Novakovich.*



*Figure 23: Normal axillary x-ray view of a reduced shoulder dislocation, showing congruency of the glenohumeral joint*

*Personal collection of Dr Paul Novakovich*



*Figure 24: Anteroposterior x-ray view of a reduced elbow dislocation*

*Personal collection of Dr Paul Novakovich*

# Disclaimer

BMJ Best Practice is intended for licensed medical professionals. BMJ Publishing Group Ltd (BMJ) does not advocate or endorse the use of any drug or therapy contained within this publication nor does it diagnose patients. As a medical professional you retain full responsibility for the care and treatment of your patients and you should use your own clinical judgement and expertise when using this product.

This content is not intended to cover all possible diagnosis methods, treatments, follow up, drugs and any contraindications or side effects. In addition, since such standards and practices in medicine change as new data become available, you should consult a variety of sources. We strongly recommend that you independently verify specified diagnosis, treatments and follow-up and ensure it is appropriate for your patient within your region. In addition, with respect to prescription medication, you are advised to check the product information sheet accompanying each drug to verify conditions of use and identify any changes in dosage schedule or contraindications, particularly if the drug to be administered is new, infrequently used, or has a narrow therapeutic range. You must always check that drugs referenced are licensed for the specified use and at the specified doses in your region.

Information included in BMJ Best Practice is provided on an “as is” basis without any representations, conditions or warranties that it is accurate and up to date. BMJ and its licensors and licensees assume no responsibility for any aspect of treatment administered to any patients with the aid of this information. To the fullest extent permitted by law, BMJ and its licensors and licensees shall not incur any liability, including without limitation, liability for damages, arising from the content. All conditions, warranties and other terms which might otherwise be implied by the law including, without limitation, the warranties of satisfactory quality, fitness for a particular purpose, use of reasonable care and skill and non-infringement of proprietary rights are excluded.

Where BMJ Best Practice has been translated into a language other than English, BMJ does not warrant the accuracy and reliability of the translations or the content provided by third parties (including but not limited to local regulations, clinical guidelines, terminology, drug names and drug dosages). BMJ is not responsible for any errors and omissions arising from translation and adaptation or otherwise. Where BMJ Best Practice lists drug names, it does so by recommended International Nonproprietary Names (rINNs) only. It is possible that certain drug formularies might refer to the same drugs using different names.

Please note that recommended formulations and doses may differ between drug databases drug names and brands, drug formularies, or locations. A local drug formulary should always be consulted for full prescribing information.

Treatment recommendations in BMJ Best Practice are specific to patient groups. Care is advised when selecting the integrated drug formulary as some treatment recommendations are for adults only, and external links to a paediatric formulary do not necessarily advocate use in children (and vice-versa). Always check that you have selected the correct drug formulary for your patient.

Where your version of BMJ Best Practice does not integrate with a local drug formulary, you should consult a local pharmaceutical database for comprehensive drug information including contraindications, drug interactions, and alternative dosing before prescribing.

## Interpretation of numbers

Regardless of the language in which the content is displayed, numerals are displayed according to the original English-language numerical separator standard. For example 4 digit numbers shall not include a comma nor a decimal point; numbers of 5 or more digits shall include commas; and numbers stated to be less than 1 shall be depicted using decimal points. See Figure 1 below for an explanatory table.

BMJ accepts no responsibility for misinterpretation of numbers which comply with this stated numerical separator standard.

This approach is in line with the guidance of the [International Bureau of Weights and Measures Service](#).

## Figure 1 – BMJ Best Practice Numeral Style

5-digit numerals: 10,000

4-digit numerals: 1000

numerals < 1: 0.25

Our full website and application terms and conditions can be found here: [Website Terms and Conditions](#).

### Contact us

+ 44 (0) 207 111 1105

[support@bmj.com](mailto:support@bmj.com)

BMJ

BMA House

Tavistock Square

London

WC1H 9JR

UK

# BMJ Best Practice

## Contributors:

---

### // Authors:

---

**Thomas M. DeBerardino, MD**

The San Antonio Orthopaedic Group  
San Antonio, TX

DISCLOSURES: TMD is a paid consultant and receives royalties from Arthrex, Inc. He serves on the Data Safety Monitoring Board for Aesculap and is a paid consultant for Arthrex, Inc., Emovi, ConMed, Icarus, JRF, and LinX Robotics. He has patents with Arthrex, Inc. TMD declares that none of these relationships relate to this topic.

### // Acknowledgements:

Dr Thomas M. DeBerardino would like to gratefully acknowledge Dr Paul Novakovich and Dr Brent Ponce, previous contributors to this topic.

DISCLOSURES: PN and BP declare that they have no competing interests.

### // Peer Reviewers:

---

**Daniel J. Solomon, MD**

Co-director of Orthopedic Sports and Shoulder Service  
Department of Orthopedic Surgery, Naval Medical Center San Diego, San Diego, CA  
DISCLOSURES: DJS declares that he has no competing interests.

---

**Matthew T. Provencher, MD**

Assistant Director  
Orthopaedic Shoulder and Sports Surgery, Naval Medical Center San Diego, San Diego, CA  
DISCLOSURES: MTP declares that he has no competing interests.

---

**Peter Cundy, MBBS, FRACS**

Head of Orthopaedic Surgery  
Women's & Children's Hospital, Adelaide, South Australia, Australia  
DISCLOSURES: PC declares that he has no competing interests.